

SUBCUTANEOUS MUCORMYCOSIS CAUSED BY RHIZOPUS ORYZAE PROBABLE NOSOCOMIAL ACQUIRED INFECTION (*)

Flávio de QUEIROZ TELLES FILHO (1,4), Afonso COELHO (2), Edward PORTO (3), Rosângela Ferreira LAMEIRA (4), Marli Maria FREITAS (5), Janio BARBOZA (5) and Jorge Luiz Zanette RAMOS (5)

SUMMARY

The Authors present a case of subcutaneous mucormycosis occurring in a patient with clinical and biochemical evidence of diabetic ketoacidosis. The clinical, mycological and histopathological features are described, emphasizing the relevance of a rapid diagnosis in order to establish early treatment. The clinical forms of mucormycosis and the main associated conditions are briefly reviewed as well as the most probable conditions which may lead to the enhanced susceptibility to infection in the diabetic patient in ketoacidosis. The recovery of *Rhizopus oryzae* from the air of the room of the patient suggests a nosocomial infection acquired through contamination of venous puncture site by air borne spores.

INTRODUCTION

The human infections caused by fungi of the class *Zygomycetes* are cosmopolitan and have been reported in normal and immunocompromised hosts. The disease has been generically called Zygomycosis (Phycomycosis). GREER¹² suggested the terms Mucormycosis and Entomophthoromycosis to name the infections restrictedly caused by *Zygomycetes* of the orders *Mucorales* and *Entomophthorales*, since they are different diseases¹². The human mucormycosis is world-wide in distribution often as an opportunistic infection and rarely affecting immunologically normal individuals¹⁸. Frequently it is a disease of acute evolution, characterized by invasion and growth of *Mucorales* in the vascular wall and lumen, with subsequent mycotic thromboembolism, ischemia, tissue necrosis and eventually death depending on the affected site. The rhinocerebral variant is the most acute and fulminant of the known mycosis^{21,22}. The entomophthoromycosis, also known

as subcutaneous zygomycosis or basidiobolomycosis is restricted to tropical and subtropical regions, being reported the cases mainly from Africa and Asia, and occasionally from South America^{5,13,18}. Generally it has a chronic evolution characterized by the development of eosinophilic granuloma in the subcutaneous fat, rhino-orbital cavities and other areas of the organism, with swelling of the affected regions. The patients are apparently healthy^{6,18,19}.

The agents of mucormycosis are ubiquitous in nature, where they live on decaying organic material as saprophytes. They may be isolated from the air, soil, fruits, clinical materials and human orifices⁴. They reproduce by sexual and asexual ways and in the anamorphic (asexual) state form a great amount of spores inside sacular structures called sporangia. The principal way of dissemination is the air. The genera of the order *Mucorales* related as the

(*) Hospital de Clínicas da Faculdade de Medicina da Universidade Federal do Paraná, Curitiba, PR, Brasil

(1) Professor Auxiliar da Disciplina de Doenças Infecciosas e Parasitárias da U.F.PR

(2) Professor Titular de Anatomia Patológica da U.F.PR

(3) Micologista do Instituto de Medicina Tropical de São Paulo

(4) Setor de Micologia Médica do Hospital de Clínicas da U.F.PR

(5) Médicos Residentes do Departamento de Clínica Médica da U.F.PR

cause of mucormycosis are the following: *Rhizopus*, *Mucor*, *Absidia*, *Rhizomucor*, *Mortierella*, *Cunninghamella*, *Saksenaea* and *Syncephalastrum*.

The first case of mucormycosis, according to RIPPON²², was reported by PALTAUF in 1885. There are approximately 400 cases of different clinical manifestations actually described. During the last two decades there was a significant increase in number mainly related to diabetic ketoacidosis and immunodepression^{14,17,22}.

The primary or exogenous cutaneous and subcutaneous mucormycosis is a rare occurrence and the way of infection is related to the rupture of the skin barrier with subsequent development of necrotic lesions in the skin or subcutaneous fat^{15,24}. Recently microepidemics of cutaneous mucormycosis were reported in hospitals and were related to the use of elasticized adhesive tape dressings on open wounds in immunocompromised patients^{11,23} as well in patients with orthopedic problems and without apparent immunological change⁹. The reports with histological study and mycological identification, especially in hospital acquired cases are rare.

REPORT OF THE CASE

A.S.F., 61 years old, white, male, diabetic, was admitted to the emergency room of "Hospital de Clínicas da Universidade Federal do Paraná", in keto-acidotic coma. He was decompensated because of irregular use of insulin, irregular diet and two abscesses in the left thigh. He was comatous, dehydrated, with the following laboratory findings: Red blood cell count, 4,040,000/mm³; total white blood cell count, 10,700/mm³ and a differential count as follows: polymorphonuclear leukocytes, 77%; lymphocytes, 20%; and monocytes, 3%. Blood urea nitrogen 34 mg/100ml; serum creatinin, 3.8 mg/100 ml; blood glucose 694 mg/100 ml. Serum electrolyte estimation showed the following levels: sodium, 136 mEq/l; potassium, 4.6 mEq/l. Arterial gases: pCO₂, 8.2 mmH₂O; pO₂, 123 mmH₂O; buffer base, 16; base excess -32; pH 6.84; HCO₃, 1.4 μEq/l.

He was routinely treated and the abscesses were drained. On the second day of admission

he was conscious and the ketoacidosis was partially corrected. On the fourth day there was a hemorrhagic and vesicular lesion on the left forearm in the area where a venous puncture for fluid and electrolytes administration was done. This area was involved with elasticized tape dressing. At the same time the patient developed ketoacidosis again. In 24 hours the forearm lesion progressed to an extensive fagedenic ulceration with irregular margins, showing the muscle tendons and measuring 12 x 8 cm (Fig. 1A). A fragment to the margin was removed and sent to bacteriological, mycological and histopathological examination.

Bacteriology — Bacterial cultures of the ulceration showed *Staphylococcus aureus* growth.

Mycology — The tissue fragment was sectioned in aseptic conditions and small portions were mounted in 40% potassium hydroxide on a microscope slide and covered with a cover slip. Fragments were also placed in Petri dishes with Sabouraud's agar/cloramphenicol and incubated at 37°C and room temperature (25°C).

Direct microscopic examination: after 15 minutes of tissue digestion a mass of intertwined hyphae were seen among the cell clusters in decomposition. After 4 hours, with better clarification, there was a great amount of thick, hyaline tortuous, coenocytic right-angled hyphae, with no perfect parallel walls suggesting tissue invasion by *Mucorales*.

Culture — After 24 hours in all incubated plates the tissue fragment and the area of agar 3 cm around were covered by clear web like mycelium with radiated margins. At the microscope (400x) it seemed steril with an intense cytoplasmatic flux inside the coenocytic hyphae. After 4 days the plates were totally covered by an elevated cotton-like, brownish-gray mycelium with small dark points. The slide culture showed sporangia with no or slightly branching, emerging in opposition to poor developed rhizoids, which is characteristic of *Rhizopus* sp.

Incubated samples in different temperatures showed a positive growth at 45°C. Further subcultures were sent to Prof. Edward Porto, "Instituto de Medicina Tropical de São Paulo", who identified the *Mucorales* as *Rhizopus arrhi-*

zus. This fungus is now considered as synonym of *R. oryzae* WENT & PRINSEN GERLIGS, 1895.

Histopathology — There was extensive necrosis of skin and subcutaneous fat with acute

inflammation. Scattered among the polymorphonuclear neutrophils were numerous broad non septated right angled branching hyphae easily recognized in the hematoxylin eosin stained slides (Fig. 1, C, D). Special staining by

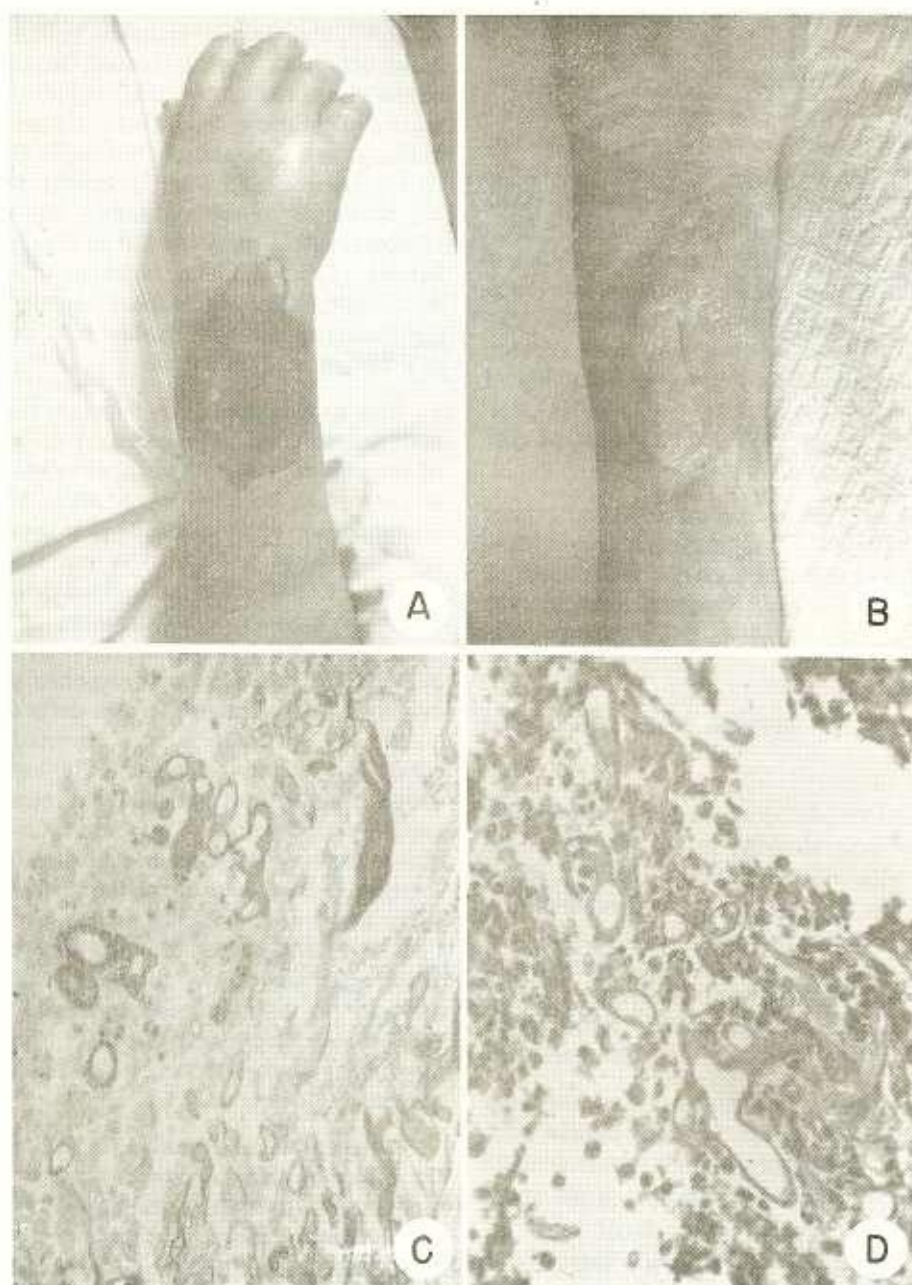


Fig. 1 — A-B — Zygomycosis of forearm before and during the treatment. C-D — Broad non septated branching hyphae with tissue necrosis. GROCCOTT and H.E., $\times 400$

Grocott methenamine silver nitrate technique emphasized the contrast between the fungus and the tissue. There was no vascular invasion in sections.

Evolution — After the results from the direct mycological examination, the patient received amphotericin B by venous route and local therapeutics with 1.5% amphotericin B cream. After completing 75 mg of systemic administration the diabetes was compensated, showing blood glucose of 173 mg/100 ml and normal arterial gases. The tissue specimens still showed the presence of hyphae on histological and mycological examinations. After completing 725 mg of amphotericin B the levels of blood urea and serum creatinin were elevated and the drug was interrupted. The diabetes again showed ketoacidosis. After correcting the ketoacidosis and the reintroduction of amphotericin B, a progressive change in ulceration was noticed with development of granulation tissue and no secretion.

Two months after admission, after a total dose of 1,775 mg of amphotericin B and daily 40 units of NPH insulin, diabetes was controlled and the cutaneous lesion reduced to 5 x 3 cm with granulation tissue, and the patient was clinically well.

Attempts of fungi isolation from the hospital environment

Ten rolls of elastic opened or not adhesive bands from several areas in the hospital were sectioned with sterile scissors in small strips and placed on the surface of Sabouraud dextrose agar. To ensure contact with the agar, the strips were moistened with a small amount of 5% sterile glucose solution. After one week incubation, several contaminant fungi were grown, but none was identified as *Mucorales*.

Eight plates of Sabouraud dextrose agar were settled in the room where the patient stayed, during a period of 6 hours, coincidentally with the most active work hours. After seven days incubation several contaminant fungi have grown and in two plates of the same room, together with colonies of *Penicillium sp.* and *Aspergillus sp.*; there was the development of *Rhizopus oryzae*.

DISCUSSION

According to reports on mucormycosis², the primary invasion of the skin and subcutaneous tissue by *Mucorales* occurs in less than 10% of the cases. Due to the possibility of internal dissemination from primary skin lesions^{25,27}, the disease must be promptly recognized accordingly, and treated. In the case of ketoacidosis associated with rapidly progressive skin ulceration, the direct microscopical examination with potassium hydroxide is conclusive for treatment. When correctly interpreted the direct examinations allows the institution of therapeutics until the tissue invasion is confirmed by biopsy. The isolation of *Mucorales* in culture, without evidence in the direct or histopathological examination may only indicate a fungal contamination.

The association of mucormycosis and diabetic ketoacidosis is recognized in about 50% of the clinical cases. The main underlying factor seems to be acidosis. ELDER & BAKER⁸ demonstrated experimentally that hyperglycemia "per se" is not enough to favour the infection in rabbits, but when associated with internal acidity it causes the progression of the infection to a definitive disease. Several changes related to the inflammatory response and phagocytosis have been described in diabetic ketoacidosis^{21,26}. Recently it was reported that "in vitro" the serum of patients in ketoacidosis, shows a significant decrease in transferrin capacity to bind iron and this alteration abolishes important host defense mechanisms¹. Probably there are other factors related to the susceptibility of these individuals to the fungus infection. The thermophily of some *Mucorales* associated with the affinity to acid pH culture media and the high glucose concentration make the keto-acidotic blood the ideal "habitat" for the fungus, especially when the immunological response is decreased.

The conditions described in association with the break of skin barrier in some cases of cutaneous or subcutaneous mucormycosis are: combination of heat, local pressure and epidermal maceration under contaminated dressings^{9,11}; surgical skin incisions^{10,20}; corticosteroid intramuscular injection¹⁶; burns⁷ and even apparently normal skin³. *Rhizopus sp.* is

the agent most frequently isolated^{9,10,15} and when the specific identification was possible, *R. oryzae* and *R. rhizopodiformis* were found^{11,15}. Although we did not isolate any *Mucorales* from the dressings in our patient, the possibility that a contamination of the venous puncture site could occur cannot be ruled out. On the other hand, the isolation of *R. oryzae* from the patient's room make it possible that the venous puncture site infection has been caused by a contamination by air borne spores.

RESUMO

Mucormicose subcutânea causada por *Rhizopus oryzae*. Provável infecção hospitalar

Os Autores relatam caso de mucormicose subcutânea em paciente apresentando quadro clínico e laboratorial de ceto-acidose diabética. São descritos os aspectos clínicos, micológicos e histopatológicos, salientando-se a importância da obtenção do diagnóstico rápido para a instituição da terapêutica precoce.

São revistas as formas clínicas da mucormicose e as principais condições associadas, bem como os possíveis mecanismos que facilitam a infecção por *Mucorales* em pacientes com ceto-acidose diabética.

O isolamento de *R. oryzae* do ambiente onde o paciente esteve internado, sugere tratar-se provavelmente de infecção hospitalar adquirida por contaminação venosa através de esporos do fungo.

REFERENCES

1. ARTIS, W. M.; FOUNTAIN, J. A.; DECLCHER, H. K. & JONES, H. E. — A mechanism of susceptibility to mucormycosis in diabetic ketoacidosis: Transferrin and iron availability. *Diabetes* 31: 1108-1114, 1983.
2. BAKER, R. D. — The epidemiology of mucormycosis. In: AL DOORY, Y. — *The Epidemiology of Human Mycotic Diseases*. Springfield, Charles C. Thomas, 1975, 197-209.
3. BATEMAN, C. P.; UMLAND, E. T. & BECKER, L. E. — Cutaneous zygomycosis in a patient with lymphoma. *J. Am. Acad. Dermatol.* 8: 890-894, 1983.
4. BHADURI, S.; KURRLE, E.; VANEK, E. & SPANEL, R. — Mucormycosis in the immunocompromised host. *Infection* 11: 170-172, 1983.
5. BITTENCOURT, A. L.; MELO, C. R.; JALIL, O. A. M. & ANDRADE, Z. A. — Basidiobolomycose. Apresentação de um caso. *Rev. Inst. Med. trop. São Paulo* 19: 208-212, 1977.
6. CHANDLER, A. W.; KAPLAN, W. & AJELLO, L. — *Histopathology of Mycotic Diseases*. London, Wolfe Medical Publications, 1980, 122-127.
7. CHUNTRASAKUL, C. & CHANTARAKUL, N. — Mucormycosis in severely burned patients. Report of two cases with extensive destructive lesions. *J. Med. Assoc. Thai.* 66: 135-138, 1983.
8. ELDER, T. D. & BAKER, R. D. — Pulmonary mucormycosis in rabbits with alloxan diabetes. *Arch. Path.* 61: 159-168, 1956.
9. EVERETT, E. D.; PEARSON, S. & ROGERS, W. — *Rhizopus* surgical wound infection associated with elasticized adhesive tape dressings. *Arch. Surg.* 114: 738-739, 1979.
10. FEUILHADE, M.; REVUZ, J. & TOURAINE, R. — Mucormycose cutanée primitive chez un transplanté renal. *Ann. Dermatol. Venerol.* 109: 765-766, 1982.
11. GARTENBERG, G.; BOTTONI, E. J.; KEUSCH, G. & WEITZMAN, I. — Hospital acquired mucormycosis (*Rhizopus rhizopodiformis*) of skin and subcutaneous tissue. *N. Engl. J. Med.* 299: 1115-1118, 1978.
12. GREER, D. L. — Agents of zygomycosis (Phycomycosis). In LENETTE, E. H.; BALOWS, A.; HAUSLER, J. R. & TRUANT, J. P. — *Manual of Clinical Microbiology*. (Third/ed.). Washington, American Society for Microbiology, 1980, 611-619.
13. GUIMARÃES, N. S. & BARRETO, E. R. M. — Zigo-micose subcutânea. *An. Bras. Dermatol.* 58: 277-280, 1983.
14. HAMMER, G. S. — Mucormycosis in a transplante patient. *Am. J. Clin. Path.* 64: 389-398, 1975.
15. HAMMOND, D. E. & WINKELMANN, R. K. — Cutaneous phycomycosis. Report of three cases with identification of *Rhizopus*. *Arch. Dermatol.* 115: 990-992, 1979.
16. JAIN, J. K.; MARKOWITZ, A.; KHILANANI, P. V. & LAUTER, C. B. — Localized mucormycosis following intramuscular corticosteroid. Case report and review of the literature. *Am. J. Med. Sci.* 275: 209-216, 1978.
17. KRICK, J. A. & REMINGTON, J. S. — Opportunistic invasive fungal infections in patients with leukaemia and lymphoma. *Clin. Haematol.* 5: 249-310, 1976.
18. LACAZ, C. da S.; PORTO, E. & MARTINS, J. E. C. — Zigo-micose. In *Micologia Médica. Fungos, Actinomicetos e Algas de Interesse Médico*. 7.ª ed. São Paulo. Sarvier, 1984.

19. MARCHEVSKY, A. M.; BOTTONI, E. J.; GELLER, S. A. & GIGER, D. K. — The changing spectrum of a disease, etiology, and diagnosis of mucormycosis. *Human Pathol.* 11: 457-464, 1980.
20. MEAD, J. H.; LUMPTON, G. P.; DILLAVOU, C. L. & ODOM, R. B. — Cutaneous *Rhizopus* infection. Occurrence as a postoperative complication associated with an elasticized adhesive dressing. *J.A.M.A.* 242: 272-274, 1979.
21. PEREIRA, V. G.; PEREIRA, M. A. A.; CRUZ, J. O. B. & HARON, E. S. — Mucormicose rino-orbitária. Relato de um caso. *Rev. Hosp. Clin. Fac. Med. São Paulo* 37: 140-146, 1982.
22. RIPPON, J. W. — Mucormycosis. In: *Medical Mycology. The pathogenic fungi and the pathogenic actinomycetes.* (2nd.). Philadelphia, W.B. Saunders, 1982, 615-640.
23. SHELDON, D. L. & JOHNSON, W. C. — Cutaneous mucormycosis: Two documented causes of suspected nosocomial cause. *J.A.M.A.* 241: 1032-1034, 1979.
24. SZEPEK, E. & GROF, P. — Subcutaneous mucormycosis. *Mykosen* 25: 503-507, 1982.
25. VELIATH, A. J.; RAO, R.; RADAHKRISHNA, P. & AURORA, A. L. — Cutaneous Phycomycosis (*Mucormycosis*) with fatal pulmonary dissemination. *Arch. Dermatol.* 112: 509-512, 1976.
26. WHEAT, L. J. — Infection and diabetes mellitus. *Diabet. Care.* 3: 187-191, 1980.
27. WILSON, C. B.; SIBER, G. R. & O'BRIEN, T. F. — Phycomycotic gangrenous cellulitis. *Arch. Surg.* 111: 532-538, 1976.

Recebido para publicação em 14/6/1984.