

## Thrombotic thrombocytopenic purpura associated with dengue and chikungunya virus coinfection: case report during an epidemic period

Maria Luiza Almeida Bastos<sup>1</sup>, Ruth Maria Oliveira de Araújo<sup>2</sup>, Deivide de Sousa Oliveira<sup>2</sup>, Ana Nery Melo Cavalcante<sup>1</sup>, Geraldo Bezerra da Silva Junior<sup>1</sup>

### ABSTRACT

The present report shows the occurrence of thrombotic thrombocytopenic purpura (TTP) associated with acute dengue and chikungunya virus coinfection, manifesting as a severe disease with high mortality potential. The patient was a 28 year-old man with clinical and epidemiological diagnosis of arboviruses infections who developed thrombocytopenia and anemia, after which oral corticosteroid therapy was started. On the third day of hospitalization, he showed neurological alterations that simulated a cerebral vascular accident, but the imaging examination did not identify ischemic or hemorrhagic alterations. At that moment, the TTP hypothesis was raised so that plasmapheresis and corticosteroid pulse therapy were started, have been essential for the favorable evolution of the case.

**KEYWORDS:** Chikungunya virus. Dengue virus. Coinfection. Thrombotic thrombocytopenic purpura.

### INTRODUCTION

Thrombotic microangiopathies (TMA) are a heterogeneous group of potentially fatal diseases<sup>1-4</sup>. The most severe short-term TMA is thrombotic thrombocytopenic purpura (TTP)<sup>2</sup>. The pathophysiology of this disease is due to the formation of microthrombi in the endothelium due to platelet hyperaggregation to the non-cleaved von Willebrand factor (VWF) 1 multimers. ADAMTS13 (a disintegrin and metalloproteinase with a thrombospondin type 1 motif, member 13) is the protein responsible for the cleavage of vWF multimers. Its deficiency may be congenital (cTTP) or acquired, usually of autoimmune origin<sup>1-4</sup>.

Acquired TTP is usually mediated by anti-ADAMTS13 antibodies or immune mediated Thrombotic Thrombocytopenic Purpura (iTTP). It presents as microangiopathic hemolytic anemia, thrombocytopenia and neurological alterations<sup>2</sup>. The presentation is acute in most cases and invariably fatal, if not treated adequately<sup>3</sup>.

Infections are important causes of immune responses in the context of iTTP<sup>5</sup>. Reports of TTP secondary to parvovirus B19, dengue, HIV and viral hepatitis demonstrate the potential of viral infections to act as a triggering factor of microangiopathic diathesis<sup>6-9</sup>. The present case report describes iTTP secondary to dengue and chikungunya virus coinfection in the current epidemic of arbovirus infections in a State in Northeastern Brazil.

<sup>1</sup>Universidade de Fortaleza, Programa de Pós-Graduação em Saúde Coletiva, Fortaleza, Ceará, Brazil

<sup>2</sup>Universidade Federal do Ceará, Faculdade de Medicina, Hospital Universitário Walter Cantídio, Fortaleza, Ceará, Brazil

**Correspondence to:** Geraldo Bezerra da Silva Junior

Universidade de Fortaleza, Programa de Pós-Graduação em Saúde Coletiva, Av. Washington Soares, 1321, Bloco S, Sala S-01, CEP 60811-905, Fortaleza, CE, Brazil  
Tel/Fax: +55 85 3477 3280 / +55 85 3477 3424

**E-mail:** [geraldobezerrajr@yahoo.com.br](mailto:geraldobezerrajr@yahoo.com.br), [mluiza@edu.unifor.br](mailto:mluiza@edu.unifor.br)

**Received:** 11 April 2018

**Accepted:** 15 August 2018

**Table 1** - Temporal evolution of Hb (g / dL), platelets (/ mm<sup>3</sup>) and LDH (U / L). On the 5<sup>th</sup> day, the plasma exchange started

	D0	D3	D6	D7	D8	D9	D10	D11	D12	D13	D17
Hb (g/dL)	8.0	6.4	6.3	7.4	7.3	7.8	9.5	9.9	10.6	11.6	<b>10.3</b>
Platelets (/mm <sup>3</sup> )	12.000	11.000	34.000	54.000	105.000	156.000	202.000	239.000	301.000	398.000	<b>366.000</b>
LDH (U/L)	1.166	1.461			660	445	775	481	364	444	<b>339</b>
Reticulocyte (relative %)	<b>1,9</b>	<b>6</b>									

\*Reference value: Hb = 13,5-18,0 g/dL; Platelets = 140.000- 450.000; LDH = 200 -480 U/L; Reticulocyte count relative (%) = 0,5 – 2,3

## CASE REPORT

A 28-year-old male patient with a previous history of immune thrombocytopenic purpura (ITP), diagnosed six years ago but had stopped had treatment approximately five years ago, was hospitalized with clinical and epidemiological diagnosis of arbovirus infection (fever, asthenia, myalgia and arthralgia). On admission, thrombocytopenia (12,000/mm<sup>3</sup>) and anemia (8.0 g/dL) were observed (Table 1). Oral corticosteroid therapy was started with prednisone 1 mg/kg/day. On the third day of hospitalization, he had headache with vomiting, associated with mental confusion and, subsequently, motor aphasia and right hemiplegia. Considering the sudden worsening of the patient's overall conditions, he was referred to the intensive care unit. Nuclear magnetic resonance imaging of the brain was performed to rule out acute ischemic or hemorrhagic events. The neuroimaging examination showed no alterations. Faced with an acute neurological worsening, the possibility of TTP was considered. Analysis of the peripheral smear showed innumerable schizocytes, confirming the presence of TMA. Plasmapheresis and pulse therapy with methylprednisolone were started due to the hypothesis of TTP.

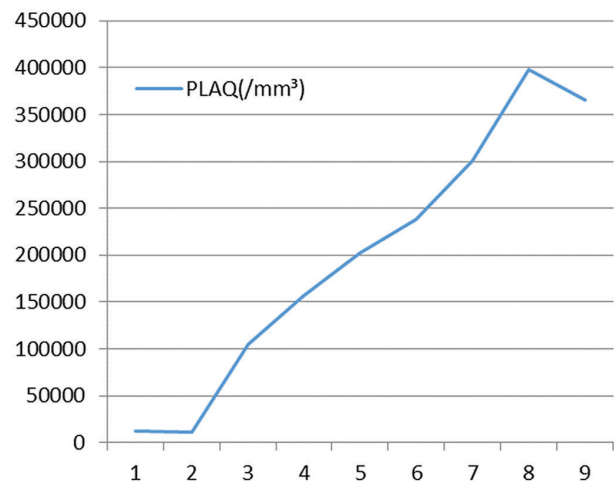
Serological results were IgM positive for chikungunya and dengue viruses, and initially, the presence of IgG only raised to chikungunya virus (Euroimmun Medizinische Labordiagnostika, Lübeck, Germany). Serological tests for hepatitis virus B and C were negative, as well as for retroviruses (only HIV). Regarding retroviruses, other representatives are not routinely investigated and, in this case, they were not suspected. The patient also had negative results for antinuclear antibody (ANA) (Table 2). During the follow-up, serological results for dengue and chikungunya were confirmed, at this time showing the presence of IgG antibodies to chikungunya as well as to dengue virus. The serological test for zika virus was not performed following guidelines from Brazilian Ministry of Health, which recommend not to test zika virus when serological tests for dengue and chikungunya are positive.

There was a decrease in lactate dehydrogenase (LDH) (Table 1). Plasmapheresis was maintained until platelet

**Table 2** - Serologic assessment showing the presence of IgM/IgG anti CHIKV and IgM antiDen. ADAMTS13 low activity and the presence of an inhibitor confirms the diagnosis of TTP

Serologic assessment	D3	D17
Dengue IgM/IgG	reactive/ nonreactive	reactive/reactive
Chikungunya IgM/IgG	reactive/reactive	reactive/reactive
ANA	nonreactive	
Anti HIV1-2	nonreactive	
VDRL	nonreactive	
antiHBS	nonreactive	
antiHCV	nonreactive	
HbsAg	nonreactive	
Activity ADAMTS13/ ADAMTS13 inhibitor	4%/ reactive	

counts remained higher than 150,000 for three consecutive days (Figure 1). Complete remission of neurological signs occurred after the first plasmapheresis.

**Figure 1** - Platelets (/mm<sup>3</sup>) from the day of arrival until discharge. The patient underwent plasmapheresis from day 2 to day 5

## DISCUSSION

There have been rare descriptions in the literature of TTP association with chikungunya fever, or coinfection

with other arboviruses, such as dengue virus<sup>6-9</sup>. The aim of this publication is to provide data for further studies and alert health teams to identify arboviruses-related emergency associations.

This case report describes a severe hematological complication associated with emerging arboviruses, such as chikungunya virus, which is endemic in Brazil in a coinfection with dengue virus. The patient was admitted with unspecific symptoms, including fever, myalgia and arthralgia, which is common to the three currently endemic arboviruses in Brazil. As the symptomatology is not specific of any of the three arboviruses, they may vary from patient to patient, in most cases only serological tests can differentiate one infection from another, according to the current literature<sup>10</sup>.

The formation of anti-ADAMTS13 antibodies has been implicated in the genesis of many cases of acquired TTP<sup>4</sup>. In this context, infections are important triggers for microangiopathic diathesis<sup>5</sup>. The patient had TMA-compatible clinical manifestations. The presence of acute neurological alterations is compatible with TTP. In addition, serological results together with clinical manifestations and the occurrence of arboviruses epidemic in Northeastern Brazil confirm the diagnosis of dengue and chikungunya virus coinfection in this case.

Chikungunya fever is a disease spread by mosquitos of the *Aedes aegypti* genus. It belongs to the genus alphavirus, has RNA as its genetic material and enters host cells through the envelope of glycoproteins, especially E1 and E2. The first cases were described in 1952-1953 in Africa<sup>5</sup>. The disease symptomatology is most often joint-related, with a recent description of potentially severe neurological and immunological phenomena such as encephalitis<sup>5</sup>, Guillain-Barré syndrome<sup>5,11</sup> and immune-mediated thrombocytopenia<sup>11</sup>. The arrival of the virus in Brazil was probably due to the 2014 World Cup, when zika and chikungunya viruses became part of the arboviruses circulating in the country<sup>5</sup>.

Dengue fever is an endemic disease in Northeast Brazil, with episodes of cyclic epidemics, especially during the rainy season at the beginning of each year. It is also transmitted by mosquitos<sup>11</sup>. It belongs to the genus flavivirus and has RNA as its genetic material. The infection is most often asymptomatic, with some patients developing arthralgia, thrombocytopenia and episodes of vascular extravasation, which, if not adequately managed, can progress to severe forms. Dengue may be associated with neurological and hematological complications<sup>12</sup>, among others.

The two arboviruses infections may present with myalgia, headache, arthralgia and thrombocytopenia. Anemia is not a common finding for these diseases<sup>12,13</sup>. Coinfection can occur, especially because the two viruses share the same

vector, the *Aedes aegypti* mosquito. TTP cases were reported in association with dengue fever<sup>6,7</sup> and Congo-Crimean hemorrhagic fever with chikungunya infection<sup>8</sup>.

Severe deficiency of the ADAMTS 13 protein (defined as activity below 10%) plays an important role in the genesis of TTP. This proteinase cleaves the vWF multimer, which participates in the coagulation and platelet aggregation pathways<sup>1</sup>.

In this case, the patient was at first clinically and epidemiologically diagnosed with an arbovirus infection due to the dengue and chikungunya fever epidemic in Northeastern Brazil. Subsequently, worsening of anemia, thrombocytopenia, neurological alterations and the presence of schizocytes in the peripheral blood smear suggested the diagnosis of TMA<sup>7,8</sup>. The ADAMTS 13 activity below 10% and positive serological tests (IgM and IgG) to dengue and chikungunya confirmed the arboviruses coinfection associated with iTTP secondary to the arboviruses infections.

## CONCLUSION

Although there is a lot of information on hematological complications of dengue virus infections, there same is not true regarding chikungunya virus infections. In this context, due to the severity and lethality of TTP, it is important that health professionals are prepared to identify similar cases and that adequate therapy is instituted in a timely manner. More studies are required to evaluate the impact of dengue and chikungunya virus infection on the genesis of TMA, especially TTP.

## CONFLICT OF INTEREST

There are no conflicts of interest between the investigators and the patient, who authorized the reporting of his case by signing the free and informed consent form.

## FUNDING

The researchers received subsidies from Alexion Pharmaceuticals and Merck Sharp Dohme. GBSJ received grant from Brazilian Research Council (Conselho Nacional de Desenvolvimento Científico e Tecnológico - CNPq) – PQ2.

## REFERENCES

1. Benhamou Y, Boelle PY, Baudin B, Ederhy S, Gras J, Galicier L, et al. Cardiac troponin-I on diagnosis predicts early death and refractoriness in acquired thrombotic thrombocytopenic purpura. *J Thromb Haemost.* 2015;13:293-302.

2. Bendapudi PK, Li A, Hamdan A, Uhl L, Kaufman R, Stowell C, et al. Impact of severe ADAMTS13 deficiency on clinical presentation and outcomes in patients with thrombotic microangiopathies: the experience of the Harvard TMA Research Collaborative. *Br J Haematol.* 2015;171:836-44.
3. Bendapudi PK, Makar RS. An algorithmic approach to the diagnosis and management of the thrombotic microangiopathies. *Am J Clin Pathol.* 2016;145:152-54.
4. Kremer Hovinga JA, Coppo P, Lämmle B, Moake JL, Miyata T, Vanhoorelbeke K. Thrombotic thrombocytopenic purpura. *Nat Rev Dis Primers.* 2017;3:17020.
5. Booth KK, Terrell DR, Versely SK, George JN. Systemic infections mimicking thrombotic thrombocytopenic purpura. *Am J Hematol.* 2011;86:743-51.
6. Deepahjali S, Naik RR, Mailankody S, Kalaimani S, Kadiravan T. Dengue virus infection triggering thrombotic thrombocytopenic purpura in pregnancy. *Am J Trop Med Hyg.* 2015;93:1028-30.
7. Ehelepolar ND, Gunawadhan MB, Sudusinghe TN, Sooriyaarachchi SK, Manchanayake SP, Kalupahana KL. A dengue infection without bleeding manifestation in an adult with immune thrombocytopenic purpura. *Trop Med Health.* 2016;44:36.
8. Epelboin L, Bidaud B, Mosnier E, Le Turnier P, Vesin G, Walter G, et al. Fatal case of Chikungunya and concomitant thrombotic thrombocytopenic purpura in French Guiana during air flight medical evacuation. *J Travel Med.* 2017;24:tax028.
9. Gavali AS, Shelgaonkar J, Bartakke S. Thrombotic thrombocytopenic purpura in a case of fever dengue: rare presentation. *Indian J Crit Care Med.* 2017;21:226-8.
10. Patterson J, Sammon M, Garg M. Dengue, Zika and Chikungunya: emerging arboviruses in the New World. *West J Emerg Med.* 2016;17:671-9.
11. Staples JE, Breiman RF, Powers AN. Chikungunya fever: an epidemiological review of a re-emerging infectious disease. *Clin Infect Dis.* 2009;49:942-8.
12. Albuquerque PL, Silva Júnior GB, Diógenes SS, Silva HF. Dengue and aplastic anemia: a rare association. *Travel Med Infect Dis.* 2009;7:118-20.
13. Ferreira ML, Cavalcanti CG, Coelho CA, Mesquita SD. Manifestações neurológicas de dengue: estudo de 41 casos. *Arq Neuropsiquiatr.* 2005;63:488-93.