

NEPHROTOXICITY ATTRIBUTED TO MEGGLUMINE ANTIMONIATE (GLUCANTIME) IN THE TREATMENT OF GENERALIZED CUTANEOUS LEISHMANIASIS

M.L.O. RODRIGUES(1), R.S. COSTA(2), C.S. SOUZA(1), N.T. FOSS(1) & A.M.F. ROSELINO(1)

SUMMARY

Background: Pentavalent antimonials have become of basic importance for the treatment of leishmaniasis. Their most severe side effects have been reported to be increased hepatic enzyme levels and electrocardiographic abnormalities. Nephrotoxicity has been rarely related.

Observations: We report a case of generalized cutaneous leishmaniasis involving a 50-year old male patient who was submitted to treatment with meglumine antimoniate (Glucantime). He developed acute renal failure (ARF) due to acute tubular necrosis (ATN), followed by death after receiving a total of 53 ampoules of Glucantime.

Conclusions: The treatment with Glucantime was responsible by ARF diagnosed in this patient. The previous urine osmolarity and serum creatinine levels were normal and the autopsy showed ATN. It should be pointed out if ARF may also be explained by massive deposits of immunocomplexes by leishmania antibodies and antigens due to the antigenic break by the antimonial compound, since our patient presented countless lesions covering the entire tegument, similar to the Hexheimer phenomenon, but at the autopsy no glomerular alterations were seen.

KEYWORDS: Leishmaniasis; Antimonials; Nephrotoxicity.

INTRODUCTION

Leishmaniasis is a primarily zoonotic parasitic disease involving animals other than man, who may become infected after insect biting. Cutaneous and visceral leishmaniasis are caused by protozoa of the genus *Leishmania*¹⁰. The persistence of active focal points in the remaining wooded zones of Brazil is responsible for cases of cutaneous leishmaniasis, explaining the increase in the number of cases recorded in the State of São Paulo⁵.

At our hospital we treat cutaneous and mucocutaneous leishmaniasis with 10 to 20 mg/kg/day of meglumine antimoniate (Glucantime) for 20 and 30 days, respectively. The most important side effects of the drug are cardiotoxicity, hepatotoxicity and nephrotoxicity³. After treating more than 200 cases of cutaneous and mucocutaneous leishmaniasis in the last 19 years at our hospital, half of them were autochthonous¹, we report here the first patient with the disease who died possibly due to treatment with Glucantime.

CASE REPORT

We report a 50-year old male patient with papulotuberculous and

erythematous-violaceous lesions, some of them with central ulcerations, disseminated throughout the tegument, including the head, of one month and a half duration (Figure 1). Otorhinolaryngologic examination revealed hyperemia and edema of the nasal mucosa. Skin biopsies from the face, trunk and leg confirmed the presence of amastigote forms of *Leishmania* sp using a rabbit anti-*Leishmania* sp as the primary antibody on the immunoperoxidase technique using avidin-biotin peroxidase complex (Figure 2 A, B). No abnormalities were detected upon physical examination, except for hypertension (18 x 12 mmHg) and obesity (weight = 148 kg; height = 1.73 m). Laboratory tests were normal (urinalysis; blood count: white cells 5,800, hemoglobin 14.5, lymphocytes 24.6%; blood creatinine 1.1 mg%, BUN 19.8 mg%, glucose 96.5 mg%, cholesterol 249 mg%, triglycerides 141 mg%, HDL 33 mg%). GOT was 16 U/l, GPT 23 U/l, alkaline phosphatase 56 U/l, and gamma GT 43.3 U/l. The ECG was normal, an anti-HIV test was negative, and the Montenegro test was positive.

Treatment with Glucantime was started as follows: 1 ampoule administered i.v. for 1 day, 2 ampoules/day for 2 days, and 3 ampoules/day thereafter. On the 15th day the patient was discharged

(1) The Division of Dermatology, Department of Internal Medicine.

(2) Department of Pathology, University of São Paulo, Faculty of Medicine of Ribeirão Preto, Brasil.

Correspondence to: Mirian Lane de O. Rodrigues, MD. Division of Dermatology, Faculty of Medicine of Ribeirão Preto, USP. Av. Bandeirantes 3900, 14049-900 Ribeirão Preto, SP, Brazil. Tel/Fax: 55.16.633-0236. E-mail: mirian@fmrp.usp.br

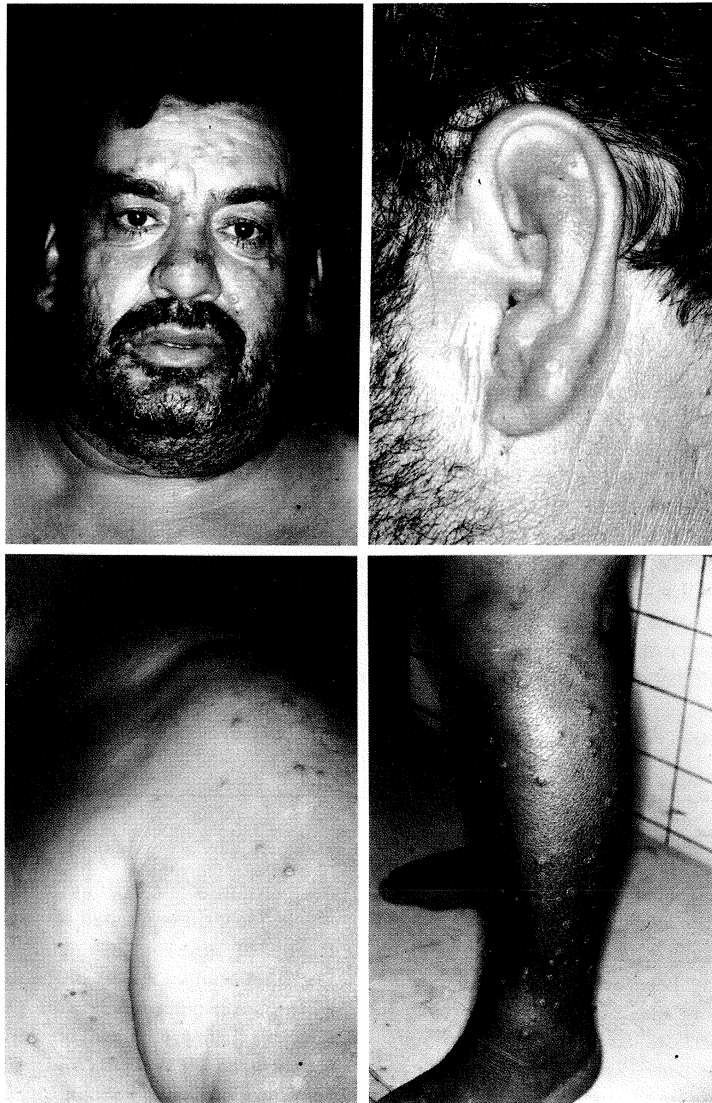


Fig. 1 - Generalized papulo-tuberculous skin lesions are observed. Some of them presented central ulcerations.

on maintenance treatment, but he returned one week later reporting intense myalgia, reduced appetite, vomiting, pain and edema of the lower limbs. Serum creatinine was increased (5.6 mg/dl), BUN was 71 mg/dl, and the patient presented anuria and increased central venous pressure. The ECG showed sinus tachycardia, short P-R interval, and an abnormal T wave, considered to represent lower ischemia. The patient died after receiving a total of 53 ampoules of Glucantime.

The autopsy showed morbid obesity, acute chest congestion, fibrinous pericarditis with great pericardium effusion besides concentric hypertrophy of the left ventricle, and fibrous consistence and nodular hepatic superficies. Histological sections of the liver showed disorganized architecture due to intense fibrosis joining together the portal spaces with the formation of nodules. A marked mononuclear inflammatory

infiltrate was also observed in the portal spaces, with individual hepatocyte necrosis and signs of regeneration. Micro and macrofocular steatosis and canalicular cholestasis were also present. A diagnosis of cirrhosis and active chronic hepatitis was made (Figure 2D).

Histological sections of the kidneys showed no alterations in the glomerular, interstitial and vascular compartments. In contrast, in the tubular compartment there was acute tubular necrosis (ATN) characterized by tubular dilatation, presence of intraluminal casts with necrosis of epithelial cells, and tubular basement membrane denudation (Figure 2C). Sections of the lung showed marked congestion and hemorrhage. No leishmanias were observed in these organs using the immunoperoxidase technique described before.

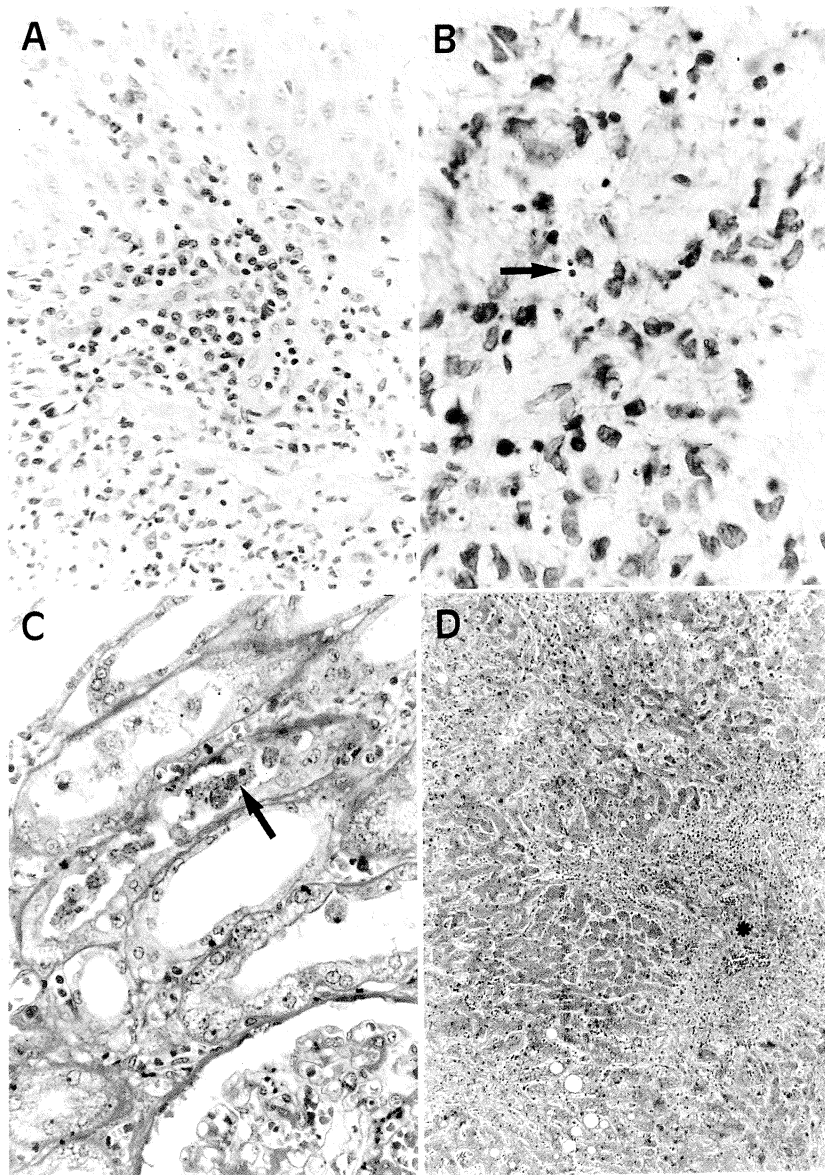


Fig. 2 - A: Skin biopsy shows mononuclear inflammatory infiltration in the dermis, with presence of plasmocytes (Hematoxylin-Eosin, x1500). B: Multiple amastigotes forms of leishmania detected by rabbit anti-*Leishmania* sp antibody (Immunoperoxidase technique, x3860). C: Histological section of kidney showing an acute tubular necrosis characterized by dilatation of proximal tubules with attenuation of the brush border and flattened epithelium, and the frequent loss of epithelial integrity, and cell desquamation (arrow) and tubular basement membrane denudation (Masson's trichrome, x1500). D: Histological sections of the liver shows disorganized architecture due to intense fibrosis joining together the portal spaces and mononuclear inflammatory infiltrate with the formation of nodules. Micro- and macrofototcular steatosis and canalicular cholestasis were also present (Masson's trichrome, x386).

DISCUSSION

Pentavalent antimonials were introduced before World War II and became basic drugs for the treatment of tegumental and visceral leishmaniasis. They are considered to be of low toxicity, depending on the cumulative doses used, and are rapidly excreted by the kidneys¹². Two pentavalent antimonials commonly used for the treatment of leishmaniasis are sodium stibogluconate (Pentostam) and meglumine antimoniate (Glucantime)². Glucantime has been more accepted in Brazil, where it is

distributed by the Ministry of Health³. The dose recommended by the WHO is 20 mg/kg/day. Since the present patient weighed approximately 150 kg, the dose used was supposed to be 3,000 mg/day. The mean dose used at our hospital for adult patients weighing 60 kg is 2 ampoules per day, i.e., 850 mg/day. On the basis of the report by HERWALDT & BERMAN⁷, and the obesity of this patient, we decided to prescribe 3 ampoules per day, i.e., 1,275 mg/day.

The most severe side effects reported with the use of antimonials

are elevated hepatic transaminases and electrocardiographic abnormalities^{9,11,16}.

When admitted to the hospital, the patient presented normal renal and hepatic function and only used the antimonial compound during hospitalization and after discharge. Fifteen days after starting Glucantime he developed acute renal failure (ARF) followed by death. The hepatitis and cirrhosis observed at autopsy was attributed to chronic alcoholism. Although the patient had a history of alcoholism, he did not present clinically diagnosed hepatic decompensation because of the absence of jaundice and hepatosplenomegaly. Furthermore, his laboratory tests were normal. It should be pointed out that antimonial compounds may cause a certain degree of hepatic involvement during treatment that may persist a few months after their discontinuation. Hepatitis is a rare but severe complication⁶.

Reports about renal compromise due to antimonial compounds are rare^{4,8,13,14,15}. A defect in the urine concentration has been attributed to the antimonials, probably due to its antagonist effect on neurohypophysis hormone^{4,14}.

This patient presented ARF after receiving 53 ampoules of Glucantime. His previous urine osmolarity and serum creatinine levels were normal. Other causes of prerenal or drug-induced ARF were ruled out by clinical examination since there were no symptoms of volemic losses or use of others drugs. The autopsy showed ATN responsible by ARF detected in our patient, also reported by CUCÉ et al.⁴ ARF may also be explained by massive deposits of immunocomplexes by leishmania antibodies and antigens due to the antigenic break by the antimonial compound, since the patient presented countless lesions covering the entire tegument, similar to the Hexheimer phenomenon but at the autopsy no glomerular alterations were seen. Another hypothesis is the hepatorenal syndrome, i.e., renal involvement secondary to hepatic failure, but the patient did not present the corresponding laboratory alterations or hepatic encephalopathy, and in those cases renal microscopy usually shows no abnormalities.

A second patient from our service (unpublished results) with mucosal leishmaniasis recently presented ARF after 12 days of Glucantime treatment. This patient had AIDS with opportunistic cryptococcal infections, but his case was not fully elucidated because autopsy was not performed.

In view of the above considerations, we wonder whether it would be opportune to start treatment with low doses of antimonials. For the present patient, the initial dose was 1 ampoule of Glucantime for one day, followed by 2 ampoules for 2 days and by maintenance treatment with 3 ampoules/day. It is our opinion that the dose could have been increased gradually, although we had previously treated other patients with disseminated cutaneous leishmaniasis with the habitual dose with a satisfactory outcome.

This is the report of a case of leishmaniasis in which we utilized a very high dose of glucantime based on the weight of the patient, which caused his death due to acute tubular necrosis.

We believe that this report will serve to guide other physicians

who, when facing similar cases, will have the opportunity to evaluate the best dose of glucantime to be used, without considering, in specific cases, the total amount based on the mg/kg/day dosage.

RESUMO

Nefrotoxicidade atribuída ao Glucantime no tratamento da Leishmaniose cutânea generalizada

Antimoniais pentavalentes são importantes no tratamento da leishmaniose. Seus efeitos mais graves que têm sido relatados são o aumento do nível de enzimas hepáticas e anormalidades electrocardiográficas. Nefrotoxicidade tem sido raramente relatada.

Nós relatamos um caso de leishmaniose cutânea generalizada, envolvendo um paciente masculino de 50 anos de idade, que foi submetido ao tratamento com Glucantime. Ele desenvolveu insuficiência renal devido a necrose tubular aguda e depois veio a óbito; após receber um total de 53 ampolas de Glucantime. O tratamento com o Glucantime foi o responsável pela necrose tubular aguda diagnosticada em nosso caso.

REFERENCES

1. ALBERTO, F.L.; CRUZ, A.K.; ALMEIDA, A.M. & ROSELINO, A.M.F. - *Leishmania amazonensis* no interior do Estado de São Paulo? In: ANAIS DO CONGRESSO BRASILEIRO DE DERMATOLOGIA, 48, Curitiba, 1993. p. 162.
2. BENENSON, A.S. - Leishmaniasis. I. Leishmaniasis cutanea y mucocutanea. In: BENENSON, A.S. *El control de las enfermedades transmisibles en el hombre: informe oficial de la Asociación Estadounidense de Salud Pública*. 15. ed. Washington, OPS, 1992. p. 322-326.
3. BRASIL. MINISTÉRIO DA SAÚDE - *Leishmaniose tegumentar americana no Brasil*. Brasília, 1996.
4. CUCÉ, L.C.; BELDA JÚNIOR, W. & DIAS, M.C. - Nephrotoxicity to Glucantime® in the treatment of leishmaniasis. *Rev. Inst. Med. trop. S. Paulo*, 32: 249-251, 1990.
5. GOMES, A.C. - Epidemiological profile of cutaneous and mucocutaneous leishmaniasis in Brazil. *An. bras. Derm.*, 67: 55-60, 1992.
6. HARVEY, S.G. - Heavy metals. In: GOODMAN, L.S. & GILMAN, A., ed. *The pharmacological basis of therapeutics*. 5. ed. New York, MacMillan, 1975. p. 924-945.
7. HERWALDT, B.L. & BERMAN, J.D. - Recommendations for treating leishmaniasis with sodium stibogluconate (Pentostam) and review of pertinent clinical studies. *Amer. J. trop. Med. Hyg.*, 46: 296-306, 1992.
8. JOLLIFFE, D.S. - Nephrotoxicity of pentavalent antimonials. *Lancet*, 9: 584, 1985.
9. KOFF, A.B. & ROSEN, T. - Treatment of cutaneous leishmaniasis. *J. Amer. Acad. Derm.*, 31: 693-708, 1994.
10. LAINSON, R. & SHAW, J.J. - Epidemiology and ecology of leishmaniasis in Latin-America. *Nature (Lond.)*, 273: 595-600, 1978.

11. MELBY, P.C.; KREUTZER, R.D.; MCMAHON-PRATT, D; GAM, A.A. & NEVA, F.A. - Cutaneous leishmaniasis: review of 59 cases seen at the National Institutes of Health. *Clin. infect. Dis.*, **15**: 924-937, 1992.
12. REES, P.H.; KEATING, M.I.; KAGER, P.A. & HOKMEYER, W.T. - Renal clearance of pentavalent antimony (sodium stibogluconate). *Lancet*, **2**: 226-229, 1980.
13. SAMPAIO, R.N.R.; ROCHA, R.A.A.; MARSDEN, P.D. et al. - American cutaneous leishmaniasis. Casuistry in the School Hospital of University of Brasília. *An. bras. Derm.*, **55**: 69-76, 1980.
14. VEIGA, J.P.R.; ROSA, T.T.; KIMACHI, T. et al. - Renal function in patients with mucocutaneous leishmaniasis treated with pentavalent antimonials. *Rev. Inst. Med. trop. S. Paulo*, **27**: 298-302, 1985.
15. VEIGA, J.P.R.; WOLFF, E.R.; SAMPAIO, R.N. & MARSDEN, P.D. - Renal tubular dysfunction in patients with mucocutaneous leishmaniasis treated with pentavalent antimonials. *Lancet*, **3**: 569, 1983.
16. WANKE, N.C.F.; BIRKENHAUER, M.C.; MACEIRA, J.M.P.; SILVA, F.C. & PEREZ, M. - American tegumentary leishmaniasis. Retrospective study of 65 cases. *An. bras. Derm.*, **66**: 49-54. 1991.

Received: 22 June 1998

Accepted: 03 December 1998

