

CASE REPORT

CUTANEOUS PROTOTHECOSIS: REPORT OF THE SECOND BRAZILIAN CASE

Ivonise FOLLADOR(1), Achiléa BITTENCOURT(2), Fernanda DURAN(3) & Maria das Graças ARAÚJO(4)

SUMMARY

The present report describes a case of cutaneous protothecosis caused by *Prototheca wickerhamii* in a non-immunocompromised female from the state of Bahia, Brazil. This is the second case described in Brazil. Dermatological examination revealed diffusely infiltrated erythematous plaques on the flexor aspect of the right arm and forearm. The authors emphasize the pathological aspects that can lead to misdiagnosis this condition. The patient was successfully treated with fluconazole.

KEYWORDS: *Prototheca wickerhamii*; Cutaneous protothecosis; Subcutaneous mycosis; Fluconazole.

INTRODUCTION

Protothecosis is an infection caused by the achlorophyllic algae of the genus *Prototheca*. Three species are known: *P. wickerhamii*, *P. zopfii* and *P. stagnora*, but only the first two have been known as agent of disease in humans and animals²⁶. There are more than 80 cases of protothecosis described in the literature^{7,10,13,14,19,20,21,23,26,35}; only one of which occurred in Brazil¹.

Prototheca is found in plant products, soil and water in tanks, lakes and sewage²⁶. Inoculation with *Prototheca* has been reported to occur during surgery and orthopedic procedures, through insect bites and trauma. Infection may also occur by penetration of the agent through any previous skin injury in contact with contaminated water^{3,17,25,26}.

Human protothecosis can manifest as a primary cutaneous form; an articular form (olecranon bursitis) and as a systemic infection that may also involve the skin^{3,6,24,26}. Cutaneous lesions are described as papules, nodules, plaques, verrucous lesions, and ulcerated and herpetiform lesions^{3,8,9,15,16,22,26}.

The aim of this paper is to present a case of cutaneous protothecosis with florid cutaneous lesions and peculiar pathological aspects.

CASE REPORT

A 72-year-old woman presents skin lesions since one year when the lesions appeared after trauma at a bus that resulted in skin abrasion in the right arm. The abrasion were washed and dressed with an antiseptic iodine solution. A few days later she started to feel moderate itching and

noted redness on the right arm. At this time, she began to use a potent corticosteroid cream containing clobetasol that she had used for more than 6 months. The itching continued and the lesions extended to the forearm. The patient has been living in Salvador-Bahia for more than 30 years and had no previous history of cutaneous or systemic disease.

Dermatological examination: Diffuse infiltrated erythematous plaques on the flexor aspect of the right arm and forearm which did not affect the cubital fold was seen (Fig. 1). No joint or systemic involvement was observed. No other clinical abnormalities were present and laboratory tests were within normal limits. Serological reactions against HIV and HTLV-I were negative. The diagnostic possibilities were sarcoidosis, lymphoma, leprosy and photosensitization dermatitis.

Pathological examination: A skin biopsy revealed moderate acanthosis and a granulomatous process with abscesses (Fig. 2). Round, birefractive structures were noted inside giant cells, in the abscesses and in the epidermis. The first slide stained with silver (Grocott method) gave the impression of yeast-like structures with multiple buds resembling *Paracoccidioides brasiliensis* (Fig. 3) but with a slightly silver impregnation, the typical morula element with symmetric subdivisions characteristic of *P. wickerhamii* was observed (Fig. 4). Alcian blue pH 2.4 stained the capsule of the organisms showing clearly the morula aspect (Fig. 5).

Culture: A biopsy specimen cultured on Sabouraud dextrose agar at 30 °C grew smooth, creamy white, yeastlike colonies after 48 hours (Fig. 6). Growth was inhibited by cycloheximide. A wet preparation stained with lactophenol cotton blue revealed the characteristic endospore-containing sporangium of *Prototheca* (Fig. 7). *P. wickerhamii* was characterized by the sugar assimilation test as previously described^{12,18}.

(1) Dermatologist of the Hospital Universitário Professor Edgar Santos, Federal University of Bahia (UFBA), Professor of Dermatology, School of Medicine, Escola Bahiana de Medicina e Saúde Pública (EBMSP), BA, Brazil.

(2) Professor of Pathology, School of Medicine, UFBA. Researcher of National Research Council (CNPq), BA, Brazil.

(3) Medical doctor, private clinic, BA, Brazil.

(4) Mycologist of the Central State Laboratory (LACEN), BA, Brazil.

Correspondence to: Dr Ivonise Follador, Hospital Universitário Professor Edgar Santos, Serviço de Dermatologia, 2º subsolo, Rua João das Botas s/n, Canela, 40110-160 Salvador, Bahia, Brazil. Phone: 55 71 3396000. E-mail: follador@svn.com.br

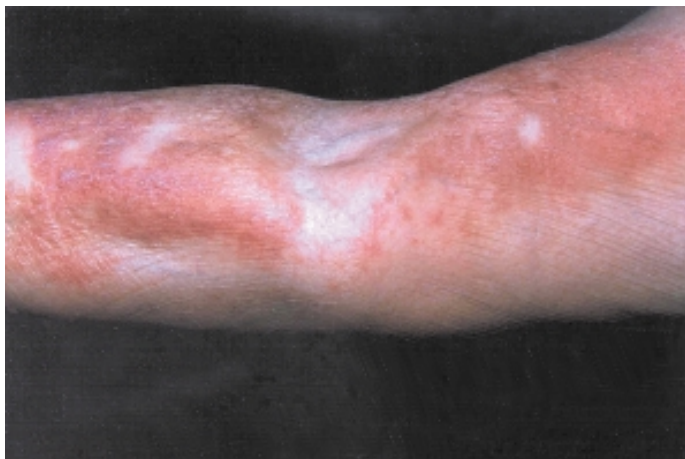

Fig. 1 - Erythematous and infiltrated lesions on the flexural surface of the right arm and forearm without involvement of the fold.

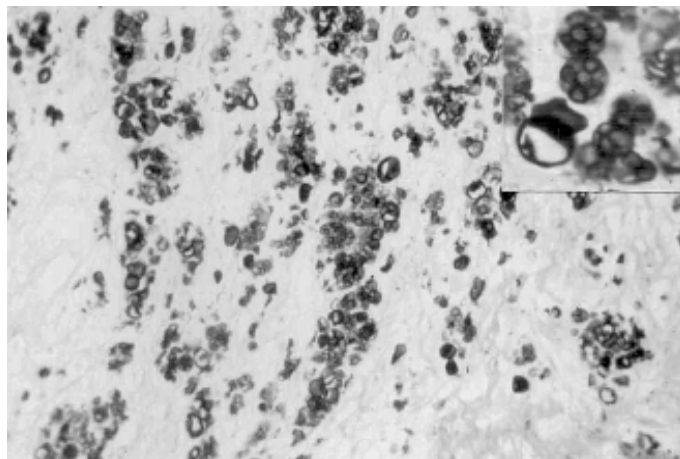


Fig. 4 - Silver staining shows many microorganisms arranged in small clusters. Grocott, x120. On the right corner the typical morula aspect can be seen. Grocott, x640.

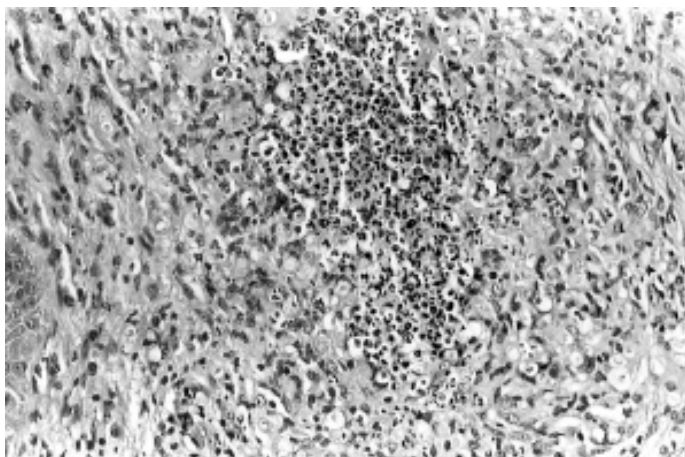


Fig. 2 - The dermis shows an abscess surrounded by epithelioid and giant cells. Many of the giant cells contain rounded structures circled by a halo. HE, x320.

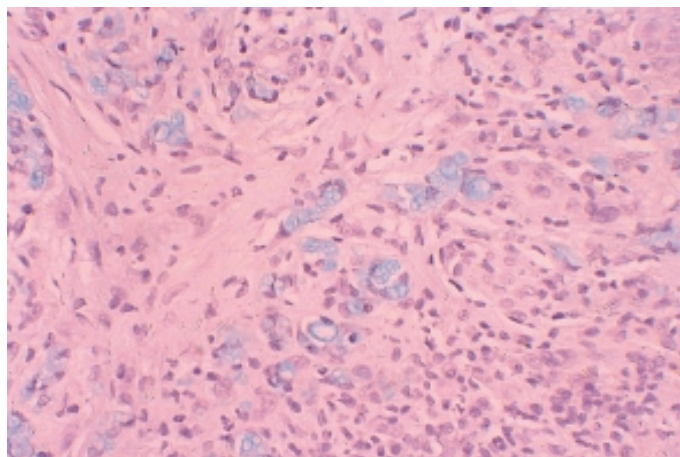


Fig. 5 - Several blue rounded structures can be seen against a pink background, some of them with the classical morula aspect. Alcian blue, x100.

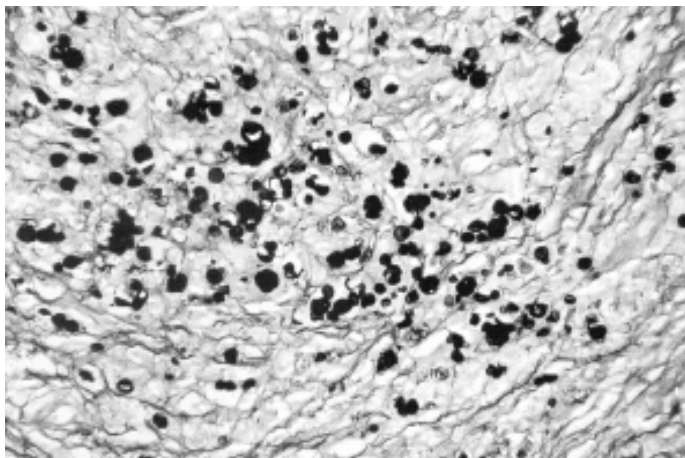


Fig. 3 - Silver staining shows microorganisms like yeasts with buds. Grocott, x200.

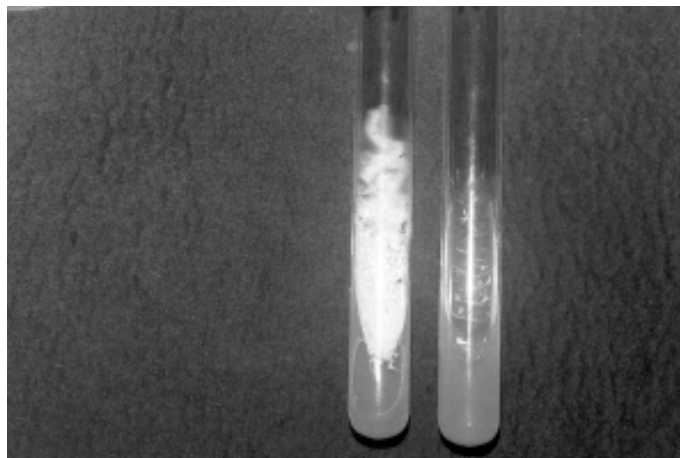


Fig. 6 - See smooth, creamy, white, yeastlike colonies on Sabouraud culture at left. No growth is seen on Sabouraud plus Cyclohexamide culture at right.

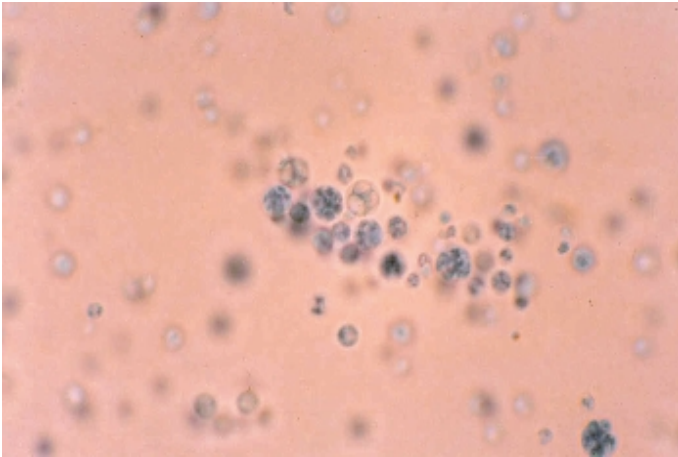


Fig. 7 - See the characteristic endospore-containing sporangium of *Prototheca*. Wet preparation stained with lactophenol cotton blue.

Treatment: The patient was treated successfully with fluconazole daily (150 mg/day) for 30 days and then weekly (150 mg/week) for 60 days. The lesions regressed completely and the patient has been followed up every two months until May/2001 without relapses during 18 months.

DISCUSSION

The case herein described is the second reported in Brazil but the first with isolation of the etiologic agent. The lesions appeared at the trauma site. Probably the vehicle of infection was the water used to clean the lesion.

Protothecosis has been reported to occur associated with conditions that cause immunosuppression^{3,4,13,20,22,26,27,28}, but in our patient no associated condition was detected. Certainly the local dissemination of the lesion was favored by the prolonged use of topical corticosteroid.

The microscopical pattern of protothecosis is similar to that observed in subcutaneous mycotic lesions, with the presence of a granulomatous reaction and abscesses. In protothecosis the microorganisms appear clearly only with special stainings. In the present case the initial silver staining was marked and led to the impression that the causative agent were represented by yeasts with multiple buds mimicking *P. brasiliensis*, but the morula aspect, with symmetrical endospores characteristic of *P. wickerhamii* could be seen with a slightly argentic impregnation. To prevent histological diagnostic problems, periodic-acid-Schiff technique should be also employed, because it clearly demonstrates the morula aspect. The organisms stained with alcian blue, aspect that is not referred in the literature.

Subcutaneous mycotic lesions caused by fungi reproducing with endospores, such as *Coccidioides immitis* and *Rhinosporidium seeberi*, can be easily differentiated from *Prototheca* because these fungi possess much larger sporangia and smaller sporangiospores than *Prototheca*. A histological differential diagnosis should also be made with mycoses presenting yeast-like forms in tissues which may be confused with the sporangia of *Prototheca*, such as the capsule-deficient form of *Cryptococcus neoformans*, *P. brasiliensis* and *Loboa loboii*. In contrast

to *Prototheca*, however, those fungi show budding and do not produce endospores. *P. brasiliensis* produces various buds and the presence of more than three is sufficient for the histological diagnosis. *L. loboii* reproduces by successive budding, forming characteristic chains of cells connected to each other by prominences². However, as previously mentioned a marked argentic impregnation of the *Prototheca* organisms may create diagnostic problems, as occurred initially in the present case. It should also be considered that the sporangia of *Prototheca* can be stained by alcian blue, in order to avoid confusion with the capsular-deficient forms of *Cryptococcus* and the yeast forms of *Blastomyces dermatitides* whose capsules are also stained by the same substance^{2,5}.

The patient was treated successfully with an imidazole derivate (fluconazole). The action of this drug is due to its inhibitory action on the synthesis of ergosterol, a substance that accounts for 4% of the components of the *Prototheca* wall^{3,11}.

Considering the existence of some histological similarities between protothecosis and subcutaneous mycosis, it is possible that pathologists could underdiagnose some cases.

RESUMO

Prototocose cutânea: registro do segundo caso brasileiro

O presente relato descreve um caso de prototocose cutânea causada por *Prototheca wickerhamii* em uma mulher não imunodeprimida do estado da Bahia, Brasil. Este é o segundo caso descrito no Brasil. O exame dermatológico revelou placas eritematosas infiltradas na superfície flexora do braço e antebraço direitos. Os autores enfatizam os aspectos anatomopatológicos que podem levar a erro diagnóstico. A paciente foi tratada com sucesso com fluconazole.

ACKNOWLEDGMENTS

Special thanks to Dr. Márcia de Souza C. Melhem, Mycology Unit, Instituto Adolfo Lutz, São Paulo-SP, Brazil, for confirmation of identification of *P. wickerhamii*.

REFERENCES

1. AGOSTINI, A.A.; LISOT, J.M.C. & GONZALES, D.H.V. - Protothecose do cotovelo: relato de um caso. *Rev. Ass. med. bras*, 29: 178-179, 1983.
2. BITTENCOURT, A.L. & LONDERO, A.T. - Tropical mycosis In: DOERR, W. & SEIFERT, G., ed. *Tropical Pathology*. Heidelberg, Springer-Verlag, 1995. p. 705-798.
3. BOYD, A.S.; LANGLEY, M. & KING Jr, L.E. - Cutaneous manifestations of *Prototheca* infections. *J. Amer. Acad. Derm.*, 32: 758-764, 1995.
4. CAREY, W.P.; KAYKOVA, Y.; BANDRES, J.C.; SIDHU, G.S. & BRAU, N. - Cutaneous protothecosis in a patient with AIDS and a severe functional neutrophil defect: successful therapy with amphotericin B. *Clin. infect. Dis.*, 25: 1265-1266, 1997.
5. CHANDLER, F.W. - Blastomycosis. In: CONNOR, D.H.; CHANDLER, F.W. *et al.*, ed. *Pathology of infectious diseases*. New York, Appleton and Lange, 1997. p. 943-951.
6. COX, G.E.; WILSON, J.D. & BROWN, P. - Protothecosis: a case of disseminated algal infection. *Lancet*, 17: 379-382, 1974.

7. DAVIES, R.R.; SPENCER, H. & WAKELIN, P.O. - A case of human protothecosis. **Trans. roy. Soc. trop. Med. Hyg.**, 58: 448, 1964.
8. ELGART, M. - Unusual subcutaneous infections. **Derm. Clin.**, 14: 105-111, 1996.
9. GOLDSTEIN, G.D.; BATHIA, P. & KALIVAS, J. - Herpetiform protothecosis. **Int. J. Derm.**, 25: 54-55, 1986.
10. KAPICA, L. - First case of human protothecosis in Canada: laboratory aspects. **Mycopathologia** (Den Haag), 73: 43-48, 1981.
11. KIM, S.T.; SUH, Y.S.; CHAE, Y.S. & KIM, Y.J. - Successful treatment with fluconazole of protothecosis developing at the site of an intralesional corticosteroid injection. **Brit. J. Derm.**, 135: 803-806, 1996.
12. KUO, T.T.; HSEUH, S.; WU, J.L. & WANG, A.M. - Cutaneous protothecosis. A clinicopathologic study. **Arch. Path. Lab. Med.**, 111: 737-740, 1987.
13. LAENG, R.H.; EGGER, C.; SCHAFFNER, T.; BORISCH, B. & PEDRINIS, E. - Protothecosis in an HIV-positive patient. **Amer. J. surg. Path.**, 18: 1261-1264, 1994.
14. MATSUDA, T. & MATSUMOTO, T. - Protothecosis: a report of two cases in Japan and a review of the literature. **Europ. J. Epidem.**, 8: 397-406, 1992.
15. MENDEZ, M.C.; LIZAMA, E.S. & LOGEMANN, H. - Human cutaneous protothecosis. **Int. J. Derm.**, 34: 554-555, 1995.
16. MODLY, C.E. & BURNETT, J.W. - Cutaneous algal infections: protothecosis and chlorellosis. **Cutis**, 44: 23-24, 1989.
17. MONOPOLI, A. - Cutaneous protothecosis. **Int. J. Derm.**, 34: 766-767, 1995.
18. PADHYE, A.; BAKER, J. & D'AMATO, R.F. - Rapid identification of *Prototheca* species by API 20C system. **J. clin. Microbiol.**, 10: 579-582, 1979.
19. PHAIR, J.P.; WILLIAMS, J.E.; BASSARIS, H.P.; ZEISS, C.R. & MORLOCK, B.A. - Phagocytosis and algicidal activity of human polymorphonuclear neutrophils against *Prototheca wickerhamii*. **J. infect. Dis.**, 144: 72-77, 1981.
20. POLK, P. & SANDERS, D.Y. - Cutaneous protothecosis in association with the acquired immunodeficiency syndrome. **Sth. med. J. (Bgham, Ala.)**, 90: 831-832, 1997.
21. SIRIKULCHAYANONTA, V.; VISUTHIKOSOL, V.; TANPHAICHITRA, D. & PRAJAKTHAM, R. - Protothecosis following hand injury. A case report. **J. Hand Surg.**, 14: 88-90, 1989.
22. TANG, W.Y.M.; LO, K.K.; LAM, W.Y. *et al.* - Cutaneous protothecosis: report of a case in Hong Kong. **Brit. J. Derm.**, 133: 479-482, 1995.
23. TEJADA, E. & PARKER, C.M. - Cutaneous erythematous nodular lesion in a crab fisherman. Protothecosis. **Arch. Derm.**, 130: 244-245, 1994.
24. VENEZIO, F.R.; LAVOO, E.; WILLIAMS, J.E. *et al.* - Progressive cutaneous protothecosis. **Amer. J. clin. Path.**, 77: 485-493, 1982.
25. WALSH, S.V.; JOHNSON, R.A. & TAHAN, S.R. - Protothecosis: an unusual cause of chronic subcutaneous and soft tissue infection. **Amer. J. Derm.**, 20: 379-382, 1998.
26. WIRTH, F.A.; PASSALACQUA, J. & KAO, G. - Disseminated cutaneous protothecosis in an immunocompromised host: a case report and literature review. **Cutis**, 63: 185-188, 1999.
27. WOLFE, I.D.; SACKS, H.G.; SAMORODIN, C.S. & ROBINSON, H.M. - Cutaneous protothecosis in a patient receiving immunosuppressive therapy. **Arch. Derm.**, 112: 829-832, 1976.
28. WOOLRICH, A.; KOESTENBLATT, E.; DON, P. & SZANIAWSKI, W. - Cutaneous protothecosis and AIDS. **J. Amer. Acad. Derm.**, 31: 920-924, 1994.

Received: 20 July 2001

Accepted: 12 September 2001