

LIVER MORPHOLOGY WITH EMPHASIS ON BILE DUCTS CHANGES AND SURVIVAL ANALYSIS IN MICE SUBMITTED TO MULTIPLE *Schistosoma mansoni* INFECTIONS AND CHEMOTHERAPY

L. C. da SILVA (1), M. Regina VIANNA (2, 3), C. P. ABRANTES (1), D. M. C. LIMA (1), A. L. FALAVIGNA (1), R. H. ANTONELLI-CARDOSO (1), S. D. DEPERON GALLUCCI (1) & T. de BRITO (1, 2, 3)

SUMMARY

In an attempt to be as close as possible to the infected and treated patients of the endemic areas of schistosomiasis (*S. mansoni*) and in order to achieve a long period of follow-up, mice were repeatedly infected with a low number of cercariae.

Survival data and histological variables such as schistosomal granuloma, portal changes, hepatocellular necrosis, hepatocellular regeneration, schistosomotic pigment, periductal fibrosis and chiefly bile ducts changes were analysed in the infected treated and non treated mice.

Oxamniquine chemotherapy in repeatedly infected mice prolonged survival significantly when compared to non-treated animals (chi-square 9.24, $p = 0.0024$), thus confirming previous results with a similar experimental model but with a shorter term follow-up. Furthermore, mortality decreased rapidly after treatment suggesting an abrupt reduction in the severity of hepatic lesions.

A morphological and immunohistochemical study of the liver was carried out. Portal fibrosis, with a pattern resembling human Symmers fibrosis was present at a late phase in the infected animals. Bile duct lesions were quite close to those described in human Mansonian schistosomiasis. Schistosomal antigen was observed in one isolated altered bile duct cell. The pathogenesis of the bile duct changes and its relation to the parasite infection and/or their antigens are discussed.

KEY WORDS: Experimental mansonian schistosomiasis; Oxamniquine therapy; Bile duct changes; Survival analysis.

INTRODUCTION

In a previous study, DA SILVA et al (1985) showed that chemotherapy in repeatedly *S. mansoni* infected mice prolonged survival significantly when compared to non-treated animals. However, a long-term follow-up study of liver le-

sions was not possible, due to the limited survival time of the non-treated animals.

In an attempt to be as close as possible to the infected and treated patients of the endemic

(1) Institute of Tropical Medicine of S. Paulo. São Paulo, SP, Brazil (LIM-47).

(2) Department of Pathology, S. Paulo Medical School, University of S. Paulo.

(3) "Instituto Adolfo Lutz", S. Paulo Health Service, S. Paulo, S. Paulo, SP, Brazil.

Address for correspondence: Thales F. de Brito, M. D. Faculdade de Medicina da Universidade de São Paulo, Departamento de Patologia. Av. Dr. Arnaldo, 455. CEP 01246 São Paulo, SP, Brasil.

areas and in order to achieve a longer period of follow-up, mice were infected with a lower number of cercariae and experimental exposures were less frequent when compared to the previous experimental model. (DA SILVA et al, 1985). Liver morphology in experimental mansonian schistosomiasis was described by GÖNNERT (1955), and in this study altered bile ducts were noted for the first time in mice.

Recently, VIANNA et al (1989) described bile duct lesions in human mansonian schistosomiasis. In this experimental model, a more detailed morphological study of the hepatic changes with emphasis on the bile duct pathology was carried out.

MATERIAL AND METHODS

Experimental infection of mice — A total of 200 outbred albino female Swiss mice, were distributed in four groups:

Group I: 80 infected, non-treated mice.

Group II: 80 infected, and treated mice.

Group III: 20 non-infected, and treated mice.

Group IV: 20 non-infected, non-treated mice.

Mice from groups I and II were infected by tail-immersion with 10-15 cercariae each. Experimental exposures were performed biweekly, except during the period of high mortality (15-27 weeks), when only one exposure was done. Mice from the four groups were identified and randomly distributed in the same cages.

Chemotherapy — Oxamniquine in a single dose of 100 mg/kg of body weight was given through a gastric tube to mice from groups II and III. The other animals received a similar volume of saline solution. Chemotherapy was performed at the 15th week of infection. Therefore, each mouse was exposed to a total of 70 to 105 cercariae during the pre-treatment period and to 70 to 105 cercariae thereafter. Stool examinations were performed before and 8 and 21 weeks after treatment. No worm counting was performed in this experiment.

Parasitological studies — Pre-treatment: at the 12th week, recently collected stools from 24 mice of the group I and 26 mice of the group II were examined.

Post-treatment: Parasitological examination was performed 8 and 21 weeks after chemotherapy in all surviving mice from both groups. At the 21th week (36 weeks from the first infection), all mice had been submitted to four reinfections after either chemotherapy or to placebo.

Morphological studies — Autopsies were performed at the 15th week (before treatment) in 5 mice from groups I and II, at the 42th week (27 weeks after chemotherapy) in 4 mice from groups I, III and IV and in 8 mice from group II.

Fragments of the liver were fixed in buffered 10% formalin and routinely embedded in paraffin. Sections about 4 μ thick were cut and processed for conventional stainings which included hematoxylin-eosin, Masson's trichrome and Gomori's reticulin stain. The combined alcian blue (AB) (pH 2.5) and periodic acid-Schiff (PAS) reagent with diastase digestion method to distinguish blue stained acidic from red-stained neutral mucopolysaccharides (MPS) was also done in all cases to study the bile ducts changes. The following histological variables were analysed in each case and noted either as present or absent:

1. Schistosomal granuloma ("early" or "mature" granulomata around viable or non viable eggs and dead worms and healed granulomata).
2. Portal changes (non specific inflammation with or without spill over of the infiltrate on the periportal hepatic cells, piece meal necrosis, acute and/or chronic phlebitis and portal fibrosis).
3. Bile ducts changes (bile duct hyperplasia, acidophilic cell change and intestinal metaplasia, as judged by the AB-PAS stain, with or without new-glands formation).
4. Hepatocellular necrosis (manifested either by groups of hepatic cells undergoing ischemic necrosis or by necrosis of isolated hepatic cells throughout the liver lobe).
5. Evidence of hepatocellular regeneration.
6. Schistosomotic pigment.
7. Periductal fibrosis.

Immunohistochemical studies — The immunoperoxidase procedure was done as follows:

rabbit anti-serum was raised against *S. mansoni* worms. Goat anti-rabbit IgG from Diagnostic Reagent, USA (linking antibody) and peroxidase-antiperoxidase complex (PAP) from Dako Corporation, USA, were used in 1/50 and 1/2.000 dilutions respectively in the PAP method. Staining was performed according to the method of STERNBERGER et al (1970). The 1/500 dilution of rabbit IgG against *S. mansoni* was incubated overnight and the linking antibody during 30 minutes.

The substrates used were 6% hydrogen peroxidase (0.6 ml), 3,3' diaminobenzidine (Sigma Corp., USA) diluted in 100 ml of PBS, pH = 7.4. Sections were slightly counterstained with Harris hematoxylin. Positive stain was not observed in normal mice liver and was abolished when PBS or non-immune serum was used as the first layer.

Statistical analysis — The methods of estimating the four survival functions for censored data was the product-limit developed by KAPLAN & MEIER (1958). PETO and PETO's (1972) logrank test was used to compare survival distribution.

Fisher exact test was applied on morphological data to compare proportional histologi-

cal variables between animals autopsied before treatment and animals treated and infected up to the 42th week. Due to the small number of autopsied animals in the non-treated group (4 mice) statistical analysis to compare treated and non-treated mice at a late phase of repeated infections (42th week) was not possible.

RESULTS

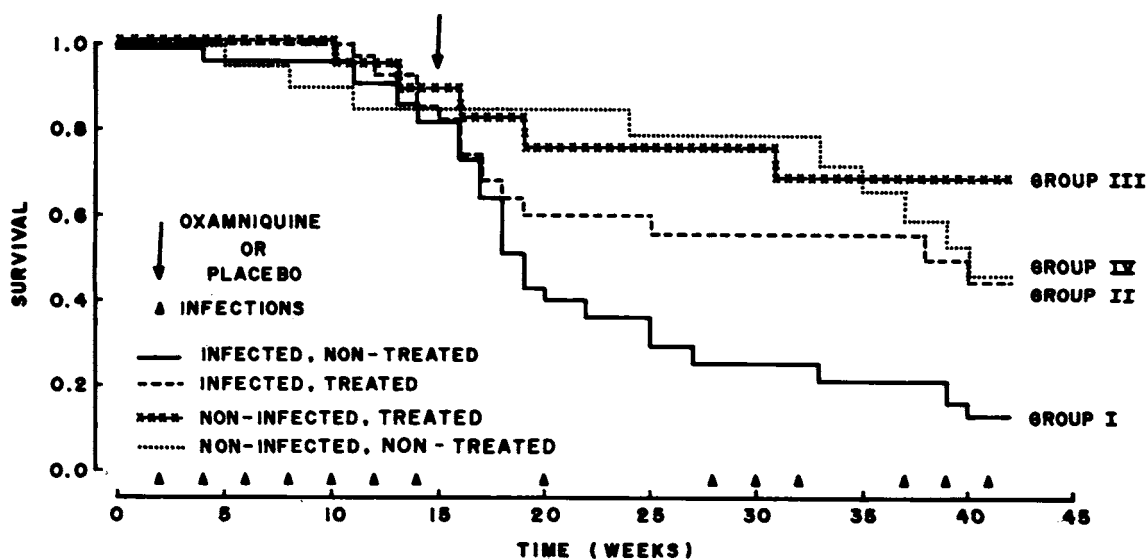
Parasitological and survival data — Stool examinations performed at the 12th week showed a positivity of about 70%. Oxamniquine was given at the 15th week because of the high mortality at this period.

Eight weeks later (23th week from the first infection), parasitological positivity was 100% in group I and 27% in group II ($p = 0.0001$). At the 36th week (21 weeks after treatment), positivity was 100% in group I and despite four infections after chemotherapy, 68% in group II ($p = 0.066$).

The statistical analysis showed a significant difference of the survival data among the four experimental groups (chi-square = 20.13, $p = 0.0002$) (graphic 1).

GRAPHIC I

Comparative survival between non treated (group I) and treated (group II) mice submitted to repeated infections with *S. mansoni* cercariae. Groups III and IV are control groups (see text).



Comparison between infected treated and non-treated mice (groups I and II) was statistically significant (chi-square 9.24, $p = 0.0024$). Noteworthy that the statistically significant differences between groups I and II were observed from the 4th week after treatment on (chi-square = 4.183, $p = 0.0408$). On the other hand, comparison between non-infected treated and non-infected non-treated mice (groups III and IV) was not statistically significant.

Liver histopathology — A spectrum of injuries to the intrahepatic bile ducts was observed, comprising either a hyperplastic epithelial lining made up either of hypertrophic cells with vacuolized or acidophilic (oncocytic) glassy cytoplasm and irregular nuclei or by cells with nuclei disposed in variable height. Crystalloid elongated bodies were frequently present in the ductal lumen.

When the bile ducts were analysed through the AB/PAS stain the following patterns were detected:

a) A purple rim made up of an admixture of acidic and neutral MPS was observed over

the luminal border of the ductal epithelium (Fig. 1). Similar but less intense MPS luminal border deposits were observed in the bile duct epithelium of the control groups liver.

b) Marked thickening of the MPS purple rim over the luminal border associated with new gland formation due to the invagination of the ductal epithelium (Fig. 2). Epithelial hyperplasia was present.

c) Morphological pattern as described in b, associated to the presence of heavy deposits of either acidic or neutral MPS making up a large cytoplasmatic vacuole that give to the cell the globet cell appearance (intestinal metaplasia) (Fig. 3).

Early granuloma was characterized by large masses of macrophages and epithelioid cells surrounding a central core of granulocytes and usually viable eggs. The limiting border of the granuloma was indistinct with inflammatory cells extending into the liver parenchyma and occasionally involving structures of the portal tract such as bile ducts and small vessels. Matu-

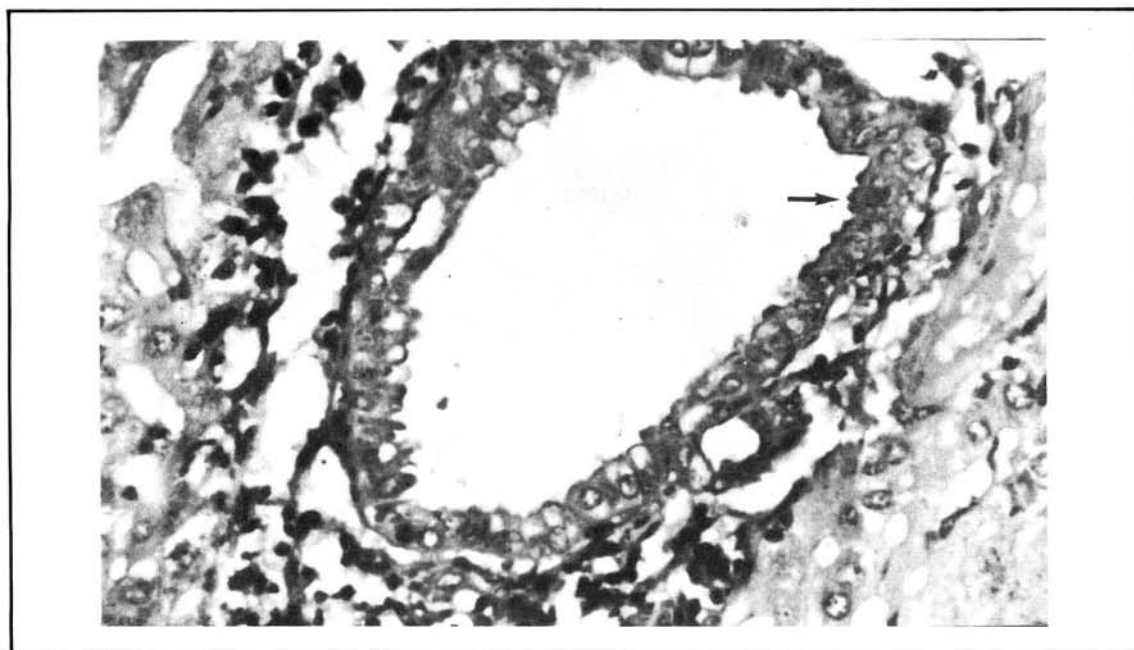


Fig. 1 — Bile duct showing focal MPS purple rim over the luminal border of the ductal epithelium (arrow). Epithelial cells exhibited cytoplasmatic vacuoles. AB/PAS and haematoxylin stain, magnification x 500.

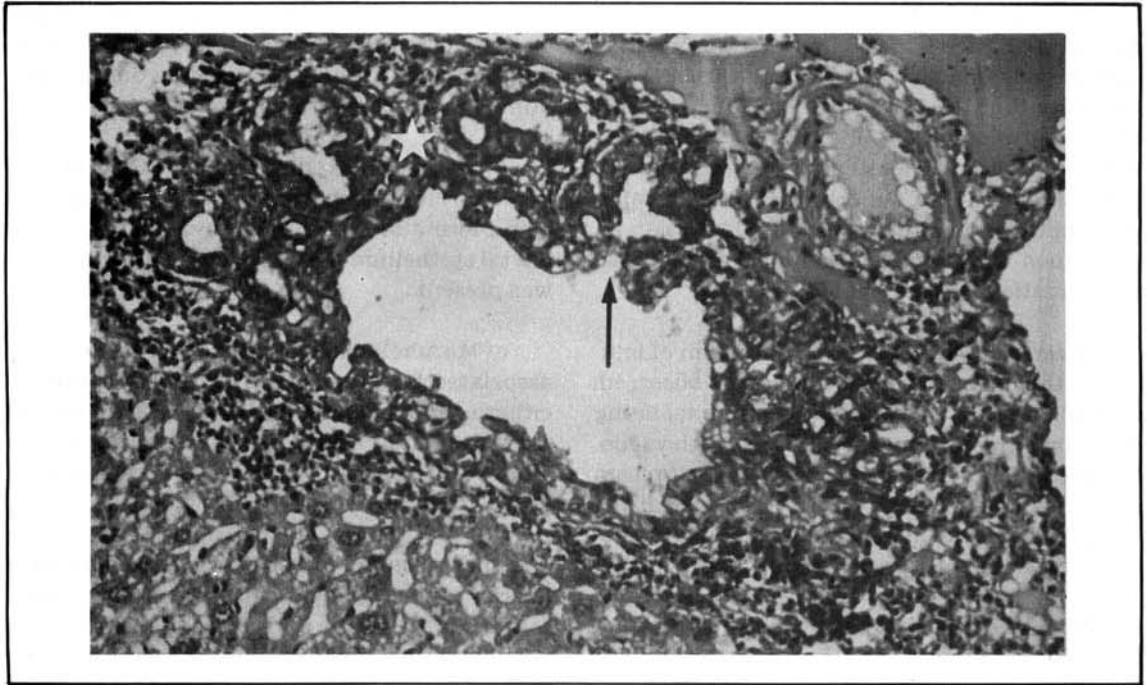


Fig. 2 — MPS purple rim over the luminal ductal epithelium associated with new glands formation (asterisks) due to epithelial invagination (arrow). Epithelial cells show cytoplasmic vacuoles. Chronic inflammatory infiltrate is seen around the duct. AB/PAS and haematoxylin stain, magnification x 150.

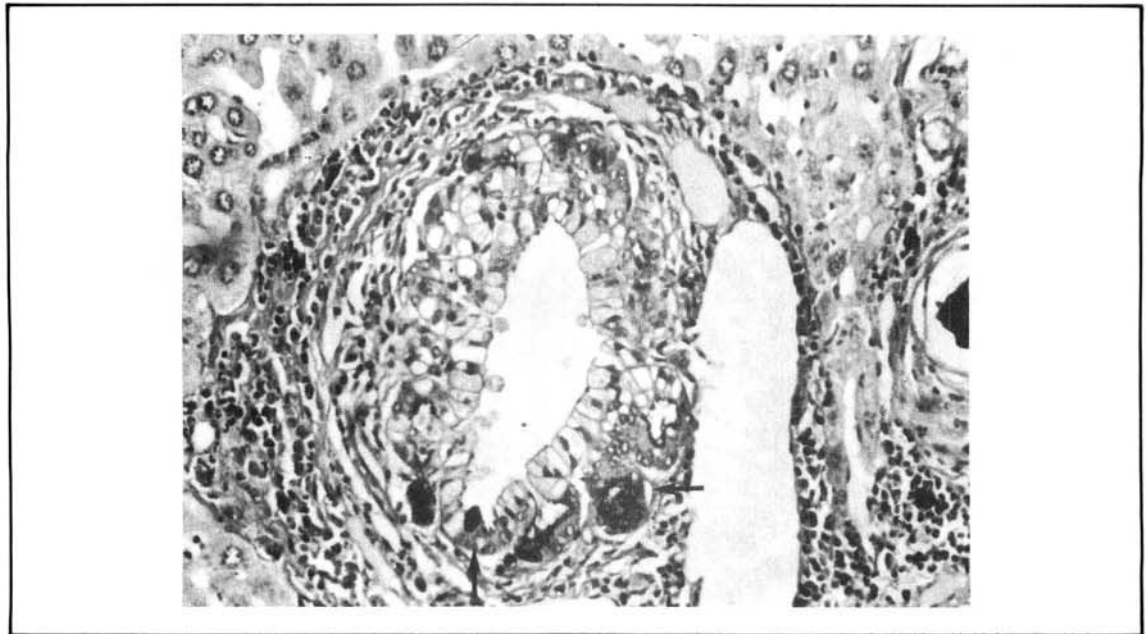


Fig. 3 — Bile duct exhibiting hyperplasia of the epithelial lining. Epithelial cells show either vacuolated or glassy cytoplasm. New glands formation with intestinal metaplasia are also seen (arrow). The bile duct is encircled by slight fibrosis and mononuclear inflammatory infiltrate. AB/PAS and haematoxylin stain, magnification x 150.

re granulomata was represented by a central core of few monocytes among typical epithelioid and giant cells around viable and non viable *S. mansoni* eggs. The periphery was well delimited by an external ring of fibroblasts intermingled with granulocytes. A halo made up of lymphocytes and plasma cells was seen at periphery both of the early and mature granulomata. Healed granulomata, defined as diminished in size round structures made up of hyalin connective tissue, were also seen.

Statistical analysis of the variables showed that the morphological pattern differed when the group of animals dying after few exposures to cercariae were compared with the ones at a late phase of the repeated infection. In the former, early granulomata, with viable eggs predominate, piece meal necrosis was present ($p = 0.0090$) (Fig. 4) and portal veins exhibited edematous intimal thickening, occasionally with endothelial damage and recent thrombosis with ova present. There were no statistical differences regarding portal radicles changes in animals dying after few exposures to cercariae as compared to

mice at the late phase of the infection. Parenchymal ischemic necrosis, was frequently detected ($p < 0.0015$) in the group of animals dying after few exposures to cercariae.

In the group of animals dying at a late phase of the infection mature and healed granulomata usually around non viable or calcified eggs predominated. Noteworthy the statistically significant ($p = 0.0230$) predominance of the portal fibrosis in this latter group, with the emission of thin fibrotic septa to the hepatic parenchyma. In three non treated and one treated mice marked fibrosis with collagen oriented in parallel fibers was observed. (Fig. 5). The overall pattern resembled Symmers fibrosis of man and included the presence of dilated small vessels and few larger branches of the portal vein with marked intimal fibrosis and fragmented muscular layer. Organized thrombosis was occasionally detected in branches of the portal vein.

The immunohistochemical study was essentially as previously described (DA SILVA et al, 1985; ABDUL-ALL & ATTALLAH, 1987). Anti-

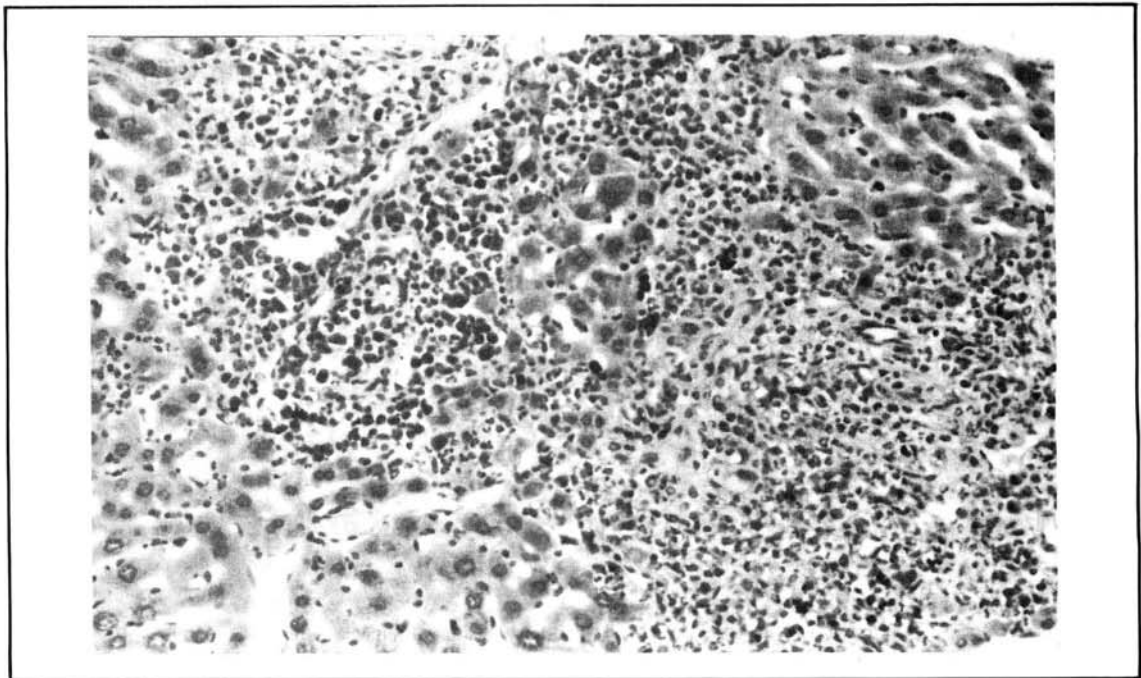


Fig. 4 — Marked portal mononuclear inflammatory infiltrate and piece-meal necrosis in a mouse infected with *S. mansoni* 15 weeks previously. HE, magnification x 150.

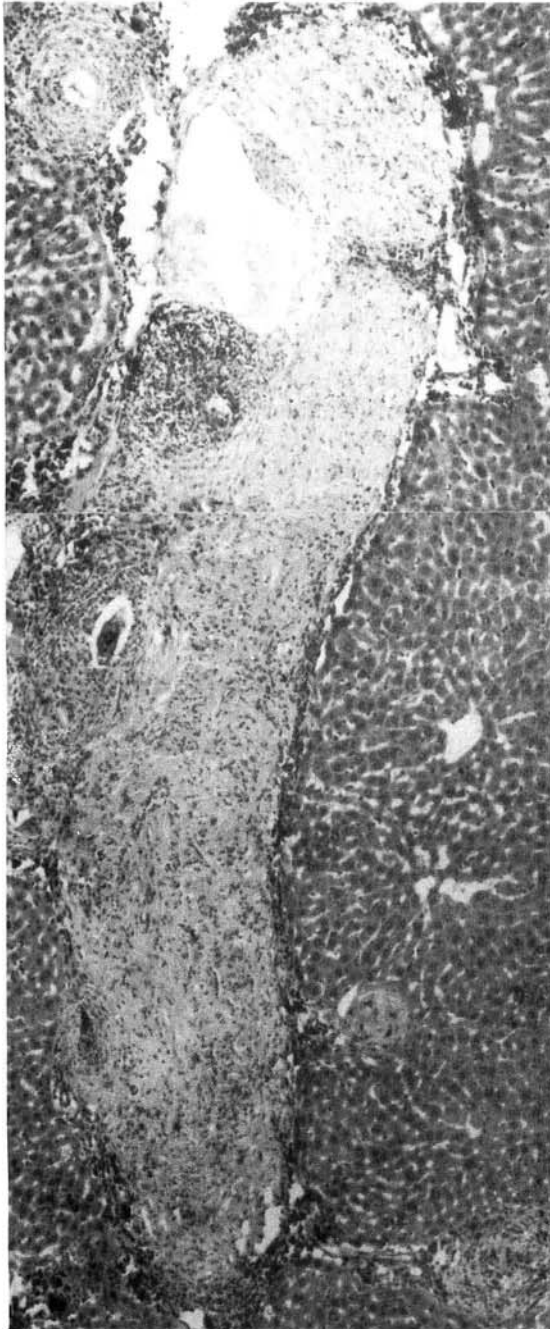

Fig. 5 — Mouse infected with *S. mansoni* 42 weeks previously, non-treated. Marked fibrosis which reminds pipe-stem fibrosis of man, with collagen changing its orientation from concentric whorls to parallel fibers. Granulomatous inflammation around schistosome eggs at periphery. HE, magnification x 75.

gen immunoperoxidase reactive deposits were observed in the miracidia and in few monocytes and granulocytes close to the egg at the central core of the early granulomata. Seldomly antigen was detected in isolated monocytes in the granuloma. Epithelioid cells were antigen immunoperoxidase non-reactive. In the mature granulomata antigen deposits were usually restricted to the miracidia and healed granulomata were non reactive.

Dead desintegrated worms were antigen immunoperoxidase reactive and the reaction appeared as granules scattered throughout the body of the worm. Rarely antigen deposits were observed in sinusoidal phagocytic cells.

In one animal at the late phase of the repeated infection an enlarged cell of the altered bile duct exhibited cytoplasmatic granules of *S. mansoni* antigen (Fig. 6).

DISCUSSION

Chemotherapy in repeatedly infected mice (group II) prolongs survival significantly when compared to non-treated animals (group I). Such improvement in survival was also observed when a similar model but with a shorter follow-up was used (DA SILVA et al, 1985). Similar findings were reported when different drugs in mice submitted to single infection were employed (WARREN, 1962; ANDREWS et al, 1980). Inte-

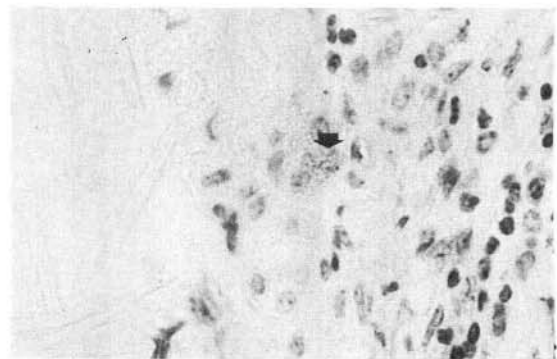


Fig. 6 — Isolated cell of the ductal epithelium with *S. mansoni* antigen peroxidase reactive granules in the cytoplasm (arrow). Mononuclear inflammatory infiltrate is seen around the duct and crystalloid elongated bodies are observed inside the duct lumen. Immunoperoxidase reaction and hematoxylin stain, magnification x 900.

resting enough, the mortality of mice decreased rapidly after treatment, suggesting an abrupt reduction in the severity of hepatic lesions after chemotherapy (ANDRADE & GRIMAUD, 1986).

Portal fibrosis, with a pattern resembling Symmers fibrosis of men, similarly as previously reported by WARREN (1966), was present at the late phase of the repeated experimental infection with *S. mansoni* in mice. Chronic phlebitis with altered muscular layer results from acute phlebitis caused by the eggs deposition and probably leads to portal hypertension. Indirect evidence of the portal hypertension was manifested by the dilated vessels detected in the portal tracts.

Piece meal necrosis was observed more frequently at the early phase of the experimental infection and probably is related to the ongoing portal inflammation. Whether such lesion has some importance in the pathogenesis of experimental schistosomal portal fibrosis remains to be established.

Bile ducts lesions were previously described by GÖNNERT (1955) and DA SILVA et al (1985). DA SILVA et al (1985) observed the bile ducts lesions in the experimental infection from the 9th week on. Since in the present study the animals were autopsied from 15th week on altered bile ducts were observed in all animals. However, new findings such as increased MPS deposits on the luminal border of the damaged ducts, intestinal metaplasia and new glands formation were added to the previous descriptions. Except for the oncocytic cell change which is not observed in humans, the findings in the altered bile ducts in the experimental infection were quite close to those recently described by VIANNA et al (1989) in the *S. mansoni* infection in man. The stimulation of epithelial hyperplasia and MPS-production in mansonian schistosomiasis is apparently not a specific one and is close to the findings already reported in the bile ducts of humans and animals infected by *Clonorchis sinensis* (CHOU & GIBSON, 1970; HOU, 1955), *Fasciola hepatica* (ACOSTA-FERREIRA, 1979) and *Opisthorchis viverrini* (THAMAVIT et al, 1987). Recently, KURASHINA et al (1988) reported that intrahepatic duct hyperplasia, which

is significantly frequent in bile ducts undergoing inflammatory changes, is a precursor of cholangiocellular carcinoma in man. Moreover, intestinal metaplasia of the bile duct epithelium is regarded by KOZUKA et al (1984) as a condition liable to neoplastic transformation. The high incidence of cholangiocarcinomas, particularly of the mucin-producing type in men and animals infected with *Clonorchis sinensis* (HOU, 1956-1964) concurs with this point of view. Such association was not report so far in human and experimental schistosomiasis mansoni. However, it is noteworthy that the parasites associated with neoplastic transformation of the bile duct epithelium live in the biliary tree and the constant movement of the worms and/or metabolic products of the living or degradation products of the dead parasites probably result in mechanical and chemical irritation to the epithelia (HOU, 1955). In schistosomiasis mansoni portal inflammation around eggs and/or dead worms probably leads to the dissemination of products of the parasite through the intrahepatic peribiliary vascular plexus with a less intense injury to the bile ducts.

The role played by the antigenic components of the *S. mansoni* egg and/or worm in the morphological changes of the bile ducts is so far merely speculative. Antigen deposits were previously detected in altered bile duct cells in murine experimental schistosomiasis (DA SILVA et al, 1985) and in the present study, this finding could be confirmed. Since the degree of infection was lower, only one isolated altered duct cell was observed to contain antigen granules. However, bile ducts alterations were conspicuous suggesting that probably non antigenic products released by the worm and/or eggs and/or the portal inflammation are playing a more important role in the pathogenesis of the duct damage.

In conclusion, this experimental model showed a significant reduction of the mortality after chemotherapy and proved to be adequate for the morphological study of bile duct damage and fibrosis in mansonian schistosomiasis.

RESUMO

Alterações morfológicas hepáticas, com especial ênfase nas alterações dos ductos biliares

e análise de sobrevivência em camundongos submetidos a infecções múltiplas por *S. mansoni* e a quimioterapia.

Numa tentativa de estar o mais próximo possível a pacientes infectados e tratados nas áreas endêmicas de esquistosomose (*S. mansoni*) e também para obter um período mais longo de seguimento, camundongos foram repetidamente infectados com um número baixo de cercárias.

Dados de sobrevivência e variáveis histológicas tais como granuloma esquistosomótico, alterações portais, necrose hepatocelular, regeneração hepática, pigmento esquistosomótico, fibrose periductal e principalmente, alterações dos ductos biliares foram analisados nos animais infectados tratados e não tratados.

A terapêutica por oxamniquina nos animais repetidamente infectados prolonga a sobrevivência de maneira significativa (Chi-quadrado 9,24, $p = 0,0024$), portanto confirmando resultados anteriores com um modelo semelhante mas com um período mais curto de seguimento. Ainda, a mortalidade decresce rapidamente depois do tratamento, sugerindo uma abrupta redução na gravidade das lesões hepáticas.

O fígado foi ainda estudado sob o ponto de vista morfológico e imunohistoquímico. Fibrose portal, com um quadro que lembra a fibrose humana do tipo Symmers está presente na fase tardia da infecção. As alterações de ductos biliares são muito próximas daquelas descritas na esquistosomose mansônica humana. Antígeno esquistosomótico foi observado em uma célula isolada do revestimento alterado de ductos biliares. A patogênese das alterações ductais e sua possível relação com a infecção parasitária e/ou seus antígenos foi discutida.

ACKNOWLEDGEMENTS

The authors would like to thank Edna A. Leick and Dr. R. Telma M. Santos for technical help and Maria Elí P. de Castro for secretarial assistance in the preparation of this manuscript.

REFERENCES

1. ABDUL-ALL, G. & ATTALLAH, A. M. — Immunopathology of experimental *Schistosoma mansoni* infection: immunohistochemical localization of parasite antigens in the host tissue. *Int. Arch. Allergy*, 82: 89-94, 1987.
2. ACOSTA-FERREIRA, W.; VERCELLI-RELLA, J. & FALCONI, L. M. — *Fasciola hepatica* human infection. Histopathological study of sixteen cases. *Virchows Arch. A Path. Anat. Histol.*, 383: 319-327, 1979.
3. ANDRADE, Z. A. & GRIMAUD, J. A. — Evolution of the schistosomal hepatic lesions in mice after curative chemotherapy. *Amer. J. Pathol.*, 124: 59-65, 1986.
4. ANDREWS, P.; DYCKA, J. & FRANK, G. — Effects of praziquantel on clinical-chemical parameters in healthy and schistosome infected mice. *Ann. trop. Med. Parasit.*, 74: 167-177, 1980.
5. CHOU, S. T. & GIBSON, J. B. — The histochemistry of biliary mucins and the changes caused by infestation with *Clonorchis sinensis*. *J. Pathol.*, 101: 185-197, 1970.
6. DA SILVA, L. C.; ALVES, V. A. F.; ABRANTES, C. P.; LIMA, D. M.; CHRISTO, C. H. & DE BRITO, T. — Effects of chemotherapy on mice submitted to multiple *Schistosoma mansoni* infection. A controlled randomized prospective study. *Tropenmed. Parasit.*, 36: 150-154, 1985.
7. GÖNNERT, R. V. — Schistosomiasis studien IV — Zur Pathologie der Schistosomiasis der Maus. *Z. Tropenmed. Parasit.*, 6: 279-336, 1955.
8. HOU, P. C. — The pathology of *Clonorchis sinensis* infestation of the liver. *J. Path. Bact.*, 70: 53-64, 1955.
9. HOU, P. C. — The relationship between primary carcinoma of the liver and infestation with *Clonorchis sinensis*. *J. Path. Bact.*, 72: 239-246, 1956.
10. HOU, P. C. — Primary carcinoma of bile duct of the liver of the cat (*Felis catus*) infested with *Clonorchis sinensis*. *J. Path. Bact.*, 87: 239-244, 1964.
11. KAPLAN, E. L. & MEIER, P. — Nonparametric estimation from incomplete observations. *J. Amer. Statist. Ass.*, 53: 457-481, 1958.
12. KOZUKA, S.; KURASHINA, M.; TSUBONE, M.; HACHISUKA, K. & YASUI, A. — Significance of intestinal metaplasia for the evolution of cancer in the biliary tract. *Cancer*, 54: 2277-2285, 1984.
13. KURASHINA, M.; KOZUKA, S.; NAKASIMA, N.; HIRABAYASI, N. & MASAFUMI, I. — Relationship of intrahepatic bile duct hyperplasia to cholangiocellular carcinoma. *Cancer*, 61: 2469-2474, 1988.
14. PETO, R. & PETO, J. — Asymptotically efficient rank invariant procedures. *J. roy. Statist. Soc., Series A*, 135: 185-207, 1972.

SILVA, L. C. da; VIANNA, M. R.; ABRANTES, C. P.; LIMA, D. M. C.; FALAVIGNA, A. L.; ANTONELLI-CARDOSO, R. H.; DEPERON GALLUCCI, S. D. & BRITO, T. de — Liver morphology with emphasis on bile ducts changes and survival analysis in mice submitted to multiple *Schistosoma mansoni* infections and chemotherapy. *Rev. Inst. Med. trop. S. Paulo*, 32(5): 328-337, 1990.

15. STERNBERGER, L. A.; HARDY, P. H.; CUCULITIS, J. J. & MEYER, H. G. — The unlabelled antibody-enzyme method of immunohistochemistry. Preparation and properties of soluble antigen-antibody complex (Horseradish peroxidase-antihorseradish peroxidase) and its use in identification of spirochetes. *J. Histochem. Cytochem.*, 18: 315-333, 1970.
16. THAMAVIT, W.; KONGKANUNTIN, R.; TIMAWECH, D. & MOORE, M. A. — Level of *Opisthorchis* infestation and carcinogen dose-dependence of cholangiocarcinoma induction in Syrian golden hamsters. *Virchows Arch. B*, 54: 52-58, 1987.
17. VIANNA, M. R.; GAYOTTO, L. C. C.; SANTOS, R. T. M.; ALVES, V. A. F. & DE BRITO, T. — Intrahepatic bile duct changes in human hepatosplenic schistosomiasis mansoni. *Liver*, 9: 100-109, 1989.
18. WARREN, K. S. — The influence of treatment on the development and course of murine hepato-splenic schistosomiasis mansoni. *Trans. roy. Soc. trop. Med. Hyg.*, 56: 510-519, 1962.
19. WARREN, K. S. — The pathogenesis of "clay-pipe stem cirrhosis" in mice with chronic schistosomiasis mansoni, with a note on the longevity of the schistosomes. *Amer. J. Path.*, 49: 477-485, 1966.

Recebido para publicação em 10/8/1990