

CHRONIC GLOMERULONEPHRITIS ASSOCIATED WITH HEPATOSPLENIC SCHISTOSOMIASIS MANSONI

Eduardo Antonio Gonçalves RAMOS & Zilton A. ANDRADE

SUMMARY

In a series of 36 cases of renal disease associated with hepatosplenic schistosomiasis the following morphologic types of glomerulonephritis were found: mesangio-capillary (33.2%), mesangial proliferative (25.0%), focal glomerular sclerosis (16.7%) and sclerosing glomerulonephritis (8.3%). No significant statistical differences were found when these results were compared with those from 36 cases of glomerulonephritis not associated with hepatosplenic disease. On the other hand, endocapillary glomerulonephritis was found to be predominant in the latter group of cases. These results did not substantiate the assumption that mesangio-capillary glomerulonephritis is specifically related to hepatosplenic schistosomiasis. However, if the types of glomerulonephritis that predominantly involve the mesangium are considered together, they are significantly associated with hepatosplenic schistosomiasis. Mesangial involvement is known to occur in other parasitic diseases and that may be related to a common immunopathogenesis.

KEY-WORDS: Schistosomiasis; Glomerulonephritis; Parasitic nephropathy.

INTRODUCTION

Chronic glomerulonephritis appears in 12 to 15% of the patients with hepatosplenic schistosomiasis¹. It is considered as a good example of an immune-complex renal disease caused by a parasitic infection², since antibodies, complement and schistosomal antigens have been detected in the lesions, both in man^{3,4} and in experimental animals^{3,17,19,23,26}.

Nephrotic syndrome is the principal clinical manifestation, usually with low selectivity or non-selectivity of proteinuria, low blood cholesterol and some degree of hypertension^{1,4}.

Chronic mesangio-capillary glomerulonephritis and focal glomerular sclerosis are considered to be the main histological types of glomerulopathy associated with hepatosplenic schistosomiasis^{5,6,7,8,16,22,25}. These data are derived

from studies where a group of hospitalized patients or series of necropsy cases were considered. It is not known whether there are peculiar types of glomerulonephritis which are associated with hepatosplenic schistosomiasis, since no comparative studies with other groups of glomerulonephritis not associated with schistosomiasis are available.

The present investigation is a histopathological evaluation of the types of glomerulonephritis seen in a group of cases associated with hepatosplenic schistosomiasis as compared with a similar group, from the same geographic area, but without such association.

MATERIAL AND METHODS

From the files of the Department of Pathology, Hospital Prof. Edgard Santos, Federal Uni-

Centro de Pesquisas Gonçalo Moniz — FIOCRUZ-UFBa.
Rua Valdemar Falcão, 121 — Brotas — Salvador, Bahia — Brazil
Supported by Grants N.º 25380.006108/86 and 2541/85 (FINEP, Brazil).

versity of Bahia, necropsy protocols and paraffin blocks from 72 cases of glomerulonephritis, half of them associated with hepatosplenic schistosomiasis, were taken and re-analyzed. In the first 36 cases (Group I) hepatosplenic schistosomiasis was the main disease and care was taken not to include cases presenting any other principal disease or any other systemic process. The diagnosis of hepatosplenic schistosomiasis was confirmed in every case by the finding of portal fibrosis with portal vein destruction and granulomas around *Schistosoma mansoni* eggs (Symmers' pipe-stem fibrosis) with the presence of esophageal varices and splenomegaly. In some cases the spleen had been previously removed.

The other group (Group II) was represented by 36 cases of chronic glomerulonephritis, as diagnosed at necropsy, but without hepatosplenic schistosomiasis and selected to be sex and age-paired with the first group. Some of the patients in this group had mild hepato-intestinal schistosomiasis.

A summary of the main clinical data appears on Table 1 and some necropsy data regarding the weights of the liver and spleen are shown on Table 2.

T A B L E I

General clinical data on 72 cases of chronic glomerulonephritis, 36 of which associated with hepatosplenic *Schistosomiasis mansoni* (Group I) and 36 without such association (Group II)

Clinical Data	Group I	Group II
Age (X ± SD)	36.4 ± 18.5	32.2 ± 16.7
Sex	23 M 13 F	21 M 15 F
Nephrotic syndrome	66.7%	50.0%
Hypertension (min > 90 mm)	41.7%	77.8%
Urea (> 150 mg%)	50.0%	72.2%
Creatinin (> 5 mg%)	33.0%	69.0%

T A B L E II

Weights of the liver, spleen and kidneys in two groups of patients with chronic glomerulonephritis: one with hepatosplenic schistosomiasis (Group I) and the other without (Group II)

Organs	Weights (grams)	
	Group I	Group II
Liver	1.423.0 ± 519.3	1.551.4 ± 580.5
Spleen	567.0 ± 506.3	174.6 ± 104.6
Kidneys		
Rt	125.8 ± 50.3	89.7 ± 45.1
Lf	129.6 ± 52.0	90.0 ± 42.9

New 2 micron thin sections from the paraffin blocks of formalin and/or Bouin fixed renal tissue were stained with hematoxylin and eosin, Schiff's periodic acid (PAS), the Heidenhain's connective tissue stain (AZAM), Masson's trichrome stain and the periodic acid silver methanamine method (PASM). All the slides were coded for the microscopic examination and the glomerular lesions classified according to the criteria of the World Health Organization¹¹. Semi-quantitative analysis of the histopathologic findings was made according to PIRANI et al.²¹.

The scores ascribed to the types of glomerulonephritis found in the two groups were compared by the chi-square test, at a $p < 0.05$ level of significance.

As for the sub-classification of mesangio-capillary glomerulonephritis into types I and II, it was made on the basis of the azocarmin granular deposits found on slides stained with the AZAN method.

RESULTS

Table 3 presents the histological types of glomerulonephritis found in the 72 cases studied and their distribution according to the two groups of cases considered. Mesangio-capillary glomerulonephritis was the most frequent type in the two groups and its subclassification is presented on Table 4. The principal histopathologic features of the main types of glomerulonephritis found are illustrated in Figures 1, 2, 3, and 4.

Statistical analysis failed to demonstrated any significance between the number of cases of mesangio-capillary glomerulonephritis present in Groups I and II. The same was true for the cases of mesangial proliferative glomerulonephritis. The presence of proliferative endo-capillary glomerulonephritis was greater in Group II and that difference was statistically significant. A comparison of the number of cases of mesangio-capillary glomerulonephritis added to the cases of mesangial proliferative glomerulonephritis indicated a greater prevalence of these types of glomerulonephritis in the group of patients with hepatosplenic schistosomiasis, and that was statistically significant. The other types of glomerulopathies, such as, focal glomerular sclerosis, sclerosing

T A B L E III

Distribution of histological types of chronic glomerulonephritis in two groups of cases: one associated with hepatosplenic schistosomiasis (Group I) and the other not (Group II)

Histological types	Group I	Group II	Total
Mesangio-capillary g.N.	12 (33.3%)	07 (19.4%)	19 (26.4%)
Mesangio-proliferative g.N.	09 (25.0%)	05 (13.9%)	14 (19.4%)
Endocapillary-proliferative g.N.	02 (5.6%)	10 (27.8%)	12 (16.7%)
Focal glomerular sclerosis	06 (16.7%)	03 (8.3%)	09 (12.5%)
Sclerosing g.N.	03 (8.3%)	04 (11.1%)	07 (9.7%)
Extra-capillary proliferative g.N.	02 (5.6%)	01 (2.8%)	03 (4.2%)
Focal segmental proliferative g.N.	01 (2.8%)	02 (5.6%)	03 (4.2%)
End-stage kidney disease	01 (2.8%)	04 (11.1%)	05 (6.9%)
Total	36(100.0%)	36(100.0%)	72(100.0%)

T A B L E IV

Sub-classification of cases of chronic mesangio-capillary glomerulonephritis in two groups of subjects; one with concomitant hepatosplenic schistosomiasis (Group I) and the other without (Group II)

Types of Mesangio-capillary g.N.	Group I	Group II	Total
Type I	10	05	15
Type II	01	01	02
Unclassified	01	01	02
Total	12	07	19

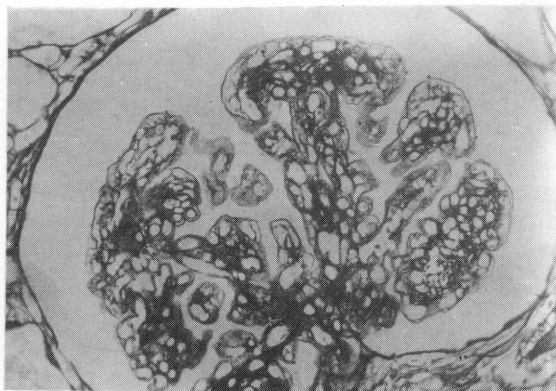

Fig. 1 — Mesangio-capillary glomerulonephritis. There is a peculiar lobular disposition of the capillary loops and a prominent duplication of the capillary basement membrane. PAMS stain, X 400.

glomerulonephritis, extra-capillary proliferative glomerulonephritis, focal segmental proliferative glomerulonephritis and end-stage renal disease could not be submitted to statistical analysis due to the small number of cases present. However there were twice as much cases of focal glomerular sclerosis in Group I than in Group II (see Table 3).

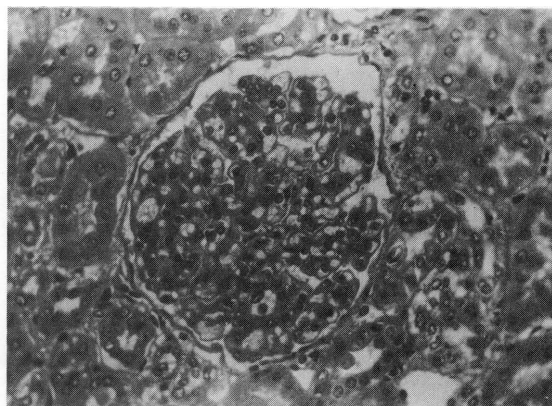


Fig. 2 — Mesangial proliferative glomerulonephritis, generalized, diffuse. Increased mesangial cellularity and diffuse expansion of the mesangial matrix. Hematoxylin and eosin, X 400.

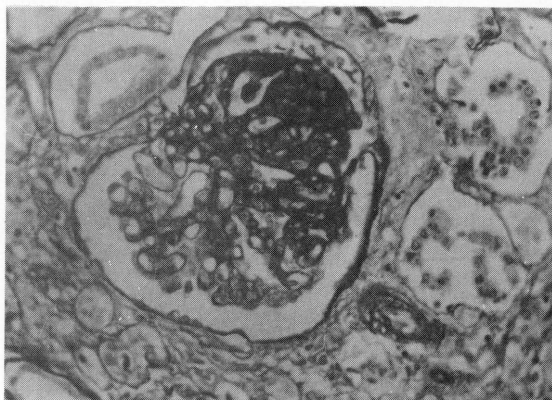


Fig. 3 — Focal glomerular sclerosis. Focal fibrous thickening and collapse of the capillary loops and mesangium with adherence to the Bowman capsule, making a sharp contrast with the other nearly normal half of the glomerulus. PAS method, X 400.

DISCUSSION

There are several morphologic types of glomerulonephritis with clinical and prognostic

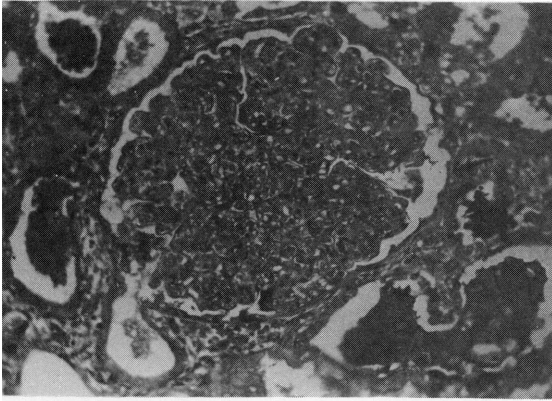


Fig. 4 — Endocapillary proliferative glomerulonephritis, generalized, diffuse. The lumen of the capillary loops are filled by the proliferation and swelling of the endothelial cells. Hematoxylin and eosin, X 400.

significance, but without a clear-cut etiological connotation. However, it is possible that one single etiology may determine a predominant histologic type. This could account for the existence of different types of glomerulonephritis in different geographic areas of the world. A predominance of chronic mesangial proliferative glomerulonephritis has been reported in the cases of renal disease associated with hepatosplenic schistosomiasis, with focal glomerular sclerosis coming second 5,6,16,22.

In a series of 15 cases of hepatosplenic schistosomiasis and chronic renal disease, QUEIROZ et al.²² found that 73% of them belonged to the mesangio-capillary type and 20% to focal glomerular sclerosis.

Reviewing 133 renal biopsies from hepatosplenic patients, MARTINELLI et al.¹⁶ observed the presence of mesangio-capillary (membranous proliferative) glomerulonephritis in 48% of the cases and focal glomerular sclerosis in 23.6%. It has been claimed that the incidence of mesangio-capillary glomerulonephritis in Bahia, Brazil²², is quite different from that seen in the United States and Europe^{9,15,24} which could reflect some regional etiologic differences.

The present study reveals that the types of glomerulonephritis occurring in patients with hepatosplenic schistosomiasis are the same that appear in other patients without such condition, at least in the Bahia area. However, when one considers the types of glomerulone-

phritis which predominantly involve the renal mesangium, such as the mesangio-capillary and the mesangial proliferative types, then it can be seen that these types together are much more frequent in hepatosplenic patients than in the control group. This consideration may be of importance, since the mesangial involvement may depend on the sizes of the immuno-complexes involved in the pathogenesis of a particular histologic type of glomerulonephritis¹⁰.

The antigen most probably involved in the renal lesions of schistosomiasis is a high molecular weight polysaccharide originated from the intestinal lining of adult worms¹⁸ and now designated as "gut associated schistosomal proteoglycan (GASP)". This antigen usually reacts in man with IgM antibodies, probably forming large immuno-complexes².

The apparently high prevalence of focal glomerular sclerosis in cases of hepatosplenic schistosomiasis is more difficult to explain, since little is known about the pathogenesis of this type of renal lesion.

Finally, it can be said that, taken isolately, the several morphologic types of glomerulonephritis seen in association with hepatosplenic schistosomiasis do not statistically differ from those observed in other patients without hepatosplenic disease. However, there is a predominant type of mesangial involvement in the most frequent forms of glomerulonephritis associated with hepatosplenic schistosomiasis, and this may reflect a pathogenetic influence, probably related to the size of the immuno-complexes involved. Usually the mesangium is particularly involved in the renal lesions associated with other parasitic diseases, such as malaria¹² and visceral leishmaniasis²⁰, where large immuno-complexes are likely to play a role.

RESUMO

Tipos de glomerulonefrite crônica associados com a esquistossomose mansônica hepato-esplênica

Numa série de 36 casos de doença renal em portadores de esquistossomose hepato-esplênica, os tipos histológicos de glomerulonefrite encontrados foram os seguintes: mesângio-ca-

pilar (33,2%), proliferativa mesangial (25,0%), esclerose glomerular focal (16,7%) e glomerulonefrite esclerosante (8,3%).

Quando estes tipos e números foram comparados com aqueles obtidos de um grupo controle de 36 casos de glomerulonefrite sem associação com a esquistossomose hepato-esplênica, não foram verificadas diferenças estatisticamente significantes, a não ser em relação à glomerulonefrite proliferativa endocapilar que apareceu muito mais frequentemente no grupo controle.

Assim sendo, a idéia de que a glomerulonefrite mesângio-capilar está especificamente associada com a esquistossomose não se consubstanciou. Todavia, quando se consideram juntos os dois grupos de glomerulonefrite com envolvimento predominantemente mesangial (mesângio-capilar e proliferativa mesangial), há uma nítida predominância dos mesmos nos casos associados com a esquistossomose hepato-esplênica. Este dado pode estar ligado à existência de imuno-complexos de grande peso molecular, os quais tendem a se depositar no mesângio, como parece ser o caso com as glomerulonefrites associadas com infecções parasitárias em geral.

REFERENCES

1. ANDRADE, Z. A. & ROCHA, H. — Schistosomal glomerulopathy. *Kidney Int.*, 16: 23-29, 1979.
2. ANDRADE, Z. A. & SADIGURSKY, M. — Immuno-fluorescence studies of schistosomal structures which share determinants with circulating schistosomal antigens. *Trans. roy. Soc. trop. Med. Hyg.*, 72: 316-318, 1978.
3. ANDRADE, Z. A. & SUSIN, M. — Renal changes in mice infected with *Schistosoma mansoni*. *Amer. J. trop. Med. Hyg.*, 23: 400-403, 1974.
4. ANDRADE, Z. A. & VAN MARCK, E. — Schistosomal glomerular disease. (A review). *Mem. Inst. Osw. Cruz*, 79: 499-506, 1984.
5. ANDRADE, Z. A.; ANDRADE, S. G. & SADIGURSKY, M. — Renal changes in patients with hepatosplenic schistosomiasis. *Amer. J. trop. Med. Hyg.*, 20: 77-83, 1971.
6. BRITO, E. — Patologia renal na esquistossomose mansônica hepatoesplênica. Um estudo em material de biópsias renais. Salvador, 1973. (Tese — Universidade Federal da Bahia).
7. BRITO, T.; BONI, D.; LOPES, J. D. & SILVA, L. C. — Kidney biopsy in human schistosomiasis: an ultrastructural study. (Preliminary report). *Rev. Inst. Med. trop. S. Paulo*, 11: 62-64, 1969.
8. BRITO, T.; BONI, D.; LOPES, J. D.; PENA, D. O. & SILVA, L. C. — Advanced kidney disease in patients with hepatosplenic Manson's schistosomiasis. *Rev. Inst. Med. trop. S. Paulo*, 12: 225-235, 1970.
9. CAMERON, J. S. — Nephrotic syndrome. *Brit. med. J.*, 4: 350-353, 1970.
10. CAMERON, J. S. — Glomerulonephritis: current problems and understanding. *J. Lab. clin. Med.*, 98: 755-787, 1982.
11. CHURG, J. & SOBIN, L. H. — Renal diseases: classification and atlas of glomerular diseases. Tokyo, Igaku-Shoin, 1982.
12. DUNNILL, M. S. — Pathological basis of renal diseases. London, W.B. Saunders, 1976.
13. FALCÃO, H. A. & GOULD, D. B. — Immune complex nephropathy in schistosomiasis. *Ann. Intern. Med.*, 83: 148-154, 1975.
14. HOSHINO-SHIMIZU, S.; BRITO, T.; KANAMURA, H. Y.; CANTO, A. L.; SILVA, A. O.; PENNA, D. O. & SILVA, L. C. — Human schistosomiasis: *Schistosoma mansoni* antigen detection in renal glomeruli. *Trans. roy. Soc. trop. Med. Hyg.*, 70: 492-496, 1976.
15. MARTINELLI, R.; GUSMÃO, E.; BRITO, E. & ROCHA, MUEHRCKE, R. C. & BLAINNEY, J. D. — The nephrotic syndrome in adults: a common disorder with many causes. *Ann. Intern. Med.*, 49: 751-774, 1958.
16. MARTINELLI, R.; GUSMÃO, E.; BRITO, E. & ROCHA, H. — Aspectos da evolução clínica da glomerulopatia associada à esquistossomose mansônica. *J. bras. Nefrol.*, 1: 20-24, 1979.
17. MORIEARTY, P. L. & BRITO, E. — Elution of renal anti-schistosome antibodies in human schistosomiasis mansoni. *Amer. J. trop. Med. Hyg.*, 26: 717-722, 1977.
18. NASH, T. E. — Factors that modulate clearance and ultimate fate of a specific schistosome antigen (GASP) in schistosome infections. *J. Immunol.*, 128: 1608-1613, 1982.
19. NATALI, P. G. & CIOLI, D. — Immune complex nephritis in *Schistosoma mansoni* infected mice. *Europ. J. Immunol.*, 6: 641-647, 1982.
20. OLIVEIRA, A. V.; ROQUE-BARREIRA, M. C.; SARTORI, A.; CAMPOS-NETO, A. & ROSSI, M. A. — Mesangial proliferative glomerulonephritis associated with progressive amyloid deposition in hamsters experimentally infected with *Leishmania donovani*. *Amer. J. Pathol.*, 12: 256-262, 1985.
21. PIRANI, C. L.; POLLAK, V. E. & SCHWARTZ, F. D. — The reproducibility of semi-quantitative analysis of renal histology. *Nephron.*, 1: 230-237, 1964.

22. QUEIROZ, F. P.; BRITO, E. & MARTINELLI, R. — Influence of regional factors in the distribution of the histologic patterns of glomerulopathies in the nephrotic syndrome. Nephron., 14: 466-470, 1975.
23. ROBINSON, A.; LEWERT, R. M. & SPARGO, B. H. — Immune complex glomerulonephritis and amyloidosis in *Schistosoma japonicum* infected rabbits. Trans. roy. Soc. trop. Med. Hyg., 76: 214-226, 1982.
24. SEYMOUR, A. E.; SPARGO, B. H. & PENKSA, R. — Contribution of renal biopsy studies to the understanding of disease. Amer. J. Path., 65: 550-585, 1971.
25. SILVA, L. C.; BRITO, T.; CAMARGO, M. E.; BONI, D. R.; LOPES, J. D. & GUNGI, J. — Kidney biopsy in the hepatosplenic form of infection with *Schistosoma mansoni* in man. Bull. Wld. Hlth. Org., 42: 907-910, 1970.
26. TADA, T.; KONDO, Y.; OKUMURA, K.; SANO, M. & YOKAGAWA, M. — *S. japonicum*: immunopathology of nephritis in *Macaca fascicularis*. Exp. Parasit., 38: 291-302, 1975.

Recebido para publicação em 29/11/86.