

## CASE REPORT

### PRIMARY PULMONARY AIDS-RELATED LYMPHOMA

Marcelo CORTI(1), María F. VILLAFANE(1), Norberto TRIONE(1), Ricardo SHTIRBU(1) & Marina NARBAITZ(2)

#### SUMMARY

Extranodal involvement is common in lymphomas associated with human immunodeficiency virus infection (HIV) and acquired immunodeficiency syndrome (AIDS). However, primary pulmonary AIDS-related non-Hodgkin's lymphoma is very rare and only few reports were published in the medical literature. Clinical presentation is nonspecific, with "B" and respiratory symptoms. Also, patients were with advanced immunodeficiency at the time of diagnosis. Generally, chest radiography showed peripheral nodules or cavitary masses. Primary pulmonary lymphoma associated with AIDS is generally a high-grade B-cell non-Hodgkin lymphoma and Epstein-Barr virus is strongly associated with the pathogenesis of these tumors.

We report a patient with AIDS and primary pulmonary lymphoma which clinical presentation was a total atelectasis of the left lung.

**KEYWORDS:** AIDS; Pulmonary lymphoma; Epstein-Barr virus.

#### INTRODUCTION

Patients infected with human immunodeficiency virus (HIV) have a higher risk to develop non-Hodgkin's lymphoma (NHL) with high frequency of extranodal lesions. Lymphoma occurs in 3 to 10% of patients with AIDS and is the second most common malignancy in this group<sup>2,16</sup>. This neoplasm is usually of high-grade B-cell type and the most frequent location is in the CNS, GI system, liver, spleen, and bone marrow. Thoracic involvement occurs in < 10% of the cases<sup>2</sup>. A variety of clinical forms of AIDS-related lymphoma in the chest have been described, including pleural effusion, interstitial and alveolar lung disease, peripheral nodules, and occasionally, hilar and mediastinal adenopathies<sup>4,18</sup>.

We report a rare case of primary pulmonary lymphoma (PPL) which clinical presentation was a total left pulmonary atelectasis.

#### CASE REPORT

A 46-year-old man infected with human immunodeficiency virus (HIV) and with hepatitis C (HCV) since 2000, had a history of transfusion in 1989 and an acute episode of hepatitis B in 2000. AIDS was diagnosed in 2003 after he presented *Candida* esophagitis. He has never received antiretroviral therapy; it was his own decision not follow the indicated treatment. He was admitted at our unit of AIDS-related infectious diseases with fever (38.5 °C), cough, shortness of breath with effort and weight loss. Physical examination revealed dyspnoea,

tachycardia and hypotension (95/60 mmHg). Pulmonary auscultation showed isolated crackles in right lung. He had lost approximately 15 kg weight during the previous three months. A chest X-ray showed an homogeneous left opacity with mediastinal deflection to the same side (Fig. 1). Relevant laboratory findings were leukocytes count 2800/mm<sup>3</sup>, hemoglobin 8 g/dL, platelets 143000/mm<sup>3</sup>, alkaline phosphatase 859 U/L, LDH 327 U/L. The CD4 T cell count was 18 cell/μL. Plasma viral load was 120 000 copies/mL (log<sub>10</sub> 5,10). Multiple blood, urine and sputum cultures were negative. An echography was performed showing hepatomegaly, splenomegaly of 14.5 cm and small isoechoic

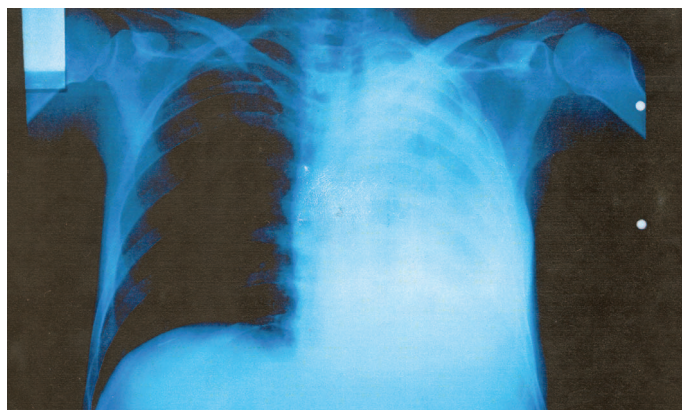


Fig. 1 - Chest radiograph showing a total atelectasis of left lung.

(1) Unit 10, Infectious Diseases, F.J. Muñoz Hospital, Buenos Aires, Argentina.

(2) Histopathology Laboratory, National Academy of Medicine, Buenos Aires, Argentina.

**Correspondence to:** Marcelo Corti, Puán 381, 2° C1406CQG, Buenos Aires, Argentina. E-mail: marcelocorti@fibertel.com.ar

adenopathies in hepatoduodenal ligament. Fiberoptic bronchoscopy was performed and revealed a tumor that completely obstructed as a whole the left bronchi, with invasion of trachea and carina. Several samples for biopsy and microbiological cultures were taken. A bone marrow biopsy was negative to detect atypical cells. Hepatic biopsy revealed cirrhosis probably related with his chronic HCV infection and was also negative for atypical infiltration. The patient died 15 days after he was admitted. His physical condition didn't allow him to receive either chemotherapy treatment or surgical resection. Histopathological examination of bronchial biopsies showed normal mucosa, the lamina propria mucosae showed an infiltrate with lymphoid cells with large, multinucleated cells, with prominent inclusions-like nucleoli, and abundant eosinophilic cytoplasm. The atypical cells showed an hyperchromatic central nuclei and one to three nucleoli near the basal membrane. The histologic findings were consistent with the diagnosis of high-grade non Hodgkin's lymphoma (Fig. 2). Immunostaining with monoclonal antibodies was performed and demonstrated that the atypical cells showed reactivity for the anti CD20; the T-cell marker CD3 was negative and Ki67 antigen proliferation index was 95%.

Epstein-Barr virus (EBV) associated latent membrane protein-1 (LMP-1) were detected in tumor cells by immunohistochemical (IHQ) and EBV-encoded mRNAs were also detected by *in situ* hybridization (ISH).

## DISCUSSION

Lymphoma is the second most common malignancy in AIDS patients<sup>2</sup>. The estimated relative risk of NHL associated with HIV

infection is 100 times greater than in general population. Like Kaposi's sarcoma (KS), the incidence of NHL increases with the progressive immunosuppression related to HIV. However, the association with the level of CD4 T cell count is higher for NHL than for KS.

Pulmonary involvement in lymphoid neoplasm can be manifested in three ways: 1) by hematogenous dissemination of the neoplasm, 2) by contiguous invasion from a hilar or mediastinal nodal lymphoma and 3) by primary pulmonary involvement. The first two situations involve progression or relapse of a known lymphomatous disorder and, in fact, is a metastasis of the hematological disease. The third situation, the PPL, is defined as an atypical lymphoid proliferation affecting one or both lungs in a patient with no detectable extrapulmonary involvement at the diagnosis or during the subsequent three months<sup>3,10</sup>.

When the lung is the primary tumor site, this definition includes: 1) multifocal, mucosa-associated lymphoid tissue (MALT); 2) pulmonary involvement with hilar or mediastinal lymph nodes and 3) multiorgan involvement by lymphomatous granulomatosis. Nevertheless this last definition is controversial because the extrapulmonary involvement is frequent<sup>3</sup>.

PPL is very rare; while extranodal forms represent 25% - 50% of cases of NHL, PPL only represents 3% - 4% of extranodal NHL and only 0.5% - 1% of primary pulmonary malignancies<sup>6,14</sup>. Until 2002 only 30 cases of PPL associated with AIDS were published in *Medline/Index Medicus* and *Embase* databases<sup>17</sup>.

Most cases of PPL are B cell tumors with a low level of malignancy, named as BALT lymphomas (bronchus-associated lymphoid tissue).

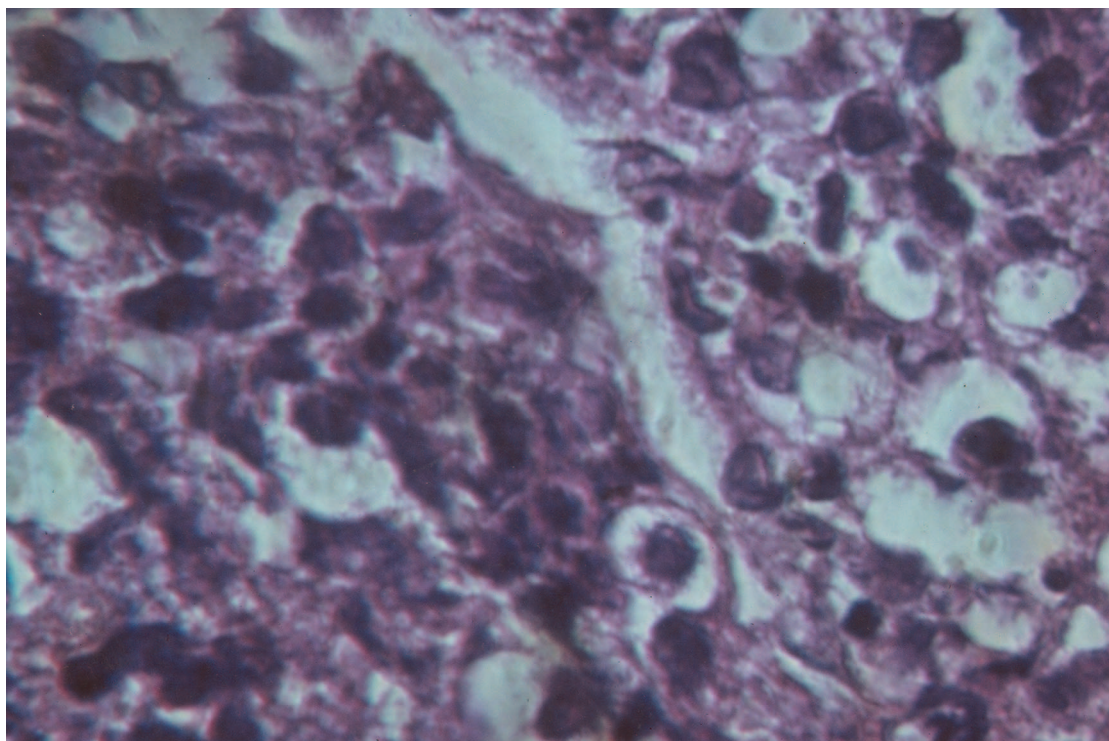


Fig. 2 - Bronchial biopsy revealed an atypical infiltrate of lymphocytes consistent with the diagnosis of high-grade pulmonary lymphoma.

However, in immunodeficient patients, highly malignant, large B cell histological forms are more common, as in the presented patient. RAY *et al.*<sup>17</sup> described 12 cases of AIDS-related primary pulmonary lymphoma, only three patients had not developed any AIDS-defining condition and all of them had a severe immunodeficiency with total CD4 count less than 50/ $\mu$ L. The CD4 lymphocyte count in our patient was 18 cell/ $\mu$ L.

Clinically, all patients present "B" symptoms at the moment of diagnosis of the neoplasia and the most frequent respiratory symptoms are thoracic pain associated with cough, hemoptysis and progressive dyspnoea, as the patient we present. Systemic "B" symptoms are frequently associated with advanced HIV disease and multiple opportunistic infections, such as tuberculosis and *Mycobacterium avium-intracellulare* disseminated disease.

Laboratory findings show haematological abnormalities such as anemia, thrombopenia, and/or leukopenia, associated with advanced HIV/AIDS disease. LDH plasma levels, that usually are elevated in AIDS-related NHL, are rarely increased in PPL<sup>9</sup>. Our patient presented normal levels of serum LDH.

The radiological manifestations of PPL consist of unilateral and bilateral nodes or of a subpleural pulmonary infiltrate or mass that may cavitate. None of the 12 patients evaluated by RAY *et al.*<sup>17</sup> or the seven studied by BAZOT *et al.*<sup>2</sup> definite hilar or mediastinal adenopathies; nor pleural effusion was noted in any of the patients. Nevertheless, this two radiological signs were observed in 21% of 54% and 44% of 73% of the patients with systemic AIDS-related NHL. Besides, PORCEL PEREZ & RUBIO CAVALLERO<sup>16</sup> described pleural involvement as the first sign of AIDS-related pulmonary lymphoma. Cavitory lesions and interstitial infiltrates also has been described. Our patient presented a total left pulmonary atelectasis, although less than 10% has this radiological pattern<sup>7,11,13</sup>.

Bronchial endoscopy may show from a normal macroscopic aspect to bronchial stenosis as showed in our patient. The diagnostic yields of bronchial, and especially transbronchial biopsy is higher when targets lesions or radiographic abnormalities are seen as in our case.

Finally, diagnosis can be made by transthoracic needle biopsy of the lung, guided by computed tomography, especially with solid mass nodules or subpleural masses.

There is evidence of a correlation between EBV and the high incidence of lymphomas in AIDS patients. The most plausible explanation for this relation is the ability for EBV to cause ongoing B cell proliferation in severe immunosuppressed patients. Epstein-Barr virus (EBV) is strongly associated with the pathogenesis of these tumors in AIDS patients and can be demonstrated using antilient membrane protein-1 antibodies and an Epstein-Barr-Virus-encoded RNA transcript-specific probe<sup>19</sup>.

RAY *et al.*<sup>17</sup> and BAZOT *et al.*<sup>2</sup> detected latent EBV infection in tumor cells from all the patients with AIDS-related PPL. PPL may be related to the severe immunodeficiency in AIDS patients with a similar pattern reactivation of latent EBV infection inside the lung as can be observed in all cases of primary CNS lymphoma<sup>8,12</sup>. We detected DNA-

EBV genome in the atypical cells in our patient by two methods: ISH and IHQ.

The median survival in patients with PPL is four months and it is lower than the described for all forms of AIDS-related NHL. PPL progression is the major cause of death and opportunistic infections also occur frequently associated with chemotherapy<sup>1,5,15,17</sup>. Our patient survived 15 days since the diagnosis and he couldn't receive specific treatment (surgical or chemotherapy) on account of his physical condition.

## RESUMEN

### Linfoma primario de pulmón en un paciente con sida

El compromiso extranodal es frecuente en los linfomas asociados con la enfermedad debida al virus de la inmunodeficiencia humana y su consecuencia, el síndrome de inmunodeficiencia adquirida. Sin embargo, el linfoma pulmonar primario es muy raro y solo existen pocos casos publicados en la literatura. La presentación clínica de esta complicación es inespecífica, con síntomas "B" y manifestaciones respiratorias. Generalmente, la radiografía de tórax muestra nódulos periféricos o masas que pueden cavitarse y los pacientes presentan inmunodeficiencia severa al momento del diagnóstico. El linfoma pulmonar primario asociado con el sida es un tumor de alto grado, de células B y asociado en su patogenia con el virus de Epstein-Barr. Se relata un caso de linfoma primario de pulmón que se presentó bajo la forma radiológica de una atelectasia global del pulmón izquierdo.

## REFERENCES

1. BASELGA, J.; KROWN, S.E.; TELZAK, E.E.; FILIPPA, D.A. & STRAUS, D.J. - Acquired immune deficiency syndrome-related pulmonary non-Hodgkin lymphoma regressing after zidovudine therapy. *Cancer*, 71: 2332-2334, 1993.
2. BAZOT, M.; CADRANEL, J.; BENAYOUN, S. *et al.* - Primary pulmonary AIDS-related lymphoma: radiographic and CT findings. *Chest*, 116: 1282-1286, 1999.
3. CADRANEL, J.; WISLEZ, M. & ANTOINE, M. - Primary pulmonary lymphoma. *Europ. respir. J.*, 20: 750-762, 2002.
4. CARIGNAN, S.; STAPLES, C.A. & MÜLLER, N.L. - Intrathoracic lymphoproliferative disorders in the immunocompromised patients: CT findings. *Radiology*, 197: 53-58, 1995.
5. CHECHANI, V.; ALLAM, A.A. & KAMHOLZ, S.L. - Pulmonary non-Hodgkin's lymphoma mimicking infection. *Respir. Med.*, 84: 401-405, 1990.
6. CLAGETTOT, O.T.; ALLEN, T.H.; PAYNE, W.S. & WOOLNER, L.B. - The surgical treatment of pulmonary neoplasms. A 10 year experience. *J. thorac. cardiovasc. Surg.*, 48: 391-400, 1964.
7. CORDIER, J.F.; CHAILLEAUX, E.; LAUQUE, D. *et al.* - Primary pulmonary lymphomas. A clinical study of 70 cases in nonimmunocompromised patients. *Chest*, 103: 201-208, 1993.
8. CORTI, M.; VILLAFANE, F.; TRIONE, N. *et al.* - Linfomas primarios del sistema nervioso central en pacientes con sida. *Enferm. infecc. Microbiol. clin.*, 22: 332-336, 2004.
9. EISNER, M.D.; KAPLAN, L.D.; HERNDIER, B. & STULBARG, M.S. - The pulmonary manifestations of AIDS-related non-Hodgkin's lymphoma. *Chest*, 110: 729-736, 1996.

10. FREEMAN, C.; BERG, J.W. & CUTLER, S.J. - Occurrence and prognosis of extranodal lymphomas. **Cancer**, 29: 252-260, 1972.
11. HERBERT, A.; WRIGHT, D.H.; ISAACSON, P.G. & SMITH, J.L. - Primary malignant lymphoma of the lung: histopathologic and immunologic evaluation of nine cases. **Hum. Path.**, 15: 415-422, 1984.
12. KOHLER, C.A.; GONZALEZ-AYALA, E.; ROWLEY, P.; MALAMUD, F. & VERGHESE, A. - Primary pulmonary T-cell lymphoma associated with AIDS: the syndrome of the indolent pulmonary mass lesion. **Amer. J. Med.**, 99: 324-326, 1995.
13. Le TOURNEAU, A.; AUDOUIN, J.; GARBE, L. *et al.* - Primary pulmonary malignant lymphoma, clinical and pathological findings, immunocytochemical and ultrastructural studies in 15 cases. **Hemat. Oncol.**, 1: 49-60, 1983.
14. L'HOSTE Jr., R.J.; FILIPPA, D.A.; LIEBERMAN, P.H. & BRETSKY, S. - Primary pulmonary lymphomas. A clinicopathologic analysis of 36 cases. **Cancer**, 54: 1397-1406, 1984.
15. POELZLEITNER, D.; HUEBSCH, P.; MAYERHOFER, S.; CHOTT, A. & ZIELINSKI, C. - Primary pulmonary lymphoma in a patient with the acquired immune deficiency syndrome. **Thorax**, 44: 438-439, 1989.
16. PORCEL PEREZ, J.M. & RUBIO CABALLERO, M. - Primary pulmonary lymphoma with pleural involvement as the first sign of acquired immunodeficiency syndrome. **Arch. Bronconeumol.**, 39: 433-434, 2003.
17. RAY, P.; ANTOINE, M.; MARY-KRAUSE, M. *et al.* - AIDS-related primary pulmonary lymphoma. **Amer. J. respir. Crit. Care Med.**, 158:1221-1229, 1998.
18. SIDER, L.; WEISS, A.J.; SMITH, M.D.; VON ROENN, J.H. & GLASSROTH, J. - Varied appearance of AIDS-related lymphoma in the chest. **Radiology**, 171: 629-632, 1989.
19. WEISS, L.M.; CHEN, Y-Y.; LIU, X-F. & SHIBATA, D. - Epstein Barr virus and Hodgkin's disease. A correlative *in situ* hybridization and polymerase chain reaction study. **Amer. J. Path.**, 139: 1259-1265, 1991.

Received: 21 December 2004

Accepted: 30 May 2005