

## VIEWPOINT

# GRANULOMATOUS INFLAMMATION

T. de BRITO & M. F. FRANCO

### GENERAL COMENTS

Granulomatous inflammation may be defined as a type of chronic inflammation in which a compact collection of cells of the mononuclear phagocyte system<sup>37</sup>, chiefly activated macrophages and cells derived from them are predominant<sup>1,39</sup>. These cells are aggregated into well demarcated focal lesions and the designation granuloma (granule + oma = tumor) derives from this peculiar aspect. In addition, granulomas usually contain an admixture of other cells, especially lymphocytes and plasma cells, and, depending on their stage, fibroblasts<sup>39</sup>. Eosinophils are usually present in parasitic and fungal granulomas.

The term activated macrophage implies either that an increase in the functional activity of the macrophage has occurred or that a new functional activity has appeared. Newly arrived monocytes are initially simple cells which progressively increase their nuclear euchromatin content, develop prominent nucleoli, extensive cytoplasm, free ribosomes, abundant Golgi apparatus, large lysosomes and finally acquire the morphology of the so-called activated macrophages.

The mononuclear phagocytic system as defined by VAN FURTH *et al.*<sup>37</sup> has evolved from the reticulo-endothelial system concept elaborated by ASCHOFF and coworkers<sup>4</sup> and comprises the group of highly phagocytic mononuclear cells and their precursors which are widely distributed in the body; they share many morphologic and functional features and originate from the bone marrow. Macrophages, monocytes, promonocytes, monoblasts, Kupffer cells, microglia and osteoclasts are all components of the system<sup>27</sup>.

Macrophages originate from bone marrow precursors via circulating monocytes through a maturation

process which is accompanied by morphological and functional changes; the process continues even when macrophages enter the tissues, were they are also called histiocytes<sup>1</sup>. The turnover time in most instances is about one to two weeks<sup>27</sup>. The production of monocytes is under feedback control; peripheral macrophages and lymphocytes secrete factors that have both stimulatory and inhibitory actions on stem cell proliferation in the bone marrow. Although exudation seems to be by far the most important source of macrophages in the inflammatory reaction, local histiocytic proliferation does occur<sup>1,39</sup>.

All granulomatogenic factors share one basic property, namely, they are poorly degradable materials. Thus, granulomatous inflammation can be regarded as a response to pathogens and persistent irritants of either exogenous or endogenous origin<sup>21</sup>. Soluble materials, however, can also produce granulomas when they combine with endogenous macromolecules to form insoluble, undegradable compounds<sup>29</sup>.

### TYPES OF GRANULOMA

Granulomas fall into two groups, namely foreign body or low turnover cell and epithelioid, hypersensitivity<sup>12</sup> or high turnover cell types<sup>38</sup>.

An inducing agent is often recognizable in **foreign body granulomas**, usually phagocytosed by macrophages and foreign body giant cells. The foreign body granuloma is a poorly organized granuloma with focal aggregates of macrophages intermixed with few lymphocytes and plasma cells. Epithelioid cells are either scarce or absent. Cell kinetics shows that there is a low turnover of macrophages; the few dying cells are re-

(1) University of S. Paulo, Medical School, Department of Pathology and Institute of Tropical Medicine, São Paulo, Brasil.

(2) "Universidade Estadual Paulista" Botucatu Medical School, Department of Pathology, Botucatu, S. Paulo, Brazil.

Address for correspondence: Dr. Thales de Brito. Faculdade de Medicina da USP - Departamento de Patologia. Av. Dr. Arnaldo-455, 01246-903 S. Paulo, S.P. - Brasil.

placed either by new recruits from the circulation or by local cell proliferation. Macrophages of these low turnover lesions survive 4-8 weeks<sup>1</sup>. Granulomatogenic agents, although poorly degradable, are relatively inert and nontoxic to the cells. Immune mechanisms are of minor importance in the pathogenesis of foreign body granulomas which may be regarded as "phagocytic granulomas". Macrophages and foreign body giant cell are frequently seen apposed to the inducing agent which is often observed internalized by the giant cell. Two giant cell categories can be distinguished by their morphological characteristics which may be seen both in foreign body and epithelioid granulomas but in different proportions: the foreign body giant cell which shows nuclei randomly dispersed throughout the cytoplasm in a disorganized manner, and predominates in the foreign body granuloma, and the Langhans cell type which shows nuclei located at the cell margins and is seen in the epithelioid granuloma<sup>1</sup>. Both cells originate from fusion of macrophages rather than nuclear division and probably result from the attempt of two or more macrophages to phagocytose a single particle, which results in the fusion of their plasma membranes. Foreign body giant cells mature into Langhans cells, probably by movements of the intracellular cytoskeleton<sup>1</sup>. Actin filaments are demonstrated both in macrophages and giant cells in the cell periphery and in microtubules radiating from the perinuclear into the peripheral cytoplasm. Actin filaments are important elements for the phagocytic function of these cells. The distribution of the cytoskeletal components of these cells may be characteristic of free wandering cells since it is seen in other free cells such as polymorphonuclear leukocytes and fibroblasts<sup>6</sup>.

At least one cytokine, the monocyte chemoattractant protein 1 (MCP-1), which is released by monocytes following phagocytosis<sup>18</sup>, may be involved in the foreign body granuloma formation. Human monocytes have high affinity receptors for MCP and the release of this cytokine by macrophages which have ingested material of a biochemical or biological nature causes further monocyte recruitment and cell activation.

**Epithelioid or hypersensitivity granulomas** are high turnover granulomas produced by irritants which are injurious to macrophages such as silica and infectious agents. In these granulomas a high rate of recruitment and local division of macrophages are observed to compensate for the relatively short life span (usually only a few days) and high death rate of these cells within

the lesion<sup>1</sup>. The causative agent, when present, is detected only in a small proportion of phagocytic cells, usually at the center of the granuloma. Epithelioid granulomas consist of a cohesive collection of cells which range from phagocytic and activated macrophages to epithelioid cells. Epithelioid cells arrange themselves in layers or form discrete aggregates in the central part of the lesion or around necrotic areas. They originate from macrophage precursors and have an elongated euchromatin nucleus, conspicuous nucleoli and an abundant cytoplasm with prominent endoplasmic reticulum and few lysosomes. The cells appear to be closely associated, and are interlocked by pseudopods in zipper-like arrays but with no junctional specialization. Epithelioid cells show large numbers of pale-staining secretory vacuoles in the cytoplasm and little evidence of phagocytic activity<sup>29</sup>. The vacuoles do not contain acid phosphatase, suggesting that they are not of lysosomal origin. Moreover, there is evidence that the expression of surface immune receptors (Fc and C3b) seen in macrophages is considerably reduced or absent in epithelioid cells. At an early stage, epithelioid granulomas show an admixture of macrophages, few epithelioid cells and lymphocytes. Lymphocytes at the center of the granuloma are mostly CD4 (helper-inducer) T lymphocytes<sup>29</sup>. When the granuloma matures, a halo of B and chiefly CD8 (suppressor-cytotoxic) T lymphocytes is observed at the periphery together with fibroblasts. It is assumed that these T and B lymphocytes represent progressive clonal expansion specific for the antigen/s present in the granuloma. Giant cells, mostly of the Langhans type, are detected chiefly at the center of the lesion. They may express Fc and C3b surface receptors found in macrophages and they are able to phagocytose bacteria and fungi.

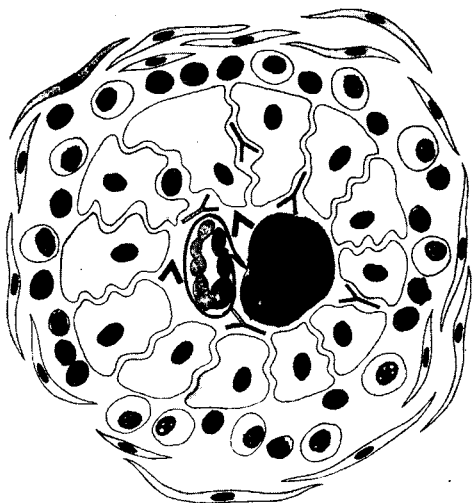
#### IMMUNOPATHOGENESIS OF THE SCHISTOSOMAL GRANULOMA

Among the experimental and human epithelioid granulomas, the immunopathogenesis of the schistosomal granuloma is one of the best studied. Schistosomiasis mansoni represents the first form of granulomatous inflammation that has been clearly shown to be of immunological origin<sup>7,8,38</sup>. Its formation is primarily a manifestation of cell mediated immunity (CMI) as demonstrated by passive transfer, association with other forms of CMI and response to immunosuppressive measures<sup>7,8,38</sup>. Schistosomal eggs possess a fenestrated shell and it has been suggested that antigenic materials

secreted by the embryo within might cross the shell through the pores. The probable events leading to the schistosomal egg granuloma begin with antigen-presenting cells (APC), mostly macrophages, expressing major histocompatibility (MHC) class II antigens, interacting with T lymphocytes with production of cytokines.

At this stage gamma-interferon (gamma-IFN) appears to up-regulate the MHC class II display on APC and the induction of cytokines such as interleukin 1 (I1) and tumor necrosis factor (TNF) production by macrophages<sup>20</sup>. I11 in synergism with TNF plays an important role in granuloma induction *in vitro*<sup>30,36</sup>. Other cytokines such as MCP-1 amplify the inflammatory response and the recruitment of stimulated macrophages. Experimental data have recently shown that T cell cytokines such as I1-2 and I1-4 appear to play a proinflammatory role in granuloma formation while gamma-IFN down-modulates its formation during the peak phase<sup>20</sup>. In the schistosomal granuloma, eosinophils may be part of the CMI reaction and their

#### ANTIGEN AND ANTIBODY DIFFUSION IN THE *S. mansoni* EGG GRANULOMA .



▲ ANTIGEN  
● ANTIBODY

Fig. 1 - The probable role of immunoglobulins in the local defense mechanisms of schistosomal granulomatous inflammation is depicted in a schematic representation. The granuloma is built up through CMI. The antigen/s filters in small doses through the barrier of epithelioid cells and is slowly neutralized by immunoglobulin/s which also penetrates between epithelioid cells and is produced by specific cells in the inflammatory peripheral halo.

depletion delays egg destruction. Stimulated macrophages evolve to epithelioid and giant cells. Lymphocytes and plasma cells form a halo surrounding the granuloma. Different degrees of collagen synthesis due to an interaction of macrophages and lymphocytes with fibroblasts may also be seen at the periphery of the granuloma<sup>7,8</sup>. Both human and experimental evidence<sup>9,10</sup> has suggested that during the early phase of the granulomatous inflammation, the response consists of activated macrophages, few epithelioid and giant cells intermixed with CD4 (helper-inducer) T lymphocytes which cannot completely wall off the antigen/s present at the center of the granuloma. As the granuloma matures, antigen/s become restricted to the miracidium and immunoglobulins, chiefly of the IgG class, are detected at the periphery, corresponding to the inflammatory halo, where immunoglobulin-producing cells are observed. Epithelioid cells act as a barrier between antigens at the center and antibodies produced by B lymphocytes in the peripheral inflammatory halo; therefore these cells play a critical role in the granulomatous inflammation. Slow permeation of antigens and antibodies, which probably takes place throughout the granuloma, allows antigen neutralization in small doses, thus preventing the local formation of large immunocomplexes which would produce marked tissue injury through complement activation. The small antigen-antibody complexes formed may be removed by local macrophages<sup>9,10</sup> (Fig. 1). Though the deleterious role of the granulomatous inflammation, through the secretion of tissue-destructive substances by its cell population, has been extensively studied<sup>8</sup>, it now appears that granuloma formation is intrinsically favorable to the host. Viewed as a whole, the schistosomal egg granuloma may be regarded as an efficient structure which walls off antigen/s and harmful substances locally produced through a mixed, chiefly cellular but also local antibody-mediated immune response<sup>9,10</sup>.

#### IMMUNOPATHOGENESIS OF THE *P. BRASILIENSIS* GRANULOMA

The *P. brasiliensis* granuloma is generally centered around one or more fungal cells and is composed of giant cells and epithelioid cells; therefore it is an epithelioid granuloma. Polymorphonuclear leukocytes may be observed close to the fungi in the central area; encircling the granuloma, there is a halo of mononuclear cells. The granulomas may show central necrosis of the coagulative type in addition to central suppuration<sup>15</sup>.

Several findings in human and experimental para-

coccidioidomycosis have indicated that the paracoccidioidal granuloma may represent an immune-specific response of the host to the fungus. Paracoccidioidomycosis presents two polar clinical forms, namely the **hyperergic pole** which is characterized by localized infection, persistent cellular immune response and a compact epithelioid granuloma, and the **anergic pole** which is represented by disseminated infection, decreased cellular immunity and loose, parasite-rich, granulomatous inflammation. The hyperergic type of reaction is typically seen in the patients with "ides" manifestations or with the sarcoidic form of the disease. The anergic pole in which granulomas have no ability to kill the fungal cells is reproduced in athymic mice as well as in patients with AIDS<sup>15, 16, 17, 24</sup>.

The microanatomy of *P. brasiliensis* granulomas has been investigated by the use of immunohistochemical techniques and monoclonal antibodies to T-lymphocyte subsets. *P. brasiliensis* granulomas, both in patients and in experimentally infected mice, show a T-cell peripheral mantle around central aggregates of macrophages. The majority of the lymphocytes have a T-helper phenotype with few suppressor CD8<sup>+</sup> cells, indicating that these cells are actively involved in the pathogenesis of the lesions and in disease control. In the granuloma, the majority of macrophages stain for lysozyme which shows their secreting nature and the potentiality to release microbicidal products into the granuloma milieu<sup>25</sup>. High levels of TNF and angiotensin-converting enzyme have been documented in paracoccidioidomycosis patients<sup>22, 23, 33</sup>; the local release of these products may be involved in the regulation of the granulomatous inflammation, as suggested for sarcoidosis, histoplasmosis and leprosy. It seems that in paracoccidioidomycosis, TNF may act as an immunomodulator capable of enhancing and amplifying the immune response and promoting macrophage-mediated parasite killing<sup>14, 33</sup>. In the peripheral halo, there is a population of cells which stain for S-100 protein (APC). The presence of the APC in close association with the T-helper lymphocytes in the granuloma may favor the interplay between these cells with the release of T-cell stimulating factors, such as IL2. Lymphokines released by activated lymphocytes may attract, fix and activate macrophages at the inflammatory foci. The activated macrophages may then show enhanced killing of *P. brasiliensis*, secrete cytokines and further differentiate into epithelioid cells<sup>15, 25</sup>. In addition,

cytokines amplify the natural host defense against the parasite as documented by their ability to increase the fungicidal activity of neutrophils, which are cells frequently found around the fungal cells, at the center of the granuloma<sup>15</sup>. Fungal products may by themselves stimulate macrophages to secrete cytokines able to induce epithelioid cell transformation; these cells, however, in the absence of an immune response are less efficient in blocking the proliferation of the parasite<sup>5, 24</sup>.

An epithelioid cell-derived macrophage deactivating factor (ECD-MDF) has been recently described which exerts by a feedback mechanism a suppressive effect on the activated macrophage, the major effector cell of the immune system<sup>21</sup>. These findings demonstrate that macrophages can be modulated in two different directions of activity. First, the well known cell activation process, which enhances the microbicidal and tumoricidal capacity of the cell. Second, they might be modulated to secrete factors which inhibit macrophage activation, controlling tissue healing on the one hand and facilitating persistence of agents in the tissues on the other<sup>21</sup>.

Natural killer (NK) cells are another cellular component identified in the paracoccidioidal granuloma. They have been shown to limit the growth of *P. brasiliensis* in culture, suggesting that they may play a defensive role in paracoccidioidomycosis. Their cytotoxic activity is significantly lower in patients with paracoccidioidomycosis, a fact interpreted as an escape mechanism of the fungus<sup>28</sup>.

*P. brasiliensis* granulomas are also characterized by a large number of IgG-secreting plasma cells at the periphery. In addition, IgG and C3 deposits on the *P. brasiliensis* cell wall are common findings within the granuloma, suggesting a participation of these humoral components in the blocking of antigenic diffusion and even of fungal survival<sup>15, 25</sup>. Trapping of fungal antigens inside macrophages in *P. brasiliensis* granulomas may also be demonstrated by immunohistochemical techniques, using an anti-*P. brasiliensis* antibody<sup>15, 25</sup>.

Another approach to the study of the morphogenesis of the paracoccidioidal granuloma has been to look at the granuloma-inducing activity of chemical components of *P. brasiliensis* cells. The intravenous inoculation of lipids extracted from yeast cells into

mice, in the form of coated charcoal particles, induces an intense pulmonary granulomatous reaction around the particles. The active fractions were mainly composed of free fatty acids and triglycerides. The data suggest that the formation of the granulomatous process may depend on the chemical composition of the agent which would attract and organize the macrophages around the parasitic cells <sup>32</sup>.

A similar study was carried out with the cell wall polysaccharides of yeast cells. The intravenous inoculation of an alkaline-soluble, acid-soluble fraction obtained after lipid extraction of yeast cell walls, induces an intense polymorphonuclear cell infiltrate in the lungs of mice at an early stage; later, the cellular infiltrate is composed predominantly of large, tightly packed mononuclear cells, with a tendency to organization and maturation to epithelioid cells. In addition, the intraperitoneal inoculation of the fraction stimulates peritoneal macrophages, suggesting that the polysaccharide component might play an important role in paracoccidioidomycosis <sup>2, 31</sup>. The presence of the lipid and polysaccharide components of the fungus due to multiplication of *P. brasiliensis* at the lesional sites provides elements for the understanding of some aspects of the inflammatory response observed in paracoccidioidomycosis, such as the neutrophil influx observed after fungal presentation and multiplication, the presence of suppuration in the center of the granuloma and the macrophage-rich exudate organized as epithelioid granulomas <sup>2, 15, 31</sup>.

Further studies have investigated the granuloma-stimulating capacity of soluble *P. brasiliensis* components in animals with and without previous specific immunization. In immunized mice injected i. v. with bentonite particles coated with *P. brasiliensis* antigens, the inflammatory area around small pulmonary vessels is significantly greater than that in nonimmunized animals. In addition, the inflammatory process evolves to fully developed epithelioid granulomas, as seen by electron microscopy which shows macrophages with characteristically interdigitated cytoplasmic borders. This finding reinforces the importance of cellular immunity in the genesis of epithelioid granulomas in paracoccidioidomycosis <sup>15</sup>.

Overall, the approach to the understanding of *P. brasiliensis* granulomas has considered either T-lymphocytes or macrophages as the pivotal cells in the

morphogenesis of the inflammatory process. It is more likely that both cells individually and synergistically play an important role in the development of the granulomas through the release of inflammatory mediators that activate mechanisms of host defense against the parasite.

#### ROLE OF THE IMMUNE RESPONSE IN GRANULOMA FORMATION

A primary role of CMI in granuloma formation has been emphasized in the literature. However, insoluble antigen antibody complexes are able to produce granulomatous inflammation under experimental conditions <sup>35</sup>. Moreover suppurative granulomas, a distinctive form of inflammatory tissue reaction, found in various infectious processes such as cat-scratch disease, lymphogranuloma venereum, atypical tuberculosis, *Yersinia* lymphadenitis and tularemia, maintain a close relationship with B-lymphocytes; local secretion of specific immunoglobulins may occur, with subsequent formation of immune complexes which may recruit neutrophils via complement activation <sup>13</sup>. It has been suggested that during an early phase of the suppurative granuloma formation there is a initial phase of T-cell-mediated immune response.

Abnormalities in the immune reaction might be associated with the development of a T-independent, macrophage-mediated immune response resulting in the recruitment and activation of monocytoid B cells within the granulomas <sup>13</sup>. Similar events may take place in immunosuppressed patients; the predominance of a humoral response with the formation of insoluble antigen-antibody complexes may be the basis for the incomplete granulomatous response seen in these patients and also occasionally in athymic mice.

The experimental immunopathogenesis of *S. japonicum* egg granulomas may differ, at least in its earlier events, from that of *S. mansoni*. *S. japonicum* eggs are produced in large aggregates, while *S. mansoni* eggs enter the tissues singly. The lesions in schistosomiasis *japonica* are made up of eosinophilic abscesses, which appear soon after egg-laying; necrosis and plasma cell infiltration are seen both in the granulomas and in the periportal inflammation <sup>38</sup>. Recent data <sup>19</sup> have shown an Arthus type hypersensitivity, which is a complement mediated response, and an immediate type of hypersensitivity which is an interleukin-4-induced reaction, occurring early in *S. japonica* egg granulomas; these

reactions may be related to eosinophil accumulation, necrosis and plasma cell infiltration. Later a strong CMI reaction appears, which corresponds to the granuloma and fibrotic stages. Moreover, it has been demonstrated that the cellular components participating in egg-granuloma formation differ greatly according to the tissues involved <sup>19</sup>.

In conclusion, it appears that the immunopathogenesis of the high-turnover granuloma is not unique. Host and parasite factors interact in order to stimulate either a CMI or an antigen-antibody insoluble complex immunopathogenesis. Failure of the CMI system may change the way high-turnover granulomas are formed. In many epithelioid granulomas, the associated local humoral response is possibly important as a defense mechanism (Fig. 2).

### GRANULOMA NECROSIS AND FIBROSIS

Granulomatous inflammation frequently results in tissue damage during the active phase, due to local secretory products of macrophages and neutrophils. Tuberculosis is a model of an immune-mediated high-turnover epithelioid granuloma which frequently presents extensive necrosis, usually at the center of the granuloma. Caseous necrosis in tuberculosis is regarded as having an immunological basis <sup>11</sup>. In the early tuberculosis lesion, there is little cellular death or tissue necrosis. The tubercle bacilli multiply within tissue macrophages in a state of symbiosis until the time when an immune response occurs. A clonally exuded T lymphocyte population then appears in response to specific antigens of the tubercle bacillus. Chemotactic cytokines for macrophages and lymphocytes are pro-

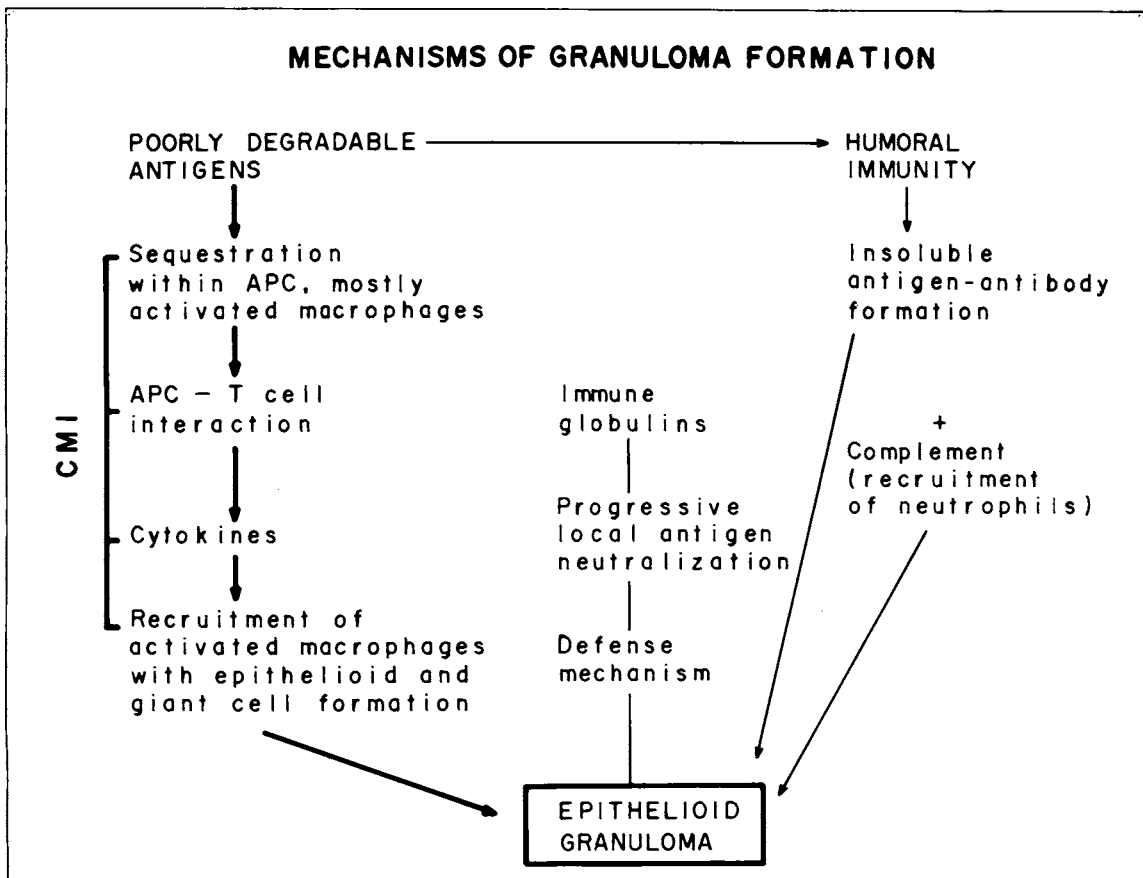


Fig. 2 - CMI is fundamental in the immunopathogenesis of epithelioid granuloma formation. The humoral arm of immunity may contribute either as an accessory defense mechanism or, with the failure of the cellular arm of immunity, may be responsible for the suppurative and/or loosely arranged epithelioid granuloma.

CMI = Cell-mediated immunity  
 APC = antigen-presenting cell

duced which lead to macrophage aggregation and local activation with phagocytosis and killing of bacilli. Under experimental conditions, it appears that, in BCG-induced granulomas, antigen-specific CD4 + T cells and their products are needed for macrophages to acquire the mycobactericidal function that enables them to control the infection <sup>26</sup>. CMI is therefore a favorable immunologic reaction for the host that appears when there is a low local concentration of antigen/s. On the other hand, a high local concentration of antigen/s speeds up the accumulation and activation of lymphocytes and macrophages at the site of antigen deposition and may cause caseation and liquefaction <sup>11</sup>. Liquefaction is due to lysis of protein, lipid and nucleic acid components of the caseum by hydrolytic enzymes of macrophages and granulocytes. Liquefaction perpetuates the disease in humans since the liquefied caseum facilitates the dissemination of the disease <sup>11</sup>.

In other parasitic granulomas where central necrosis is observed, like those of cutaneous leishmaniasis, probably similar pathogenetic mechanisms are responsible for the tissue damage <sup>34</sup>.

However, factors other than CMI also produce necrosis. Substances like silica are toxic to macrophages and cause necrosis by leakage of lysosomal enzymes <sup>1</sup>.

Fibrosis is a common terminal event of the granulomatous inflammation. Non immunological, low turnover, foreign body type granulomas stimulate the least amount of collagen production. On the other hand, in high turnover granulomas, in which CMI is of considerable importance, fibrogenesis is marked and probably related to a direct action of cytokines produced by cells of the granuloma, chiefly T lymphocytes and macrophages <sup>8</sup>.

In schistosomal granuloma and in the ensuing portal connective tissue deposition, histological changes suggestive of collagen matrix degradation have been described <sup>3</sup> thus showing that fibrosis may be partially reversible.

#### ACKNOWLEDGEMENTS

We are indebted to Prof. Mario Rubens Montenegro for revising the manuscript and for valuable scientific advice. The authors also wish to thank Miss Maria Eli P. de Castro for secretarial help.

#### REFERENCES

- ADAMS, D. O. - The granulomatous inflammatory response. A review. *Amer. J. Path.*, **84**: 164-192, 1976.
- ALVES, L. M. C.; FIGUEIREDO, F.; BRANDÃO FILHO, S. L.; TINCARI, I. & SILVA, C. L. - The role of fractions from *Paracoccidioides brasiliensis* in the genesis of inflammatory response. *Mycopathologia* (Den Haag), **97**: 3-7, 1987.
- ANDRADE, Z. A.; PEIXOTO, E.; GUERRET, S. & GRIMAUD, J. A. - Hepatic connective tissue changes in hepatosplenic schistosomiasis. *Hum. Path.*, **23**: 566-573, 1992.
- ASCHOFF, L. - Reticulo-endothelial system. In: ASCHOFF, L. - *Lectures on Pathology*. New York, Paul. B. Hoeber, 1924. p. 1-33.
- ARRUDA, M. S. P.; COELHO, K. I. R. & MONTENEGRO, M. R. - Experimental paracoccidioidomycosis in the Syrian hamster inoculated in the cheek pouch. *Mycopathologia* (Den Haag) (Submitted to Publication, 1993).
- BABA, T.; SHIOZAWA, N.; HOTCHI, M. & OHNO, S. - Three-dimensional study of the cytoskeleton in macrophages and multinucleate giant cells by quick-freezing and deep-etching method. *Virchows Arch. B. cell Path.*, **61**: 39-47, 1991.
- BOROS, D. L. - Granulomatous inflammation. *Progr. Allergy*, **24**: 183-267, 1978.
- BOROS, D. L. - Immunopathology of *Schistosoma mansoni* infection. *Clin. Microbiol. Rev.*, **2**: 250-269, 1989.
- DE BRITO, T.; HOSHINO-SHIMIZU, S.; SILVA, L. C. et al. - Immunopathology of experimental schistosomiasis (*S. mansoni*) egg granulomas in mice: possible defence mechanisms mediated by local immune complexes. *J. Path.*, **140**: 1-28, 1983.
- DE BRITO, T.; HOSHINO-SHIMIZU, S.; YAMASHIRO, E. & SILVA, L. C. - Chronic human schistosomiasis mansoni: schistosomal antigen, immunoglobulins and complement C3 detection in the liver. *Liver*, **5**: 64-70, 1985.
- DANNENBERG, A. M. - Immune mechanisms in the pathogenesis of pulmonary tuberculosis. *Rev. infect. Dis.*, **2** (Suppl. 2): S369-S378, 1989.
- EPSTEIN, W. L. - Granuloma formation in man. *Path. Ann.*, **7**: 1-30, 1977.
- FACCHETTI, F.; AGOSTINI, C.; CHILOSI, M. et al. - Suppurative granulomatous lymphadenitis. *Amer. J. surg. Path.*, **16**: 955-961, 1992.
- FIGUEIREDO, F.; ALVES, L. M. C. & SILVA, C. L. - Tumor necrosis factor production *in vivo* and *in vitro* in response to *Paracoccidioides brasiliensis* and the cell wall fractions thereof. *Clin. exp. Immunol.*, **93**: 189-194, 1993.
- FRANCO, M.; MOSCARDI-BACCHI, M.; BACCHI, C. E. et al. - Pathogenesis of *Paracoccidioides brasiliensis* granuloma. In: TORRES-RODRIGUEZ, J. M., ed. Proceedings of the X Congress of the International Society for Human and Animal Mycology (ISHAM). Barcelona, J. R. Prous Science, 1988. p. 138-142.
- FRANCO, M.; MENDES, R. P.; MOSCARDI-BACCHI, M.;

- REZKALLAH-IWASSO, M. & MONTENEGRO, M. R. - Paracoccidioidomycosis. *Baillière's Clin. Trop. Med. Commun. Dis.*, 4: 185-220, 1989.
17. FRANCO, M.; PERAÇOLI, M. T.; SOARES, A. et al. - Host-parasite relationship in paracoccidioidomycosis. *Curr. Top. med. Mycol.*, 5: 115-149, 1993.
18. FRIEDLAND, J. S. - Cytokines, phagocytosis, and *Mycobacterium tuberculosis*. *Lymphok. Cytok. Res.*, 12: 127-133, 1993.
19. HIRATA, M.; TAKASHIMA, M.; KAGE, M. & FUKUMA, T. - Comparative analysis of hepatic, pulmonary and intestinal granuloma formation around freshly laid *Schistosoma japonicum* eggs in mice. *Parasit. Res.*, 79: 316-321, 1993.
20. LUKACS, N. & BOROS, D. L. - Lymphokine regulation of granuloma formation in murine Schistosomiasis mansoni. *Clin. Immunol. Immunopath.*, 68: 57-63, 1993.
21. MARIANO, M. - Does macrophage deactivating factor play a role in the maintenance and fate of infectious granulomata? *Mem. Inst. Oswaldo Cruz*, 86: 485-487, 1991.
22. MENDES, R. P.; SCHEINBERG, M. A.; SOARES, A. M. V. C. & MARCONDES-MACHADO, J. - Evaluation of angiotensin converting enzyme in sera of patients with paracoccidioidomycosis. In: CONGRESS OF THE INTERNATIONAL SOCIETY FOR HUMAN AND ANIMAL MYCOLOGY (ISHAM), 11, Montreal, 1991. *Proceedings*. p. 172.
23. MENDES, R. P.; SCHEINBERG, M. A.; REZKALLAH-IWASSO, M. T. et al. - Evaluation of tumor necrosis factor in sera of patients with paracoccidioidomycosis. In: CONGRESS OF THE INTERNATIONAL SOCIETY FOR HUMAN AND ANIMAL MYCOLOGY (ISHAM), 11, Montreal, 1991. *Proceedings*. p. 172.
24. MIYAJI, M. & NISHIMURA, K. - Granuloma formation and killing functions of granuloma in congenitally athymic nude mice infected with *Blastomyces dermatitidis* and *Paracoccidioides brasiliensis*. *Mycopathologia* (Den Haag), 82: 129-141, 1983.
25. MOSCARDI-BACCHI, M.; SOARES, A.; MENDES, R.; MARQUES, S. & FRANCO, M. - "In situ" localization of T lymphocyte subsets in human paracoccidioidomycosis. *J. med. vet. Mycol.*, 27: 149-158, 1989.
26. NORTH, R. J. & IZZO, A. A. - Animal model: granuloma formation in severe combined immunodeficient (SCID) mice in response to progressive BCG infection. *Amer. J. Path.*, 142: 1959-1966, 1993.
27. PAPANITRIOU, J. M. & ASHMAN, R. B. - Macrophages: current views on their differentiation, structure, and function. *Ultrastruct. Path.*, 13: 343-372, 1989.
28. PERAÇOLI, M. T. S.; SOARES, A. M. V. C.; MENDES, R. P. et al. - Studies of natural killer cells in paracoccidioidomycosis. *J. med. vet. Mycol.*, 29: 373-380, 1991.
29. SHEFFIELD, E. A. - The granulomatous inflammatory response. *J. Path.*, 160: 1-2, 1990.
30. SHIKAMA, Y.; KOBAYASHI, K.; KASAHARA, K. et al. - Granuloma formation by artificial microparticles in vitro - macrophages and monokines play a critical role in granuloma formation. *Amer. J. Path.*, 134: 1189-1199, 1989.
31. SILVA, C. L. & FAZIOLI, R. A. - A *Paracoccidioides brasiliensis* polysaccharide having granuloma inducing, toxic and macrophage-stimulating activity. *J. gen. Microbiol.*, 131: 1497-1501, 1985.
32. SILVA, C. L. - Granulomatous reaction induced by lipids isolated from *Paracoccidioides brasiliensis*. *Trans. roy Soc. trop. Med. Hyg.*, 79: 70-74, 1985.
33. SILVA, C. L. & FIGUEIREDO, F. - Tumor necrosis factor in paracoccidioidomycosis patients. *J. infect. Dis.*, 164: 1033-1034, 1991.
34. SOTTO, M. N.; YAMASHIRO-KANASHIRO, E. H.; MATTA, V. L. R. & DE BRITO, T. - Cutaneous leishmaniasis of the New World: diagnostic immunopathology and antigen pathways in skin and mucosa. *Acta trop. (Basel)*, 46: 121-130, 1989.
35. SPECTOR, W. G. & HEESOM, N. - The production of granulomata by antigen-antibody complexes. *J. Path.*, 98: 31-39, 1969.
36. VAN DEUREN, M.; DOFFERHOFF, A. S. M. & VAN DER MEER, J. - Cytokines and the response to infection. *J. Path.*, 168: 349-356, 1992.
37. VAN FURTH, R.; COHN, Z. A.; HIRSCH, J. G. et al. - The mononuclear phagocyte system: a new classification of macrophages, monocytes, and their precursor cells. *Bull. Wld. Hlth. Org.*, 46: 845-852, 1972.
38. WARREN, K. S. - The secret of the immunopathogenesis of schistosomiasis: in vivo models. *Immun. Rev.*, 61: 189-213, 1982.
39. WILLIAMS, G. T. & WILLIAMS, W. J. - Granulomatous inflammation - a review. *J. clin. Path.*, 36: 723-733, 1983.