

## PCR-BASED DIAGNOSIS OF A CASE OF HERPETIC WHITLOW IN AN AIDS PATIENT

Maurício L. NOGUEIRA (1), Adriana F. OLIVEIRA (2), Janaina G. ARAUJO (2), Márcio A. GALLO (2), João G. M. FONSECA (3), Claudio A. BONJARDIM (1), Paulo C.P. FERREIRA (1) & Erna G. KROON (1)

---

### SUMMARY

Herpetic infections are common complications in AIDS patients. The clinical features could be uncommon and antiviral chemotherapy is imperative. A rapid diagnosis could prevent incorrect approaches and treatment. The polymerase chain reaction is a rapid, specific and sensible method for DNA amplification and diagnosis of infectious diseases, especially viral diseases. This approach has some advantages compared with conventional diagnostic procedures. Recently we have reported a new PCR protocol to rapid diagnosis of herpetic infections with suppression of the DNA extraction step. In this paper we present a case of herpetic whitlow with rapid diagnosis by HSV-1 specific polymerase chain reaction using the referred protocol.

**KEYWORDS:** Herpesvirus; PCR; AIDS

---

### INTRODUCTION

Chronic, recurrent or persistent herpetic infections are common complications in HIV infected patients. The clinical manifestations of herpetic infections could be atypical, and failed diagnosis could lead to improper treatment and to complications<sup>2,8</sup>. The herpetic whitlow is a complication in AIDS patient and the severity and time to healing from lesions could be longer than in immunocompetent individuals requiring antiviral therapy<sup>2,9</sup>. Herpetic whitlow usually is present as erythema, vesicular or pustular lesions, fever and lymphadenopathy. In AIDS patients, gangrene and necrosis are common findings with the possibility of autoinoculation of HSV to other sites<sup>9</sup>.

The PCR is a rapid assay, which is more efficient than usual virological methods for diagnosis of some HSV infections. It is more sensitive and specific than the viral isolation or Tzank smear and could be a great methodological tool for the diagnosis of atypical herpetic infections<sup>1,5</sup>. The thymidine kinase (TK) gene of herpesvirus is responsible for the phosphorylation of acyclovir converting it in the active form of the drug. In patients with AIDS the occurrence of acyclovir-resistant herpesvirus is a common finding in patients

receiving a long term acyclovir therapy. In cases of acyclovir-resistance the TK gene is the most common site of mutation and the sequence of this gene could distinguish between sensible and resistant strains, although this procedure is not a common diagnostic method<sup>2,4,7</sup>.

Recently we have reported a PCR protocol to rapid diagnosis of mucocutaneous herpetic infections with suppression of DNA extraction step. This approach have some advantages as the short time to perform the PCR assay, can prevent the contamination of specimens by management and has not organic reagents that could inhibit the assay<sup>6</sup>.

In this paper we describe a case report of herpetic whitlow that was identified by specific HSV-1 PCR using the referred protocol.

### CASE REPORT

A 25-years-old male, homosexual patient, HIV seropositive determined by ELISA and Western blot one year before this case with no clinical manifestation until June, when fever and weight loss were initiated. In October the patient was admitted at the

---

Financial support by FAPEMIG, CNPq and CAPES. EGK, CAB and PCPF are recipients of CNPq fellowships. MLN was recipient of CNPq fellowship and currently has a FAPEMIG fellowship.

(1) Laboratório de Vírus, Departamento de Microbiologia, Instituto de Ciências Biológicas, Universidade Federal de Minas Gerais, Belo Horizonte, MG, Brasil.

(2) Serviço de Clínica Médica, Hospital das Clínicas, Faculdade de Medicina, Universidade Federal de Minas Gerais, Belo Horizonte, MG, Brasil.

(3) Departamento de Clínica Médica, Faculdade de Medicina, Universidade Federal de Minas Gerais, Belo Horizonte, MG, Brasil.

**Correspondence to:** Erna Geessien Kroon, Ph.D. Laboratório de Vírus, Departamento de Microbiologia, Instituto de Ciências Biológicas, Universidade Federal de Minas Gerais. Av. Antonio Carlos 6627. Caixa postal 486. 31270-901 Belo Horizonte, MG, Brasil. Fax: 55-31-443-6482. E-mail: kroone@mono.icb.ufmg.br

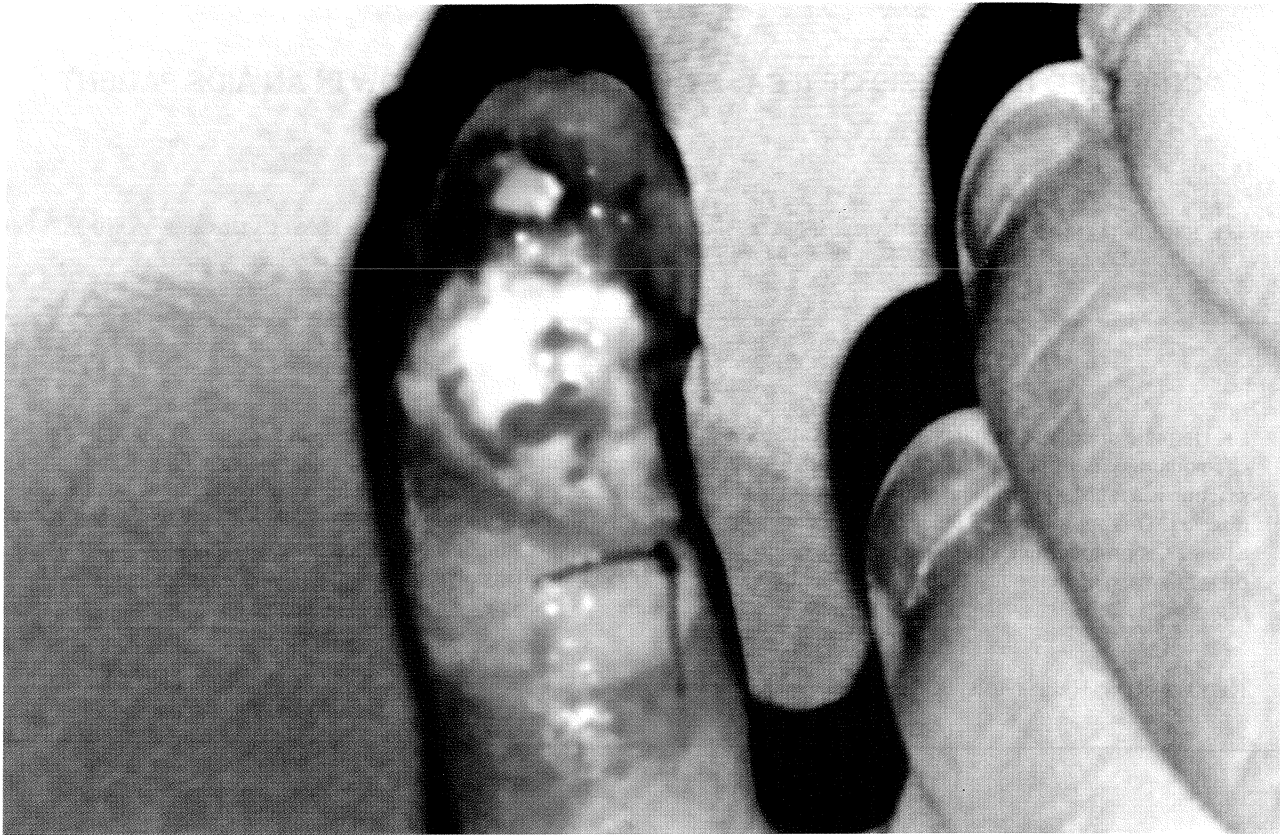


Fig. 1 - Herpetic whitlow at fourth day after admission

Internal Medicine Unit of the Hospital das Clínicas, UFMG, with a diagnosis of *Pneumocystis carinii* infection and necrotic lesions in the finger V of the left hand. Headaches and fever were present too. The lesion was detected one month before, and showed a secondary bacterial infection with no response to topical neomycin plus bacitracin and systemic antibacterial treatment with cefalexine. After admission, sulfamethoxazole-trimethoprim (SMT) therapy initiated, and the finger's lesions developed to necrosis, lost of substance and abundant purulent secretion (Fig. 1). At day three after admission a Tzank smear was performed with no conclusive result. Oral candidiasis was detected and therapy with oral Fluconazol was initiated (200mg daily). The laboratory data showed 20 CD4+ cell/mm<sup>3</sup>, BAAR negative, IgG HCMV 1/3200, HBsAg and anti-HVC were negative. At day four the PCR assay was performed. Briefly the lesion debris was washed out with sterile saline, and a sterile swab cotton was rubbed onto the base of the ulcers and immersed in Eagle's minimal essential medium plus penicillin, amikacin, amphotericin B and 1% fetal bovine serum. Hundred micro-liter was inoculated in Vero cells and no cytopathic effect was detected in 72 hours. The PCR was performed as described by NOGUEIRA et al.<sup>6</sup>. Briefly a tenfold dilution of clinical specimen was submitted to 100°C for 10 min. and 8 µL were used as DNA template. The reaction mixture was as follows: 2mM MgCl<sub>2</sub>, dNTPs (dATP, dCTP, dTTP, dGTP, 1mM each), glycerol (1%), Taq DNA polymerase (PROMEGA®, USA), buffers,

primers (10pM each, HSVTK3 5'TCAGTTAGCCTCCCCCATC and HSVTK5 5'ATGGCTTCGTACCCCTGCC) and template DNA. A known HSV-1 isolate was used as positive control and uninfected medium was used as negative control. PCR amplification was carried out as follows: 35 cycles of one minute at 94°C, 55°C and 72°C, and one cycle of 15 minutes at 72°C. A 1130bp DNA fragment corresponding to the TK gene of HSV-1 was amplified. The amplified product was visualized at agarose gel (1%) stained with ethidium bromide. In order to confirm the specificity of the PCR assay a southern blot was carried out and hybridized with the probe described below. Hybridization and wash conditions were performed according CHURCH & GILBERT method<sup>3</sup>. The DNA fragment containing the HSV-1 TK gene was labeled by "Nick Translation System" (PROMEGA®, USA) and hybridized as expected (data not shown). Oral acyclovir therapy (200mg five times a day) was initiated after PCR amplification. At five days' acyclovir therapy a clinical response was observed and the fever stopped despite the PCR assay was still positive (data not shown). At this time a cranial TC was done and a pansinusitis was detected. Amoxicilin plus clavulanic acid was administered orally for 21 days with resolution of the headaches. After 21 days of oral acyclovir therapy the lesions were resolved and pneumocystis infection also (14 day's SMT therapy). The patient was leaving to out-clinic evaluation and triple anti-retroviral therapy was initiated.

## DISCUSSION

Mucocutaneous herpetic lesions are a common problem in patients with AIDS<sup>2,8,9</sup>. The persistence or recurrence of these herpetic lesions is usually self-limited, however in AIDS patient; the chronic lesions are not uncommon. Although the usual facility to clinical diagnosis of herpetic lesion a rapid complementary assay could prevent improper diagnosis and treatment leading to severe complications like cronication and amputation of a finger with herpetic whitlow. In this report we presented that a rapid PCR-based diagnostic method shows advantages compared to Tzank smears or viral cultures to the diagnosis of herpetic lesions as showed before by NAHASS et al.<sup>5</sup>. The specific, correct and rapid diagnostic of herpetic whitlow could prevent severe complications, inoculation to other sites and equivocal therapy. In AIDS patient with supposed herpetic whitlow or atypical mucocutaneous herpetic lesions, the PCR assay was a good methodological tool for rapid and precise diagnosis.

## RESUMO

### Diagnóstico pela PCR de um caso de paroníquia herpética em um paciente com AIDS.

As infecções herpéticas são complicações comuns em pacientes com AIDS. As manifestações clínicas podem ser incomuns e o tratamento antiviral é imperativo. Um método diagnóstico rápido pode prevenir abordagens e tratamentos incorretos. A reação em cadeia da polimerase (PCR) é um método rápido, sensível e específico para a amplificação de DNA e para o diagnóstico de doenças infecciosas, especialmente as de etiologia viral. Esta abordagem tem vantagens quando comparada com os métodos convencionais de diagnóstico virológico. Recentemente nós relatamos um novo protocolo de PCR para o diagnóstico rápido de infecções herpéticas com supressão da etapa de extração de DNA. Neste trabalho nós apresentamos um caso de paroníquia herpética com diagnóstico através de PCR específico para Herpes Simplex tipo 1 usando o referido protocolo.

## ACKNOWLEDGEMENTS

The authors thank Dr. L.F.L. Reis for critical reading of the manuscript and Ilda M.V. Gamma, Maria A. Souza, Bernadete J. Martins and Angela S. Lopes for technical assistance.

## REFERENCES

1. ASHLEY, R.L. - Herpes simplex viruses. In: LENNETTE, E.H.; LENNETTE, D.A. & LENNETTE, E.T., ed. Diagnostic procedures for viral, rickettsial and chlamydial infections. 7.ed. Washington, American Public Health Association, 1995. p.375-395.
2. CHATIS, P.A.; MILLER, C.H.; SCHRAGER, L.E. & CRUMPACKER, C.S. - Successful treatment with foscarnet of an acyclovir-resistant mucocutaneous infection with herpes simplex virus in a patient with acquired immunodeficiency syndrome. *New Engl. J. Med.*, **320**: 297-300, 1989.
3. CHURCH, G.M. & GILBERT, W. - Genomic sequencing. *Proc. nat. Acad. Sci. (Wash.)*, **81**: 1991-1995, 1984.
4. FIELD, H.J. & GOLDTHORPE, S.E. - The pathogenicity of drug-resistant variants of herpes simplex virus. *Res. Virol.*, **143**: 120-124, 1992.
5. NAHASS, G.T.; GOLDSTEIN, B.A.; ZHU, W.Y. et al. - Comparison of Tzank smear, viral culture and DNA diagnostic methods in detection of herpes simplex and varicella-zoster infection. *J. Amer. med. Ass.*, **268**: 2541-2544, 1992.
6. NOGUEIRA, M.L.; CARVALHO, A.F.; BARBOSA, E.F. et al. - Diagnosis of mucocutaneous herpetic infections by PCR without DNA extraction. *Mem. Inst. Oswaldo Cruz*, **93**: 213-214, 1998.
7. NORRIS, S.A.; KESSLER, H.A. & FITE, K.H. - Severe, progressive herpetic whitlow caused by an acyclovir-resistant virus in patient with AIDS. *J. infect. Dis.*, **157**: 209-210, 1988.
8. QUINNAN, G.V.J.; MASUR, H.; ROOK, A.H. et al. - Herpesvirus infection in acquired immune deficiency syndrome. *J. Amer. med. Ass.*, **252**: 72-77, 1984.
9. WEAVER, G. & KOSTMAN, J.R. - Inoculation herpes simplex virus infections in patients with AIDS: unusual appearance and location of lesions. *Clin. infect. Dis.*, **22**: 141-142, 1996.

Received: 15 April 1998.

Accepted: 13 August 1998.

