

## KERIONLIKE LESION OF THE SCALP DUE TO *ACREMONIUM KILIENSE* IN A NONCOMPROMISED BOY

Jorge O. LOPES (1), Lauro C. KOLLING (1) & Walter NEUMAIER (2)

---

### SUMMARY

We report a case of kerionlike lesion of the scalp due to *Acremonium kiliense* in a boy without underlying disease. Diagnosis was established by direct examination and cultures from pus and scrapings.

**KEYWORDS:** Kerionlike lesion; *Acremonium kiliense*; Noncompromised boy.

---

### INTRODUCTION

Kerion is a severe form of dermatophytosis with deep, suppurant, inflammatory lesions<sup>15</sup>. The infection is rare and is generally caused by the zoophilic dermatophytes *Trichophyton mentagrophytes* var *mentagrophytes* and *T. verrucosum*<sup>19</sup>. These fungi are usually acquired from animals and the disease seen mostly in rural areas. We report an uncommon case of kerionlike lesion of the scalp due to *Acremonium kiliense*, in a boy without underlying disease.

### CASE REPORT

A 4-year-old boy, born and living in the rural area of Mata, Rio Grande do Sul (RS), Brazil, came to Mycology Department of the Santa Maria University with a three months history of a marked inflammatory lesion of the scalp, measuring eight centimeters in diameter, with swelling and hair dislodgement, despite antiinflammatory therapy with antibiotics. The patient was a nourished hygienic boy, without history of underlying disease. The patient's father related that about three months previously, the lesion started by papules, involving simultaneously several adjacent areas, jointed later in a massive acute inflammatory infiltrate, with plaques studded with

pustules. Pus and scrapings collected from the lesion and mounted in 10% potassium hydroxide solution, revealed rare hyaline, septate, 2 to 4 µm in diameter, branching hyphae. No arthroconidia formation was observed. Hair was not infected. Cultures from the pus on Mycobiotic agar (Difco) incubated at 25°C, revealed slow growing downy, white colonies. Hyphae were hyaline, septate, 2 to 4 µm in diameter, with typical *Acremonium* conidiophores bearing nonseptate, straight conidia, characteristic of *A.kiliense* (Fig. 1). The fungus was the unique microorganism isolated from the rest of scrapings on several occasions.

The patient was treated with topic econazole solution and systemic griseofulvin. Surgical intervention was not performed. After one month of treatment the patient returned to the Mycology Department presenting improvement of the lesion, remaining several crusts and alopecia (Fig. 2). Treatment continued to be administered and three months later only a desquamation persisted, with resolution of the alopecia (Fig 3).

### DISCUSSION

Fungi of the genus *Acremonium* are abundant in soil and have been recovered from many cases of mycetoma, onychomycosis and keratitis<sup>25</sup>. Only in a few

---

(1) Departamento de Microbiologia e Parasitologia, Universidade Federal de Santa Maria, RS, Brasil.

(2) Médico Dermatologista, Santa Maria, RS, Brasil

**Correspondence to:** Jorge O. Lopes, Departamento de Microbiologia e Parasitologia, Universidade Federal de Santa Maria, 97119-970 Santa Maria, RS, Brasil.

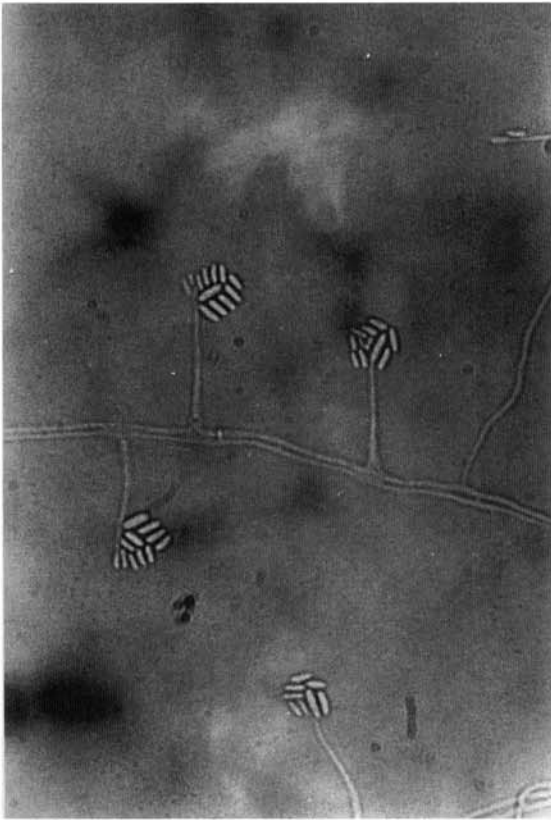


Fig. 1 - *A. kiliense*: conidiophores bearing nonseptate, straight conidia. (Slide culture, x 360).

cases *Acremonium* has been related to deep human infections of traumatic origin or in the compromised host, as pneumonia<sup>1,7</sup>, arthritis<sup>21,24</sup>, midline granulo-

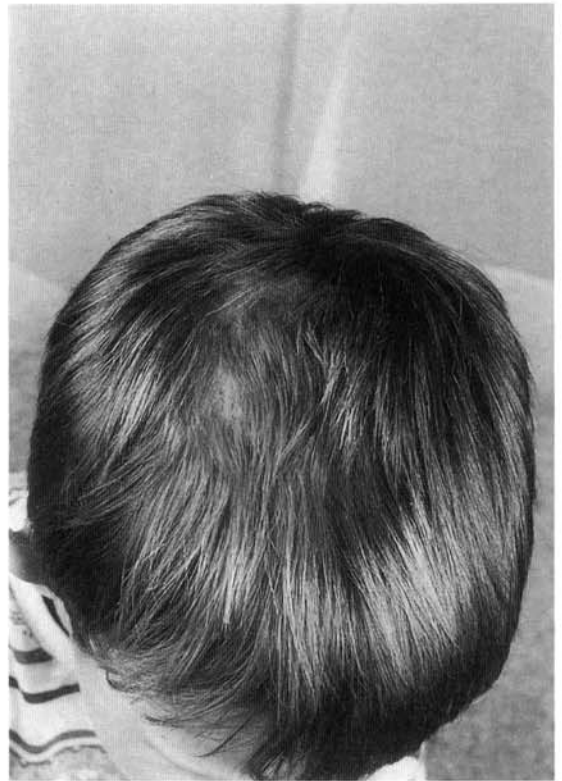


Fig. 3 - Lesion cured after three months of treatment.

ma<sup>5</sup>, meningitis<sup>8,17</sup>, endocarditis<sup>6,12</sup>, cerebritis<sup>27</sup>, osteomyelitis<sup>2</sup> and peritonitis<sup>13</sup>. Two cases of mixed *Acremonium* and *Staphylococcus aureus* infection of hemodialysis fistulae were reported<sup>16</sup>. Onycholysis and subcutaneous nodules involving both forearms due to

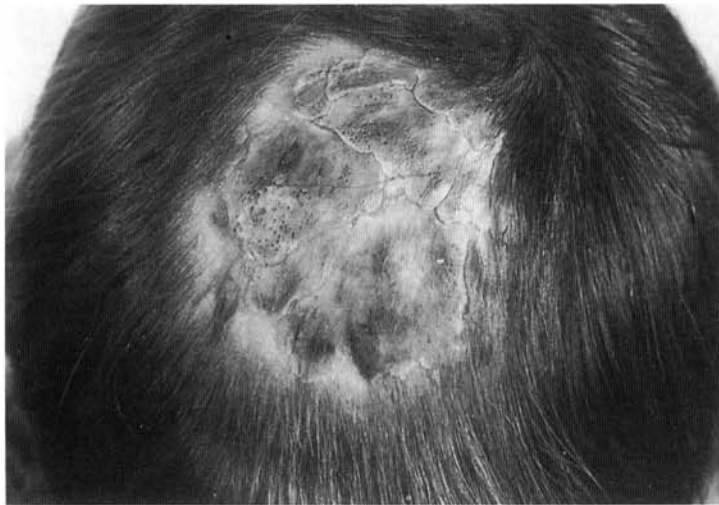

Fig. 2 - Kerionlike lesion of the scalp due to *A. kiliense* after one month of treatment.

*A. falciforme*, were reported in a renal transplant recipient<sup>23</sup>. Subcutaneous abscess was reported in a cardiac transplant recipient<sup>20</sup>.

Dermatomycosis include a variety of diseases in which skin, nails and hair are involved<sup>19</sup>. Only a few soil fungi have been related with human dermatomycosis, and the disease elicited by these fungi is similar to dermatophytosis<sup>3,4,9-11,18,26</sup>. Cutaneous infection due to *A. falciforme* was reported by TEDESCO-MARCHESE et al. in an apparently immunocompetent girl<sup>22</sup>. The lesions appeared as chronic infiltrated scaly erythematous plaques. LONDERO & RAMOS reported a case of *A. falciforme* infection located on intertriginous areas of the foot simulating tinea pedis<sup>14</sup>. A literature review of dermatomycosis has revealed no references as to observation of kerionlike lesion due to *Acremonium*.

## RESUMO

### Lesão tipo quérico do couro cabeludo causada por *Acremonium kiliense* em menino não imunocomprometido.

Relatamos um caso de lesão tipo quérico do couro cabeludo causada por *Acremonium kiliense*, em menino sem doença de base. O diagnóstico foi feito pelo exame direto e cultivos do pus e crostas.

## ACKNOWLEDGEMENTS

Our sincere appreciation is expressed to Dr. Carlos da Silva Lacaz (Laboratório de Micologia Médica, Faculdade de Medicina da USP) for culture identification.

## REFERENCES

1. BOLTANSKY, H.; KWON-CHUNG, K.J.; MACHER, A.M. & GALLIN, J.I. - *Acremonium strictum*-related pulmonary infection in a patient with chronic granulomatous disease. **J. infect. Dis.**, 149:153, 1984.
2. BRABENDER, W.; KETCHERSIDE, J.; HODGES, G.R.; RENGACHARY, S. & BARNES, W.G. - *Acremonium kiliense* osteomyelitis of the calvarium. **Neurosurgery**, 16:554-556, 1985.
3. BUCHVALD, J. - Finding of *Scopulariopsis brevicaulis* (Sacc) Baines 1907, in pathologically changed nails and skin. **Bratisl. lek. Lsty.**, 67:3-8, 1977.
4. COLLINS, N.F. & RINALDI, M.G. - Cutaneous infection in man caused by *Fusarium moniliforme*. **Sabouraudia**, 15:151-160, 1977.
5. COWEN, D.E. & DINES, D.E. - *Cephalosporium* midline granuloma. **Ann. intern. Med.**, 60:731-732, 1964.
6. DEGEORGES, M.; HEINTZ, C.H.; VALTY, J. et al. - Endocardite infectieuse a *Listeria monocytogenes* et a *Cephalosporium*. **Presse méd.**, 79:1377-1380, 1971.
7. DOUGLAS, R. & SYMPSON, S.E. - *Cephalosporium* in pleural fluid. **Amer. Rev. Tuberc.**, 48:237-240, 1943.
8. DROUHET, E.; MARTIN, L.; SEGRETAINE, G. & DESTOMBES, P. - Mycose méningo-cérébrale a *Cephalosporim*. **Presse méd.**, 75:1809-1814, 1965.
9. GENTLES, J.C. & EVANS, E.G.V. - Infection of the feet and nails with *Hendersonula toruloidea*. **Sabouraudia**, 8:72-75, 1970.
10. GIRMENIA, C.; ARCESE, W.; MICOZZI, A. et al. - Onychomycosis as a possible origin of disseminated *Fusarium solani* infection in a patient with severe aplastic anemia. **Clin. infect. Dis.**, 14:1167, 1992.
11. GRUNDER, K. - *Trichosporon capitatum* als Erreger von Dermatomykosen. **Hautarzt**, 27:422-425, 1976.
12. LACAZ, C.S.; PORTO, E.; CARNEIRO, J.J.; PAZIANNI, I.O. & PIMENTA, W.P. - Endocardite em prótese de dura-mater provocada pelo *Acremonium kiliense*. **Rev. Inst. Med. trop. S.Paulo**, 23:274-279, 1981.
13. LANDAY, M.E.; GREENWALD, J.H.; STEMER, A.A. & ASHBACH, D.L. - *Cephalosporium (Acremonium)* in dialysis-connected peritonitis. **J. Indiana med. Ass.**, 75:391, 1982.
14. LONDERO, A.T. & RAMOS, C.D. - Hialohifomicose cutânea por *Acremonium falciforme*. **An. bras. Derm.**, 65:91-92, 1990.
15. ODDS, F.C.; ARAI, T.; DISALVO, A.F. et al. - Nomenclature of fungal diseases: a report and recommendations from a sub-committee of the International Society for Human and Animal Mycology (ISHAM). **J. med. vet. Mycol.**, 30:1-10, 1992.
16. ONORATO, I.M.; AXELROD, J.L.; LORCH, J.A.; BRENSILVER, J.M. & BOKKENHEUSER, V. - Fungal infections of dialysis fistulae. **Ann. intern. Med.**, 91:50-52, 1979.
17. PAPADATOS, C.; PAVLATOU, M. & ALEXIOU, D. - *Cephalosporium meningitis*. **Pediatrics**, 44:749-751, 1969.
18. PEIRIS, S.; MOORE, M.K. & MARTEN, R.H. - *Scytalidium hyalinum* infection of skin and nail. **Brit. J. Derm.**, 106:579-584, 1979.
19. RIPPON, J.W. - Medical mycology. The pathogenic fungi and the pathogenic actinomycetes. 3ed. Philadelphia, W. B. Saunders, 1988.p.169-275.
20. STRABELLI, T.M.W.; UIP, D.E.; BOCCHI, E. et al. - Infecção por *Acremonium* sp após transplante cardíaco. In: CONGRESSO DA SOCIEDADE BRASILEIRA DE MEDICINA TROPICAL, 26, 1990.p.302-303.
21. SZOMBATHY, S.P.; CHEZ, M.G. & LAXER, R.M. - Acute septic arthritis due to *Acremonium*. **J. Rheum.**, 15:714-715, 1988.
22. TEDESCO-MARCHESE, L.C.M.; CASTRO, R.M.; LACAZ, C.S. et al. - Acremoniose cutânea. Registro de um caso. **An. bras. Derm.**, 62:25-30, 1987.
23. VAN ETTA, L.L.; PETERSON, L.R. & GERDING, D.N. - *Acremonium falciforme (Cephalosporium falciforme)* mycetoma in a renal transplant patient. **Arch. Derm.**, 119:707-708, 1983.
24. WARD, H.P.; MARTIN, W.J.; IVINS, J.C. & WEED, L. - *Cephalosporium* arthritis. **Proc. Mayo Clin.**, 36:337-343, 1961.
25. WARNOCK, D.W. & JOHNSON, E.M. - Clinical manifestations and management of hyalohyphomycosis, phaeo-ophomycosis and other uncommon forms of fungal infection in the compromised patient. In: WARNOCK,

- D.W. & RICHARDSON, M.D. Fungal infection in the compromised patient. 2ed. West Sussex, John Wiley & Sons, 1991.p. 247-310.
26. WEITZMAN, I. - Saprophytic molds as agents of cutaneous and subcutaneous infections in patients with cancer. **Rev. infect. Dis.**, 11:369-378, 1989.
27. WETLI, C.V.; WEISS, S.D.; CLEARY, T.J. & GYORI, E. - Fungal cerebritis from intravenous drug abuse. **J. forens. Sci.**, 29:260-268, 1984.

Recebido para publicação em 04/01/1995

Aceito para publicação em 26/01/1995