

Apical internal inflammatory root resorption and open apex treated with MTA: a case report

Reabsorção apical inflamatória interna e ápice aberto tratado com MTA: relato de caso

Abstract

Purpose: Internal inflammatory root resorption is a rare condition, characterized by progressive loss of tooth substance which starts on the root canal wall. Usually the process is asymptomatic and diagnosed upon routine radiographic examination. The following report shows the treatment of a case of periapical lesion and apical internal resorption that reached the external root surface.

Case description: A 16 year-old male was referred for a routine dental treatment for oral rehabilitation. Radiographic examination showed a resorptive lesion in the apical third and periapical lesion on tooth 21. Crown down preparation was performed and calcium hydroxide was placed for 2 weeks. An apical plug with white MTA was condensed into the resorption cavity and then the canal was obturated with gutta-percha and AH Plus sealer. The follow-up radiographs showed satisfactory resolution.

Conclusion: This report showed the results of the treatment with MTA apical plug. The technique avoided an invasive procedure and presented some advantages, like materials biological properties and capable of sealing.

Key words: Root resorption; dental trauma; inflammatory root resorption; MTA; calcium hydroxide

Resumo

Objetivo: A reabsorção radicular interna inflamatória é uma condição rara caracterizada por progressiva perda de substância dentária, que se inicia nas paredes do canal radicular. Geralmente o processo é assintomático e diagnosticado em exame radiográfico de rotina. O presente relato de caso mostra o tratamento de um caso de lesão periapical e reabsorção interna apical que atingiu a superfície radicular externa.

Descrição do caso: Um paciente do sexo masculino de 16 anos foi encaminhado para tratamento odontológico de rotina para reabilitação oral. O exame radiográfico mostrou uma lesão de reabsorção no terço apical e lesão periapical no dente 21. O preparo coronário foi realizado e hidróxido de cálcio foi colocado por duas semanas. Um tampão com MTA branco foi condensado na cavidade da reabsorção e então o canal foi obturado com guta-percha e cimento AH Plus. As radiografias de acompanhamento mostraram resolução satisfatória.

Conclusão: Este caso mostrou os resultados do tratamento com tampão apical de MTA. A técnica evitou um procedimento invasivo e apresentou algumas vantagens, tais como propriedades biológicas dos materiais e capacidade de selamento.

Palavras-chave: Reabsorção óssea; trauma dentário; reabsorção radicular inflamatória; MTA; hidróxido de cálcio

Débora Franzon Brun^a
Roberta Kochenborger Scarparo^b
Patrícia Maria Poli Kopper^a
Fabiana Soares Grecca^a

^a Department of Conservative Dentistry, Dental School of Federal University of Rio Grande do Sul, Porto Alegre, Brazil

^b Graduate program in Dentistry, Pontifical Catholic University of Rio Grande do Sul, Porto Alegre, RS, Brazil

Correspondence:

Fabiana Soares Grecca
Avenida Ramiro Barcelos, 2492
Porto Alegre, RS – Brazil
90035-003
E-mail: fakera@terra.com.br

Received: July 6, 2009

Accepted: December 10, 2009

Conflict of Interest Statement: The authors state that there are no financial and personal conflicts of interest that could have inappropriately influenced their work.

Copyright: © 2010 Brun et al.; licensee EDIPUCRS. This is an Open Access article distributed under the terms of the Creative Commons Attribution-Noncommercial-No Derivative Works 3.0 Unported License.

Introduction

Internal inflammatory root resorption is a rare condition characterized by progressive loss of tooth substance which starts on the root canal wall. It is caused by a transformation of the normal pulp tissue into granulomatous tissue with giant cells which resorb the dentin (1). Internal resorption appears radiographically as a uniform, round-to-oval radiolucent enlargement of the canal. In most cases it is asymptomatic and detected on radiographic screening. It is frequently observed in the cervical region, though it may occur in different areas of root canal system (2).

The exact cause of internal root resorption is unknown in most cases, but it is known that its progression depends on vital tissue, being immediate root canal treatment required for these cases (1,2). The irregular confines of the resorptive cavity interpose technical difficulties for thorough debridement and obturation (1,3). This problem becomes even more evident when resorption is located in a region to which access is difficult, being surgical intervention necessary in many cases. When internal resorption reaches the external root surface, root integrity is lost and destruction of the adjacent periodontal tissues may occur, as well as pulp necrosis (3).

Mineral trioxide aggregate (MTA) is a material for perforation repair that has offered many favorable properties, including good sealing ability (4), biocompatibility (5), radiopacity (6), and moisture resistance. Those properties have promoted the use of MTA for sealing purposes in cases of perforation (7) and internal root resorption (8-9).

Although its properties are well described in the literature, MTA has not been employed very frequently in the treatment of internal root resorption. This report showed the results of the non-invasive treatment with MTA apical plug.

Case Description

A 16-year-old male was referred to the Dental School of the Federal University of Rio Grande do Sul because of a dental trauma suffered 5 years before. Clinical examination revealed coronal fracture on tooth 21, which was slightly tender to percussion. All the teeth in this quadrant responded normally to cold testing except 21, which was unresponsive. A resorptive lesion in the apical third and thickening of the periodontal ligament space was discovered on a periapical radiograph (Fig. 1A).

Based on the clinical and radiographic findings, root canal therapy was initiated. The rubber dam was placed and tooth was accessed without anesthesia. Crown-down preparation was performed with K-Files (Maillefer Dentsply, Baillaigues, Switzerland) and Gates Glidden Burs (Maillefer Dentsply, Baillaigues, Switzerland) (Fig. 1B). During preparation the canal was irrigated with 2.5% sodium hypochlorite. A final rinse with 17% EDTA (Biodinâmica, Ibiporã, Paraná, Brazil), to remove the smear layer, was performed.

Hemorrhage and exudate from the apical region was observed during the instrumentation, which suggested resorption

exteriorization. Calcium hydroxide (Calen, SS White, São Cristóvão Rio de Janeiro, Brasil) was used for dressing (Fig. 1C) and a temporary glass ionomer cement filling (Ketac-Fil; 3M Espe, Seefeld, Germany) was applied.

The calcium hydroxide paste was removed 2 weeks later. White MTA (Maillefer Dentsply, Baillaigues, Switzerland) was condensed into the resorption cavity, by the means of a 5-mm apical plug (Fig. 1D). After seven days, the canal was obturated using lateral condensation (Fig. 1E).

After 6 months, the periapical lesion showed signs of resolution (Fig. 1F). The post core preparation, cementation of intra radicular post and restoration were performed. After 1 year, the patient was recalled, and the tooth was found to be symptom free. No percussion sensitivity was observed. The periapical radiograph showed a satisfactory image (Fig. 1G and 1H).

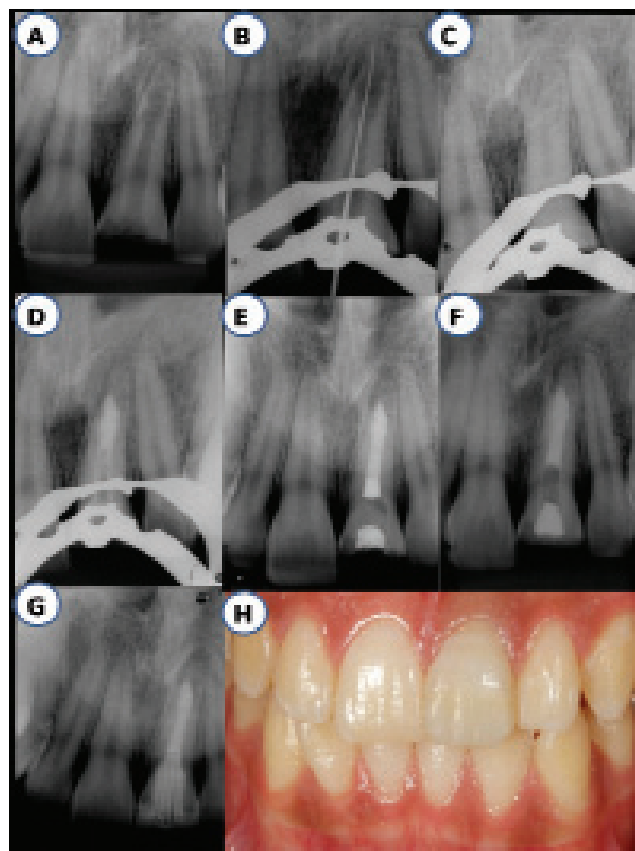


Fig. 1. (A) Radiographic aspects of apical third root resorption observed in the tooth (21). (B) Crown-down technique performed. (C) Root canal filled with calcium hydroxide dressing. (D) MTA condensed into the apical resorption cavity after 14 days. (E) Canal filled using lateral condensation. (F) Six-month follow-up. (G, H) One-year follow-up: radiographic and clinical aspects.

Discussion

According to Andreassen & Andreassen (1), internal resorption is a rare finding in permanent traumatized teeth, with approximately 2% of them showing clinical signs of this type of resorption. Internal resorptions on the apical third of root canal are even more rare and bring along with them technical difficulties.

When this is the case, MTA presents some advantages. One of them is its physical characteristics which guarantees expansion during the attachment, which favor sealing (4) and the maintenance of biological properties presented by calcium hydroxide. MTA forms calcium oxide when in contact with water, which, when in contact with the tissues fluids, forms calcium hydroxide and triggers the same repair process in tissues (5).

MTA has been proved good for solving the problems derived from perforation, as it does not interfere in the presence of

moisture and inhibits the activity of bacteria (3). On the other hand, MTA characteristics make deobturation difficult when it is necessary to use intraradicular retentor. For this reason we decided to build the apical plug (10). Hachmeister et al. (11) reported that a 5-mm apical plug is appropriate to prevent infiltration of fluids in the canal.

It is worth noting that the time the material was attached varied between 75 minutes to 4 hours (4). Due to this particular aspect, the canal was obturated in another working session. The use of calcium hydroxide proved to be an effective aid in addition to the mechanical instrumentation because its tissue-dissolving effect allowed the remaining tissue to be flushed away (12-14). The case presented here was a successful one, both clinically and radiographically. There was healing of the radiolucency in the alveolar bone and further pathologic features were not identified. After 1 year, the tooth remained asymptomatic.

References

1. Andreasen JO, Andreasen FM. Textbook and color atlas of traumatic injuries to the teeth. 3th ed. St. Louis: Munksgaard & Mosby; 1994. p.370-2.
2. Ne RF, Witherspoon DE, Gutmann JL. Tooth resorption. Quint Int 1999;30:9-25.
3. Keinan D, Heling I, Stabholtz A, Moshonov J. Rapidly progressive internal root resorption: a case report. Dent Traumatol 2008; 24:546-9.
4. Torabinejad M, Hong CU, McDonald F, Pitt Ford TR. Physical and chemical properties of a new root end filling material. J Endod 1995;21:349-53.
5. Holland R, de Souza V, Nery MJ, Faraco Jr IM, Bernabé PFE, Otoboni Filho JA, et al. Reaction of rat connective tissue to implanted dentin tube filled with mineral trioxide aggregate, Portland cement or calcium hydroxide. Braz Dent J 2001;12:3-8.
6. Leites AC, Figueiredo JAP, Demarco FF, Basso AP, Piva E. Radiopacity of the modified Portland cement in comparison with MTA. Rev Odonto Ciênc 2008;23:145-9.
7. Main C, Mirzayan N, Shabahalang S, Torabinejad M. Repair of root perforations using mineral trioxide aggregate: a long-term study. J Endod 2004;30:80-3.
8. Jacobovitz M, de Lima RKP. Treatment of inflammatory internal root resorption with mineral trioxide aggregate: a case report. Int Endod J 2008;41:905-12.
9. Hsien HC, Cheng Y, Lee Y, Lan W, Lin C. Repair of perforating internal resorption with mineral trioxide aggregate: a case report. J Endod 2003;29:538-9.
10. Stefopoulos S, Tsatsas DV, Kerezoudis NP, Eliades G. Comparative in vitro study of the sealing efficiency of white vs grey ProRoot mineral trioxide aggregate formulas as apical barriers. Dent Traumatol 2008;24:207-13.
11. Hachmeister DR, Schindler WG, Walker WA III, Thomas DD. The sealing ability and retention characteristics of mineral trioxide aggregate in a model of apexification. J Endod 2002;28:386-90.
12. Turkun M, Cengiz T. The effects of sodium hypochlorite and calcium hydroxide on tissue dissolution and root canal cleanliness. Int Endod J 1997;30:335-42.
13. Estrela C, Decurcio DA, Alencar AHG, Sydney GB, Silva JA. Efficacy of calcium hydroxide dressing in endodontic infection treatment: a systematic review. Rev Odonto Ciênc. 2008;23:82-86.
14. Ferreira R, Santos R, Wagner M, Dotto SR, Travassos RMC. Avaliação da ação antimicrobiana de diferentes medicações usadas em endodontia. Rev Odonto Ciênc 2006;21:266-9.