

Delayed tooth eruption in an adolescent with hypothyroidism

Atraso na erupção dental em adolescente com hipotireoidismo

Retardo en la erupción dental en adolescentes con hipotiroidismo

Maria Sylvia de S. Vitalle¹, Rosa Maria E. Weiler², Sheila Rejane Niskier³, Josefina Aparecida P. Braga⁴

ABSTRACT

Objective: To report the case of an adolescent with undiagnosed hypothyroidism who sought dental clinic care due to delayed tooth eruption. Multiprofessional work enabled the diagnosis.

Case description: This is a 16 years and 4 month-old patient whose initial complaint was delayed tooth eruption. Dental evaluation drew attention to the significant delay in tooth eruption as it could be related to organic diseases. This has prompted the intervention of medical professionals who diagnosed hypothyroidism in the follow-up.

Comments: Teenagers typically value acceptance by their peers and may have aesthetic concerns that lead them to seek health services for seemingly trivial complaints. A high degree of surveillance in these cases can detect more serious underlying organic problems. We highlight the importance of the multidisciplinary team in this approach.

Key-words: hypothyroidism; tooth eruption; adolescent; adolescent health.

RESUMO

Objetivo: Relatar o caso de adolescente que procurou serviço odontológico de um ambulatório de medicina do adolescente por apresentar atraso de erupção dentária. A atuação multiprofissional permitiu chegar ao diagnóstico de hipotireoidismo.

Descrição do caso: Paciente de 16 anos e 4 meses cuja queixa inicial foi atraso na erupção dentária. Na avaliação odontológica, chamava atenção o importante atraso na erupção dentária, o que poderia estar relacionado a alguma moléstia orgânica. Desta forma, solicitou-se a intervenção da equipe médica, que, no acompanhamento, constatou se tratar de hipotireoidismo.

Comentários: Chama-se a atenção o fato de que adolescentes prezam a aceitação pelos seus pares e as questões estéticas e, muitas vezes, a procura por um serviço de saúde envolve queixas que podem parecer triviais. Porém, o olhar atento não deixará que problemas orgânicos mais graves passem despercebidos. Salienta-se ainda a importância da atuação da equipe multiprofissional.

Palavras-chave: hipotireoidismo; erupção dentária; adolescente; saúde do adolescente.

RESUMEN

Objetivo: Relatar caso de adolescente que buscó servicio odontológico de un ambulatorio de medicina del adolescente, por presentar retardo en la erupción dental y cuya actuación multiprofesional permitió llegar al diagnóstico de hipotiroidismo.

Descripción del caso: Se describe la historia de una paciente de 16 años y 4 meses de edad cuya queja fue retardo en la erupción dental. En la evaluación odontológica, llamaba

Instituição: Setor de Medicina do Adolescente do Departamento de Pediatria da Universidade Federal de São Paulo (Unifesp), São Paulo, SP, Brasil

¹Doutora em Medicina pela Unifesp; Professora Permanente do Programa de Pós-graduação em Educação e Saúde na Infância e Adolescência na Unifesp; Chefe do Setor de Medicina do Adolescente (Centro de Atendimento e Apoio ao Adolescente – CAAA) do Departamento de Pediatria da Unifesp, São Paulo, SP, Brasil

²Doutora em Ciências pela Unifesp; Dentista Assistente do Setor de Medicina do Adolescente, Departamento de Pediatria da Unifesp, São Paulo, SP, Brasil

³Mestre em Pediatria pela Unifesp; Médica de Adolescente pela Sociedade Brasileira de Pediatria; Médica Assistente do CAAA; Unifesp, São Paulo, SP, Brasil

⁴Doutora em Medicina pela Unifesp; Chefe do Setor de Hematologia Infantil, Departamento de Pediatria, Unifesp, São Paulo, SP, Brasil

Endereço para correspondência:

Rosa Maria E. Weiler
Rua Botucatu, 715 – Vila Clementino
CEP 04023-062 – São Paulo/SP
E-mail: reid@uol.com.br

Conflito de interesse: nada a declarar

Recebido em: 10/10/2011

Aprovado em: 6/2/2012

la atención el importante retardo en la erupción dental, lo que podría estar relacionado a alguna enfermedad orgánica. De este modo, se solicitó la intervención del equipo médico que, en el seguimiento, constató tratarse de hipotiroidismo.

Comentarios: Se llama la atención para el hecho de que adolescentes estiman mucho la aceptación por sus pares y las cuestiones estéticas y, muchas veces, la búsqueda por un servicio de salud implica quejas que pueden parecer comunes, pero una mirada atenta no dejará que problemas orgánicos más graves pasen desapercibidos. Se subraya además la importancia de la actuación del equipo multiprofesional.

Palabras clave: hipotiroidismo; erupción dental; adolescente; salud del adolescente.

Introduction

Even though the regulatory effects of thyroid hormones on bone development and metabolism have been known for a long time, the mechanisms of thyroid hormone action on the skeleton are still a matter of debate⁽¹⁻³⁾. Along this line, even though there are reports of delayed tooth eruption in the literature, this condition is an unlikely patient complaint, and it is seldom recorded during clinical examination, possibly because physicians generally have difficulty making this assessment, or because it is not seen as a sign of severe disease. However, the possibility of hypothyroidism should be suspected when evaluating adolescents with delayed dentition, and both physicians and dentists should be aware of this clinical manifestation of hypothyroidism.

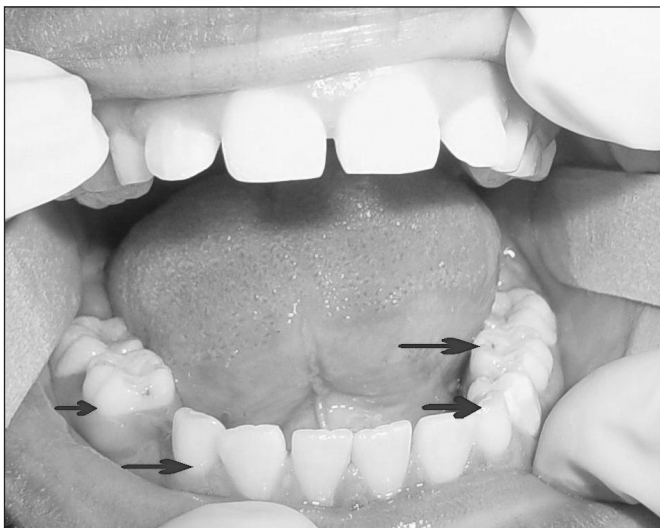


Figure 1 - Presence of primary teeth - fist appointment

The expression “tooth eruption” is usually understood as the simple appearance of teeth in the oral cavity. However, it comprises the entire occlusion path until the tooth reaches its final position in the oral cavity. Thyroid hormones interfere the most with the process of eruption, and also have a structural impact on developing teeth⁽⁴⁾.

The aim of this study is to report a case of hypothyroidism in a female who sought treatment for delayed tooth eruption⁽⁵⁾ in a multidisciplinary adolescent medicine service.

Case description

A female teenager, aged 16 years and four months, was evaluated at the Federal University of São Paulo (Unifesp) Department of Pediatrics/Adolescent Medicine Service/Oral Health Division. She complained of having delayed dentition, which bothered her because it made her look different from her friends. After initial evaluation, she was referred to the medical service for joint workup. Dental evaluation revealed marked delay in tooth eruption. She had deciduous canines, second molars, and first two upper molars. Moreover, the permanent second molars (which erupt around age 12) had not yet erupted (Figure 1). A panoramic radiograph (Figure 2) showed neither anodontia of permanent nor supernumerary teeth. The roots of unerupted permanent teeth were fully formed, and the roots of deciduous predecessors showed no signs of resorption, indicating an imbalance between the processes of deciduous root resorption and root formation in permanent teeth. Dental age was estimated at 15.6 years with a panoramic radiograph using the method described by Demirjian⁽⁶⁾.

During the medical appointment, the patient reported treatment with ferrous sulfate due to anemia for a year, without improvement. She also described constipation and growth delay⁽⁷⁾. Delayed dentition and growth were noted from the age of six. Her age at menarche was 12, and she had regular menstrual cycles. At evaluation, pubertal development was M3P3, height 150cm (5th percentile), weight=54.6kg (25–50th percentile), body mass index (BMI) 24.1kg/m² (90–95th percentile). The following tests were performed: thyroid hormone dosage, complete blood count, hemoglobin electrophoresis, osmotic fragility curve, and wrist x-ray for bone age. Thyroid hormone levels were compatible with hypothyroidism: TSH>7.5μUI/mL (reference: 0.4–4.0); free T4<0.3ng/dL (0.8–2.0). Blood test results were: hemoglobin 9.3g/dL (12.0–15.5); hematocrit 28.2% (35.0–45.0); MCV 89fl

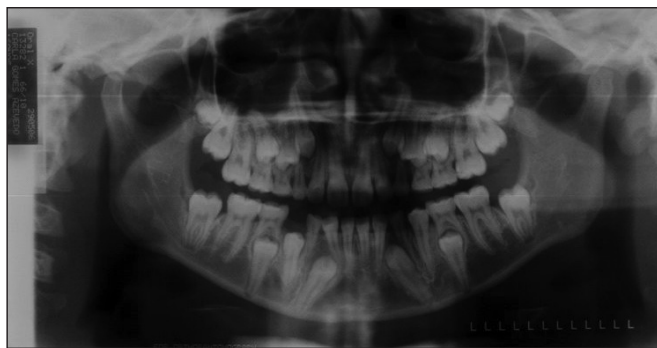

Figure 2 - Panoramic radiograph

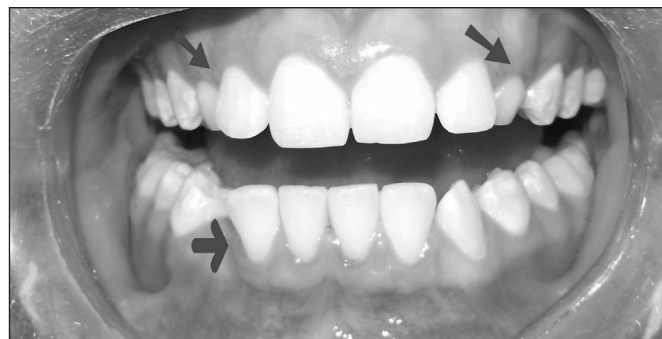

Figura 3 - Erupted permanent teeth and enamel defects in late erupted teet

(82.0–98.0); MCH 30 (26.0–34.0); white cells (3500–10500) 4640/mm³ (39S/1E/2.6B/49.3L/7.6M); platelet count 236000/mm³ (150000–450000). Serum iron level was 24mcg/dL (37–170), and ferritin 58ng/mL (11–307). Hemoglobin electrophoresis and osmotic fragility curve were normal. Wrist x-ray revealed bone age of 13 years with chronological age of 16 years according to the Greulich-Pyle Atlas, with a standard deviation of -3.1. She was then referred to the endocrinology department for treatment and follow-up.

The proposed dental treatment included serial extraction of primary teeth in the order of eruption (lower canines, first premolars, second premolars, and upper canines) after the start of levothyroxine replacement therapy to prevent loss of eruptive force. Extractions were planned to be performed after eruption of adjacent teeth, to keep the dental arch space from closing (Figure 3).

This report was approved by the Ethics Committee of the Universidade Federal de São/Hospital São Paulo, with protocol No. 0395/11.

Discussion

Prolonged retention of primary teeth may result from absence of permanent successors (permanent canines and premolars), presence of supernumerary teeth, which prevents the formation of a corridor for successor tooth eruption, ankylosis of primary teeth, and from hormonal changes⁽⁸⁾, including hypothyroidism, severe forms of hypopituitarism, and in syndromes such as trisomy 21, cleidocranial dysplasia, and Hurler syndrome^(9,10).

The process of tooth eruption is not fully understood. However, four mechanisms of action have been recognized⁽¹¹⁾: 1) root formation, a stage in which the growing root is accommodated by intrasosseous movement of the tooth crown

and resorption of the deciduous predecessor root; 2) hydrostatic pressure in the periapical tissue, pushing the tooth occlusally; 3) bone remodeling; and 4) occlusal tooth movement promoted by periodontal ligament cells and fibers.

The process of primary tooth resorption is not continuous, but rather interspersed with periods of repair. In vitro and in vivo studies show that odontoclasts play a central role in primary tooth resorption and form a path for permanent teeth⁽¹²⁾. It is important to determine the factors regulating physiological resorption. Odontoclasts and osteoclasts were initially thought to be similar in structure and histochemistry, but some differing properties have been recognized. For example, collagenase is expressed in odontoclasts, but not in osteoclasts, whereas parathyroid hormone enhances osteoclastic resorption, but does not affect odontoclastic resorption⁽¹³⁾.

T lymphocytes produce receptor activator of nuclear kappa B ligand (RANKL), a cytokine that belongs to the family of tumor necrosis factors and plays an important role in the regulation of bone cell and bone mass biology. Periodontal ligament cells secrete osteoprotegerin (OPG), another cytokine, which inhibits osteoclastogenesis. RANKL activates its specific RANK receptor, which is located in osteoclasts, inducing the formation and activation of these resorption cells. However, as OPG binds to RANKL, it blocks osteoclast activity and differentiation⁽¹⁴⁾. The balance between stimulatory (RANKL) and inhibitory (OPG) effects might regulate odontoclastogenesis, since ligament cells derived from primary roots during the physiological resorption process express increased levels of RANKL. In contrast, during the phases that precede resorption, the ligament expresses OPG, and not RANKL⁽¹⁵⁾. The RANKL/OPG system is regulated by several hormones (growth hormone, thyroid hormones, glucocorticoids, estrogens), vitamin D and cytokines (interleukin 1, 4, 6, 11, 17 and TNF delta).

Thyroid hormones have receptors in all tissues, with effects that include increased synthesis and degradation of proteins, increased glycogen levels, as well as enhanced lipolysis and glucose utilization. Furthermore, thyroid hormones regulate mucoproteins and extracellular water, and they are required for vitamin A formation and for synthesis of growth hormone, neural growth factor, and myelin proteins⁽¹⁶⁾. They are involved in myocardial contractility, central nervous system activity, nerve growth factor (NGF) synthesis, muscle contraction processes, intestinal motility, and tooth development and eruption⁽¹⁷⁾.

Clinical complaints are more frequent in patients with subclinical hypothyroidism than in those with euthyroidism, and less frequent than in those with overt hypothyroidism⁽¹⁸⁾. The delay in tooth development (in terms of tooth formation stages, not eruption) is less pronounced than bone age delay,

and the therapeutic response is also less intense. There are no changes in the number, size or shape of teeth. However, if the disease occurs during mineralization, tooth enamel will be permanently mottled (Figure 3)^(2,3).

The delay in tooth eruption, although reported in the literature, is rarely considered during the physical examination, and is often dismissed as a complaint and rarely considered for the differential diagnosis of hypothyroidism. It is therefore recommended that health care professionals pay attention to this clinical sign, which should be monitored by a multidisciplinary team. In the context of the teenager need for peer approval^(19,20), aesthetic considerations are of great importance. Some of the complaints driving teenagers to seek health care may seem trivial, but a watchful eye will not miss the need to investigate and diagnose an underlying organic problem.

References

- Gouveia CH. O efeito molecular e estrutural do hormônio tireoideano no esqueleto. *Arq Bras Endocrinol Metab* 2004;48:183-95.
- Setian N. Hipotireoidismo. *Pediatria (São Paulo)* 1981;3:108-19.
- Teixeira FS, Campos V, Mitchell C, Carvalho LM. Retenção prolongada de molares decíduos: diagnóstico, etiologia e tratamento. *R Dental Press Ortodon Ortop Facial* 2005;10:125-37.
- Pirinen S. Endocrine regulation of craniofacial growth. *Acta Odontol Scand* 1995;53:179-85.
- Levin HL. Some dental aspects of endocrine diseases. *Oral Surg Oral Med Oral Pathol* 1965;19:466-77.
- Demirjian A, Goldstein H, Tanner JM. A new system of dental age assessment. *Hum Biol* 1973;45:211-7.
- Weiler RM, Vitalle MS, Niskier SR, Braga JA, Niskier SR. Importância da Abordagem Multiprofissional: Atraso na Erupção em Adolescente Apresentando Hipotireoidismo. Proceedings of the X Congresso Brasileiro de Adolescência; 2007 Sep 27-30; Foz do Iguaçu, Paraná, p. 96.
- Haralabakis NB, Yiagtzis SC, Toutountzakis NM. Premature or delayed exfoliation of deciduous teeth and root resorption and formation. *Angle Orthod* 1994;64:151-7.
- Bernstein L, Keyes KS. Abnormalities of the teeth and their supporting structures. *Otolaryngol Clin North Am* 1972;5:249-72.
- Berthold TB, Araujo VP, Robinson WM, Hellwig I. Síndrome de Down: aspectos gerais e odontológicos. *Rev Cienc Med Biol* 2004;3:252-60.
- Ten Cate AR. *Oral histology: development, structure and function*. 5 ed. St Louis: Mosby; 1998.
- Oguchi H. In vitro studies of bone resorption by the root-resorbing tissue from the bovine deciduous tooth. *Bull Tokyo Med Dent Univ* 1975;22:175-83.
- Freilich LS. Ultrastructure and acid phosphatase cytochemistry of odontoclasts: effects of parathyroid extract. *JDR* 1971;50 (Suppl 5):1046-55.
- Hofbauer LC, Heufelder AE. Role of receptor activator of nuclear factor-kappaB ligand and osteoprotegerin in bone cell biology. *J Mol Med (Berl)* 2001;79:243-53.
- Fukushima H, Kajiya H, Takada K, Okamoto F, Okabe K. Expression and role of RANKL in periodontal ligament cells during physiological root-resorption in human deciduous teeth. *Eur J Oral Sci* 2003;111:346-52.
- Setian NS. Hypothyroidism in children: diagnosis and treatment. *J Pediatr (Rio J)* 2007;83 (Suppl 5):S209-16.
- Navarro Despaigne DA. Interrelación entre hormonas tiroideas y crecimiento: importancia clínica. *Rev Cubana Endocrinol [serial on the Internet]*. 2005;16 [cited 2010 Oct 05]. Available from: http://scielo.sld.cu/scielo.php?script=sci_abstract&pid=S1561-29532005000300007&lng=es&nrm=iso&tlng=es
- Teixeira PF, Reuters VS, Almeida PC, Ferreira MM, Wagman MW, Reis AF *et al*. Avaliação clínica e de sintomas psiquiátricos no hipotireoidismo subclínico. *Rev Assoc Med Bras* 2006;52:222-8.
- Vitalle MS, Schoen-Ferreira TH, Weiler RM, Freire SC, Rodrigues AM, Vertematti S *et al*. Adolescent Medicine Division (Adolescent Medical Support Service Center CAAA) of Federal University of São Paulo: a multiprofessional and interdisciplinary experience – The Commitment to Adolescent. *Adolesc Saude* 2010;7:13-20.
- Schoen-Ferreira TH, Aznar-Farias M, Silveiras EF. Adolescence through the Centuries. *Psic Teor Pesq* 2010;26:227-34.