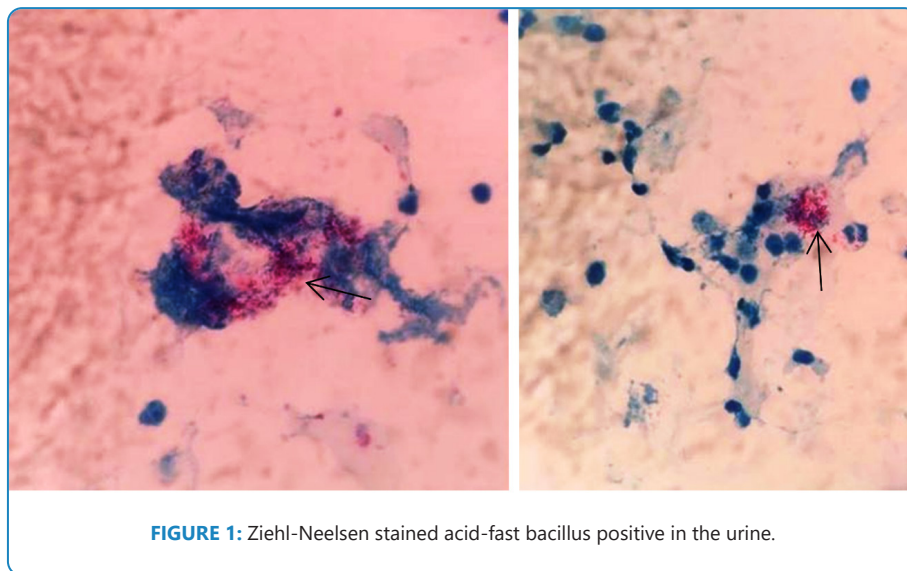


Images in Infectious Diseases

Genitourinary Tuberculosis, not Lupus

Matheo Augusto Morandi Stumpf¹ 

[1]. Universidade Estadual de Ponta Grossa, Ponta Grossa, PR, Brasil.



A 72-year-old woman presented with macroscopic hematuria for the past 2 weeks and weight loss within 6 months. She had cutaneous discoid lupus for 10 years and was taking hydroxychloroquine 400 mg daily. She denied having arthritis, dysuria, pollakiuria, or fever. She was initially diagnosed with lupus nephritis. The literature has well documented that some patients with cutaneous lupus may progress to systemic disease during follow-up¹. However, admission examinations showed normal complement, negative antinuclear antibodies, elevated inflammatory markers, and no dysmorphic hematuria. The urine contained 22,000 leukocytes/mL and 80,000 erythrocytes/mL. Although she had no urinary symptoms, we collected a urine sample for culture, which was negative. On the third day of hospitalization, she had a vespertine fever (38 °C). Tuberculosis was suggested as a differential diagnosis when confronted with urine containing "sterile" leukocyturia. The Ziehl-Neelsen stained

acid-fast bacillus (AFB) was positive in the urine (arrows in **Figure 1**), and *Mycobacterium tuberculosis* culture was positive. Computed tomography and ultrasonography of the genitourinary tract were normal. The patient was discharged on rifampicin, isoniazid, pyrazinamide, and ethambutol. Unfortunately, the patient died of a perforated peptic ulcer after 2 months.

Patients receiving immunosuppressive therapy are more likely to develop this condition. For diagnosis, AFB culture in Lowenstein Jensen medium, and polymerase chain reaction in urine can be used². However, a positive urine AFB test is not diagnostic for tuberculosis since non-tuberculous mycobacteria may be present; moreover, its sensitivity is limited, approximately 40%³.

Written informed consent was obtained from the patient for publishing this material.

Corresponding author: Matheo Augusto Morandi Stumpf. **e-mail:** matheoaugusto@hotmail.com

Authors' contribution: MAMS wrote the manuscript and reviewed the final version of the manuscript.

Conflict of Interest: The author declares that there is no conflict of interest.

Financial Support: This study was not funded by any company.

REFERENCES

1. Wieczorek IT, Propert KJ, Okawa J, Werth VP. Systemic symptoms in the progression of cutaneous to systemic lupus erythematosus. *JAMA Dermatol.* 2014;150(3):291-6.
2. Almeida APF, Silva DFD, Petruccelli KCS, Matos JDC, Moreira RX, Cordeiro-Santos M. Urogenital tuberculosis in a patient with end-stage renal disease. *Rev Soc Bras Med Trop.* 2020;53:e20190284.
3. Lee JY, Park HY, Park SY, Lee SW, Moon HS, Kim YT, Lee TY, Park HY. Clinical Characteristics of Genitourinary Tuberculosis during a Recent 10-Year Period in One Center. *Korean J Urol.* 2011;52(3):200-5.

Received 12 December 2021 | **Accepted** 18 January 2022