

Images in Infectious Diseases

Innovative mapping of skin sensitivity by monofilaments to record the diagnosis and therapeutic follow-up of leprosy

Fred Bernardes Filho^{[1],[2]} , Filipe Rocha Lima^{[1],[2]} 
 and Marco Andrey Cipriani Frade^{[1],[2]} 

[1]. Universidade de São Paulo, Faculdade de Medicina de Ribeirão Preto,

Departamento de Clínica Médica, Divisão de Dermatologia, Ribeirão Preto, SP, Brasil.

[2]. Universidade de São Paulo, Faculdade de Medicina de Ribeirão Preto, Hospital das Clínicas,
 Centro de Referência Nacional em Dermatologia Sanitária com Ênfase em Hanseníase, Ribeirão Preto, SP, Brasil.

A 53-year-old previously healthy woman presented with a 5-month history of numbness of the hands and feet, tingling sensation, and nerve pain in the legs. Positive findings on physical examination included hypochromic, anesthetic, and anhidrotic macules, with incomplete endogenous histamine tests on the right knee (**Figure 1**), electric shock-like pain on common fibular nerves, and altered tactile sensitivity of the hands and feet (**Figure 2**). She was positive for IgM anti-phenolic glycolipid-I, IgA, and IgM anti-mammalian cell entry 1A protein of *Mycobacterium* antibodies. *Mycobacterium leprae* DNA-specific repetitive element polymerase chain reaction (RLEP-PCR) was positive on skin biopsy and slit skin smear. Ultrasonography of peripheral nerves showed asymmetric and focal multiple mononeuropathies without an intraneural Doppler signal. Borderline leprosy was diagnosed clinically and by laboratory tests, and she was prescribed multibacillary multidrug therapy. Cutaneous lesion mapping (**Figure 3**) and hands/feet tactile sensitivity tests (Semmes-Weinstein monofilaments) were performed monthly. There was a significant improvement in dermatological signs and neurological symptoms under specific treatment of leprosy with antimicrobials.

Recent studies have demonstrated the importance of appreciating neurological symptoms over dermatological signs in the diagnosis of leprosy¹. Hypochromic macules with altered sensitivity are a common presentation in the entire spectrum of leprosy^{2,3}. The exclusive linkage of macular lesions to indeterminate

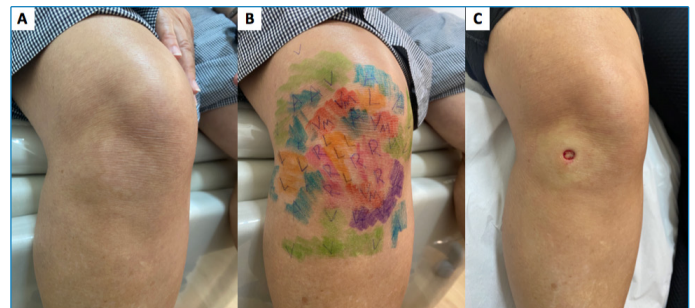


FIGURE 1: (A) Hypochromic macule on the right knee; (B) altered tactile skin sensitivity mapped by Semmes Weinstein monofilaments ranging from 0.07 gram-force (gf) to 300-gf (normal skin tactile threshold = green monofilament, 0.07-gf); (C) the macule is more evident due to the erythema surrounding the lesion after local anesthesia for skin biopsy, like the incomplete endogenous histamine test. **Legend:** green (0.07-gf); blue (0.2-gf); violet (2-gf); red (4-gf); orange (10-gf); pink (300-gf).

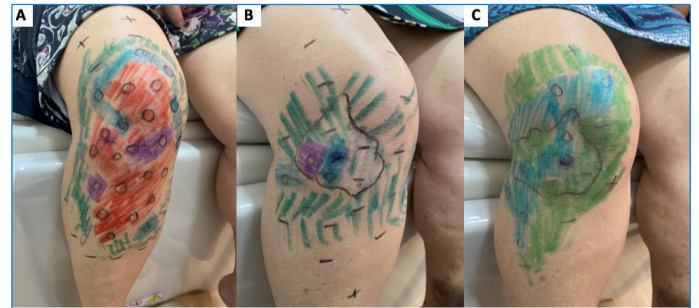
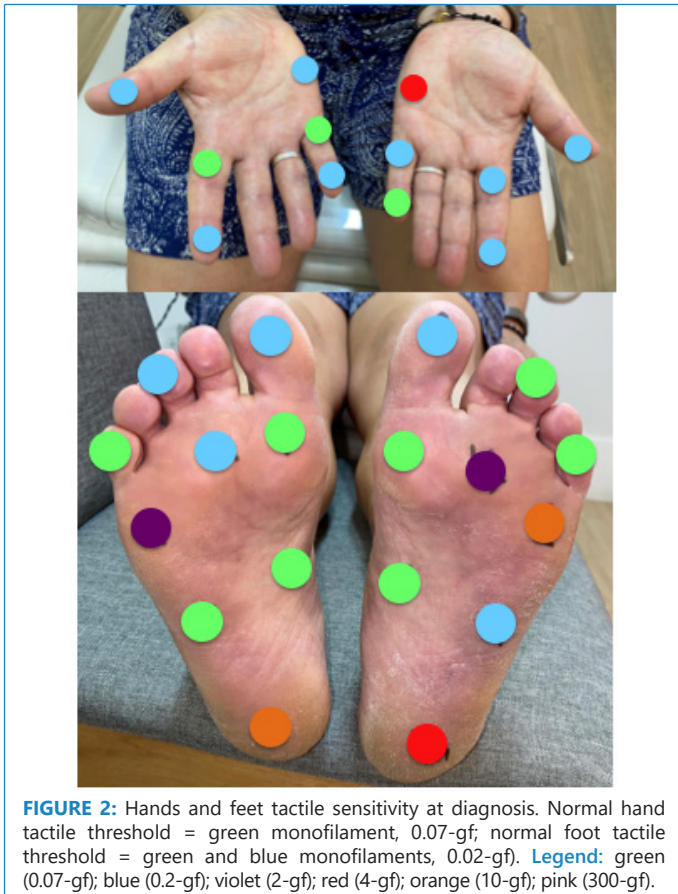leprosy is an incorrect paradigm in leprosy that leads to inadequate and insufficient treatment. The innovative mapping of cutaneous lesions using monofilaments and the usual hands/feet sensitivity evaluation is an objective assessment that documents the hallmark focality and asymmetry of leprosy at diagnosis and during follow-up.

Corresponding author: Prof. Dr. Marco Andrey Cipriani Frade. **e-mail:** mandrey@fmrp.usp.br

Authors' contribution: FBF: Study conception and design, Acquisition of data, Analysis and interpretation of data, Drafting of manuscript, Critical revision; FRL: Study conception and design, Acquisition of data, Analysis and interpretation of data, Drafting of manuscript, Critical revision; MACF: Study conception and design, Acquisition of data, Analysis and interpretation of data, Drafting of manuscript, Critical revision.

Conflict of interest: The authors declare that there is no conflict of interest.

Financial Support: This work was supported by the Center of National Reference in Sanitary Dermatology focusing on Leprosy of Ribeirão Preto Clinical Hospital, Ribeirão Preto, São Paulo, Brazil; the Brazilian Health Ministry (MS/FAEPAFMRP-USP: 749145/2010 and 767202/2011); Fiocruz Ribeirão Preto - TED 163/2019 - Processo: N° 25380.102201/2019-62/ Projeto Fiotec: PRES-009-FIO-20.



REFERENCES

1. Maymone MBC, Laughter M, Venkatesh S, Dacso MM, Rao PN, Stryjewska BM, et al. Leprosy: Clinical Aspects and Diagnostic Techniques. *J Am Acad Dermatol.* 2020;83(1):1-14. Available from: <https://doi.org/10.1016/j.jaad.2019.12.080>.
2. Sarkar R, Kaur I, Das A, Sharma VK. Macular lesions in leprosy: A clinical, bacteriological and histopathological study. *J Dermatol.* 1999;26(9):569-76. Available from: <https://doi.org/10.1111/j.1346-8138.1999.tb02051.x>.
3. Frade MAC, Rosa DJF, Bernardes Filho F, Spencer JS, Foss NT. Semmes-Weinstein monofilament: A tool to quantify skin sensation in macular lesions for leprosy diagnosis. *Indian J Dermatol Venereol Leprol.* 2021;87:1-9. Available from: https://doi.org/10.25259/IJDVL_622_19.

Received 7 July 2021 | Accepted 11 August 2021