

## Case Report

# Unusual vaginal bleeding due to a leech bite in a girl from a tropical area: A case report

Malihe Hasanzadeh<sup>[1]</sup>, Hossein Zarrinfar<sup>[2]\*</sup> and Mohsen Najjari<sup>[3]</sup>

[1]. Department of Obstetrics and Gynecology, Mashhad University of Medical Sciences, Mashhad, Iran.

[2]. Allergy research center, Mashhad University of Medical Sciences, Mashhad, Iran.

[3]. Department of Parasitology and Mycology, School of Medicine, Mashhad University of Medical Sciences, Mashhad, Iran.

### Abstract

This study describes the isolation of a leech following the presentation of unusual vaginal bleeding. Vaginal bleeding in children due to a leech bite is very rare. This is the first report of severe bleeding in a virgin 14-year-old girl from Mashhad, Iran due to the presence of a leech in the vagina.

**Keywords:** Leech bite. Bleeding. Vagina.

### INTRODUCTION

Vaginal bleeding may occur for several reasons. Regardless of its pathological etiology, duration and quantity is always of clinical importance, especially in early puberty<sup>1</sup>. All young girls with unusual vaginal bleeding should be carefully investigated and appropriately managed. The underlying causes may be genital tumors, exogenous estrogens, trauma, uterine arteriovenous malformation, or parasites. However, vaginal bleeding due to a leech entering the vagina is unusual in the tropics<sup>2</sup>. Leeches are a member of phylum Annelida and class Hirudinea. They are variable in size and have muscular, pigmented oval bodies with a tough cuticle, suckers at both ends, hard jaws, and a muscular pharynx. The majority of leeches live in freshwater environments such as rivers and ponds, while some species can be found in terrestrial and marine environments. Most leeches are predominantly blood suckers that feed on blood from vertebrate and invertebrate animals<sup>3</sup>. However, severe injuries to the internal viscera due to a leech bite are uncommon. When they do occur, they can cause serious morbidity and may even be fatal. Leech bites can occur on various sites, including the esophagus, larynx, pharynx, nose, bladder, and rectum<sup>4</sup>.

Vaginal bleeding due to a leech bite is rare, but when it occurs, it may be *caused by poor hygiene*. To our knowledge, this is the first report of vaginal bleeding due to a leech bite in a virgin girl from a rural area of Sarakhs in Khorasan Razavi province, Iran. Due to the patient's virginity, many doctors refused to perform an internal examination of the patient. However, the leech was located *underneath the vestibular bulbs and the hymen had not been damaged*.

### CASE REPORT

A virgin 14-year-old female was admitted to Ghaem Educational, Research, and Treatment Center in Mashhad, Northeast Iran. Her chief *complaint* was abnormal vaginal bleeding or irregular spotting. Her general condition was stable, except for a mild pale appearance. She complained of menorrhagia with clot formation which had begun one month prior to the referral. She had no history of trauma or pain, nor was there evidence of rape or abuse. However, she lived in a *somewhat* unhygienic environment and had washed her external genitalia with stagnant pond water. Her vital signs were as follows: blood pressure 10/60 mmHg, heart rate 84 beats/min, and temperature 37°C (98.6°F). The laboratory and *hematological* findings showed urea 11 mg/dl, creatinine 0.5 mg/dl, iron (Fe) 37 µg/dL, total iron binding capacity (TIBC) 394 µg/dL, lactate dehydrogenase (LDH) 298 U/L, ferritin 23 mg/ml, *beta*-subunit of human chorionic gonadotropin (β-hCG) 1.1 IU/L, hemoglobin (Hb) 3.9 g/dL, hematocrit (Hct) 13.6%, red blood cells (RBCs) 1.63×10<sup>6</sup> µL, mean corpuscular volume 83.4 fl, mean corpuscular hemoglobin (MCH) 23.9 pg, the

**Corresponding Authors:** Hossein Zarrinfar & Mohsen Najjari

**e-mail:** Zarrinfarh@mums.ac.ir

**Orcid:** 0000-0002-1449-4668

**Received** 4 December 2018

**Accepted** 11 March 2019

amount of hemoglobin relative to the size of the cell, MCHC 28.7 g/dL, and white blood cells (WBCs)  $10.9 \times 10^3 \mu\text{L}$ .

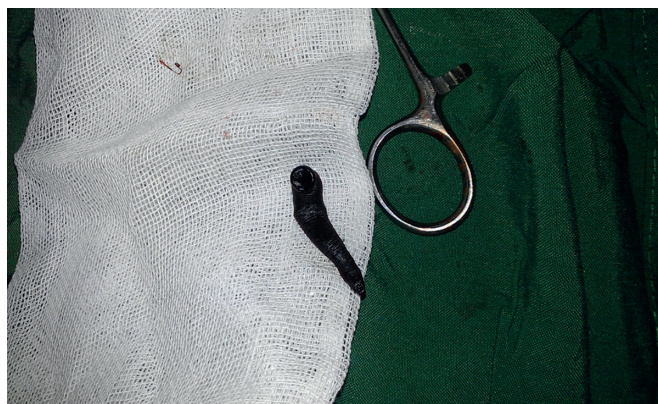
The patient underwent a pelvic examination. Her vagina was explored using a nasal speculum and a 6-cm leech was observed in the posterior wall of the vagina at the junction of the middle and lower thirds (**Figure 1 and 2**). Due to the lack of health care and long hair, this organism was hidden in that area. It was stuck firmly to the mucosa of the vagina. The leech was removed by irrigation with normal saline (0.9%) followed by extraction with plain forceps. After the leech was removed, vaginal bleeding stopped. For *stabilization of the patient's vital signs* and to reverse *anemia*, two units of packed red blood cells were transfused. Moreover, ferrous sulfate 200 mg three times a day was prescribed for four weeks. The patient's condition improved and no other pathological findings were found at the time of discharge. When the patient returned for a follow-up examination three months after the procedure, she was in good health.

## DISCUSSION

While medical treatment using leeches has been described in ancient literature, the morbidities associated with leeches have been less discussed<sup>3</sup>. Greek and Moorish physicians treated some patients by leech phlebotomy<sup>5</sup>. In addition, leeches were used in the treatment of female pelvic diseases such as uterine congestion in England in the nineteenth century. In Iran, the great physician Avi Sina (Ibn Sīnā or Abu Ali Sina, c. 980 – June 1037) in his medical encyclopedia *The Canon of Medicine* advised travelers to be cautious when drinking water from wells and springs, especially in the dark of the night, because they may be infested with leeches. Due to the dry weather and low rainfall in the area, residents of some of these areas used water collected in pits or holes. Avi Sina also described the shapes and sizes of leeches in this region as well as their harmful or therapeutic effects for the first time<sup>6</sup>. Later, his successor Rhazi, in his book *Al-Hawi*, described the successful treatment of a young man dying of a stomachache who inadvertently ingested a leech when drinking leech-infested water<sup>7</sup>. Interestingly, the issue of human leech infestation has continued to the present day. In the current study, we describe the first report of unusual vaginal bleeding due to a leech bite in a virgin 14-year-old girl from a rural area in the northeast of Iran. The first case of unusual vaginal bleeding in our hospital belonged to a 79-year-old woman from a rural area (Sabzevar) in the southwest of Khorasan Razavi province<sup>5</sup>.

Abnormal menstrual bleeding is one of the most common reasons women visit a doctor. The causes of bleeding during adolescence include pregnancy due to rape, consumption of external hormones, coagulation disorders, infection, endocrine problems, systematic problems, anatomical causes, and localized disorders (benign and malignant tumors, trauma, foreign bodies inside the vagina)<sup>8</sup>.

In literature, leech bites have been less reported as possible reasons for vaginal bleeding<sup>5,9</sup>, with the exception of a study by Aribarg and Vorapong in Thailand which reported that 10 out of 55 studied cases of vaginal bleeding in young children were the result of leech bites. So far, no significant reports have been



**FIGURE 1:** Immediate postoperative appearance of the leech isolated from the vaginal tract.



**FIGURE 2:** The relaxing mode of the 6-cm leech.

provided on the causes of vaginal bleeding in minors in Iran. Bleeding due to leech infestation is caused by anticoagulation agents in leech saliva, which can significantly increase blood coagulation time due to their anti-thrombocytopenic properties<sup>10</sup>. Moreover, leech saliva also has platelet anti-aggregation properties which can prevent platelets from clotting in order to stop bleeding.

To identify the possible cause of bleeding, it is important to obtain the patient's medical history<sup>1</sup> with an emphasis on recent events and conduct a pelvic examination using a speculum. To complete the diagnosis, laboratory tests and imaging techniques can also be helpful. Forcibly removing a leech may cause hooks to remain in the wound, which can cause infection<sup>11</sup>. Leeches may be removed after blood feeding which usually lasts for approximately 20-120 min, after which they loosen their attachment. A local anesthetic (5 cc lidocaine 10% applied directly to the body of the leech<sup>5</sup>), a strong salt solution, or a lighted match (or cigarette) have been proposed for leech detachment in emergency situations.

Regarding the coagulation profile of the patient, additional treatment may be required. Patients with complex conditions may need extra medical precautions or care. However, if bleeding ceases after a short time no further treatment is usually required. In cases of heavy or *prolonged vaginal bleeding*, the vagina should be examined and washed with normal saline solution to ensure leech saliva has been removed and the canal should be cleaned and gauze inserted<sup>12</sup>.

Hence, physicians should be aware of human leech infestation as one of the possible reasons for vaginal bleeding in childhood, especially in patients from deprived areas with poor sanitation.

According to the *study*, abnormal vaginal bleeding in a virgin adolescent girl should be carefully examined. Removal of the leech should be done carefully and without applying any additional pressure and by washing with saline solution. Moreover, in order to decrease morbidities from vaginal leech infestation, health care professionals should be aware of this issue in those who use collected water for drinking and bathing and those who live in *urban or rural* areas with poor sanitation.

**Acknowledgements:** We thank the staff of the Medical Parasitology and Mycology Laboratory in Ghaem Hospital at Mashhad University of Medical Sciences.

**Conflict of Interest:** The authors declare that they have no conflict of interest.

## REFERENCES

1. Muram D. Vaginal bleeding in childhood and adolescence. *Obstet Gynecol Clin North Am.* 1990;17(2):389-408.
2. Saha PK, Roy S, Bhattacharya D, Mukherjee P, Naskar T, Bhuiya A. Leech bite: a rare gynecologic emergency. *Med Gen Med.* 2005;7(4):73.
3. Elliott JM, Kutschera U. Medicinal leeches: historical use, ecology, genetics and conservation. *Freshw Rev.* 2011;4(1):21-41.
4. Krüger C, Malleyeck I, Olsen OH. Aquatic leech infestation: a rare cause of severe anaemia in an adolescent Tanzanian girl. *Eur J Pediatr.* 2004;163(6):297-9.
5. Mofrad MH, Shafiei R, Bolandi S, Najjari M, Hatam G. Leech bite: a rare cause of postmenopausal vaginal bleeding. *Iran Red Crescent Med J.* 2012;14(6):384-5.
6. Azizi MH. The otorhinolaryngologic concepts as viewed by Rhazes and icenna. *Arch Iran Med.* 2007;10:552-5.
7. Saifi N, Alam S, Ahmed S. Leech Therapy: Modern and Unani Medicine Perspective. *World J Pharm Pharmac Sci.* 2016;5(9):796-802.
8. Cowan BD, Morrison JC. Management of abnormal genital bleeding in girls and women. *N Engl J Med.* 1991;324(24):1710-5.
9. Hannan MJ, Hoque MM. Leech infestation in children through body orifices: experience in a hospital in Bangladesh. *World J Surg* 2012;36(1):2090-2.
10. Hernández M, Ramírez Gutierrez RE. Internal hirudiniasis: vaginal bleeding resulting from leech bite. *Ginecol Obstet Mex.* 1998;66:284-6.
11. Ikizceli I, Aşaroğulları L, Sözüer E, Yürümez Y, Akdur O. Bleeding due to a medicinal leech bite. *Emerg Med J.* 2005;22(6):458-60.
12. Aribarg A, Phupong V. Vaginal bleeding in Thai children due to leech. *J Trop Med Parasitol.* 1999;22:77-9.