

# Reactions to the different pigments in tattoos: a report of two cases \*

Reações aos diferentes pigmentos de tatuagens: relato de dois casos

Fernanda André Martins Cruz <sup>1</sup>  
 Rafaela Marega Frigério <sup>3</sup>  
 Lúcia Helena Fávoro Arruda <sup>5</sup>

Denise Lage <sup>2</sup>  
 Mariana Colombini Zaniboni <sup>4</sup>

**Abstract:** Tattoos are defined as the intentional or accidental deposit of pigment into the skin. These pigments have been associated with various dermatoses such as allergic contact dermatitis, lichenoid dermatitis, photoinduced reactions, and granulomatous, sarcoid and pseudolymphomatous reactions. The objective of this report was to describe the various types of reactions to pigments and the importance of recognizing them clinically. Two cases are reported: one of lichenoid dermatitis resulting from a reaction to the red pigment of a tattoo and the other of a pseudolymphoma resulting from a reaction to red and lilac pigments and a photo-induced reaction to a yellow pigment. Removal generally requires multiple forms of treatment, most of which fail to remove the colors completely.

**Keywords:** Coloring agents; Skin manifestations; Tattooing

**Resumo:** A tatuagem é definida como deposição de pigmento intencional ou acidental na pele. Os pigmentos têm sido associados a diversas dermatoses, como a dermatite de contato alérgica, a dermatite liquenoide e as reações fotoinduzidas, granulomatosas, sarcoídeas e pseudolinfomatosas. Enfocam-se os diversos tipos de reações aos pigmentos e a importância de reconhecê-los clinicamente. São relatados dois casos: um de dermatite liquenoide sobre o pigmento vermelho e outro de pseudolinfoma sobre os pigmentos vermelho e lilás e de reação fotoinduzida sobre o amarelo. A remoção geralmente requer múltiplos tratamentos, e a maioria não retira as cores completamente.

**Palavras-chave:** Agentes corantes; Manifestações cutâneas; Tatuagem

## INTRODUCTION

Tattooing has been practiced for over 8000 years. It is common in many different cultures and countries, and its popularity had been increasing in the Western world since the 1970s. The Portuguese word for tattoo, "tatuagem" originates directly from the English. <sup>1-3</sup> Studies have reported various reactions to the salts and organic and inorganic compounds used in tattoos. <sup>1-8</sup> Among the most common reactions, those resulting from the red pigment deserve particular mention. These may be associated with allergic contact dermatitis, lichenoid dermatitis and pseudolymphoma, the two latter conditions having been identified in the cases presented here.

## CASE REPORT

### Case 1

A 24-year old female patient presented with pruriginous lesions that had been present for one year on a tattoo performed three years previously on her right ankle. Examination revealed excoriated, lichenified plaques located over the red pigment (Figure 1). Biopsy revealed hyperparakeratosis, chronic lichenoid inflammatory infiltrate with perivascular involvement, in addition to a deposit of pigment on the dermis compatible with lichenoid dermatitis (Figure 2). Intralesional corticoid therapy was administered, resulting in a significant improvement in the appearance of the lesions.

Received on 06.08.2009.

Approved by the Advisory Board and accepted for publication on 19.03.2010.

\* Study conducted at the Department of Dermatology, Celso Pierro Hospital and Maternity Home, Pontifical Catholic University of Campinas (PUC, Campinas), Campinas, São Paulo, Brazil.

Conflict of interest: None / *Conflito de interesse: Nenhum*

Financial funding: None / *Suporte financeiro: Nenhum*

<sup>1</sup> Medical resident in Dermatology, Celso Pierro Hospital and Maternity Home, Pontifical Catholic University of Campinas (PUC, Campinas), Campinas, São Paulo, Brazil.

<sup>2</sup> Physician, Department of Dermatology, Celso Pierro Hospital and Maternity Home, Pontifical Catholic University of Campinas (PUC, Campinas), Campinas, São Paulo, Brazil.

<sup>3</sup> Head, Department of Dermatology, Celso Pierro Hospital and Maternity Home, Pontifical Catholic University of Campinas (PUC, Campinas), Campinas, São Paulo, Brazil.

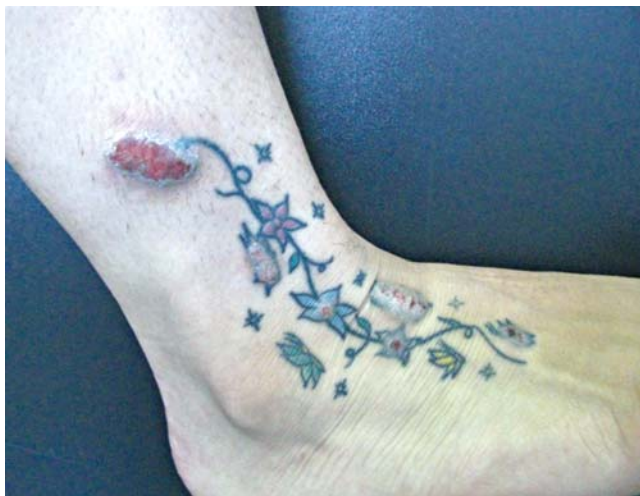

FIGURE 1: Lichenified, excoriated plaques located over the red pigment



FIGURE 3: Hyperkeratotic nodulations over the purple pigment

**Case 2**

A 30-year old male patient who presented with nodules over the purple and red pigments of a tattoo performed on his right leg one year previously. After sun exposure two months prior to consultation, lesions had also appeared over the yellow pigment. Examination showed hyperkeratotic nodulations over the purple and red pigments and erythematous papules over the yellow pigment (Figures 3, 4 and 5). Biopsies of the red and purple pigments, performed prior to the appearance of the lesions over the yellow pigment, showed intense, diffuse, dense lymphocytic inflammatory infiltrate around the pigment, compatible with pseudolymphoma (Figure 6). The reaction to the yellow pigment was considered to be photoin-

duced, since it was noted that the lesion appeared following exposure to sunlight. Treatment was carried out with topical occlusive clobetasol; however, response was poor. Other treatments are currently being attempted.

**DISCUSSION**

Pigments are composed of both salts and inorganic metals such as mercury (red), chrome (green), manganese (purple), cobalt (blue), cadmium (yellow) and hydrated iron oxide (ochre) and of organic preparations such as sandalwood (red) and Brazilwood (red) and have been associated with various dermatoses.<sup>4</sup>

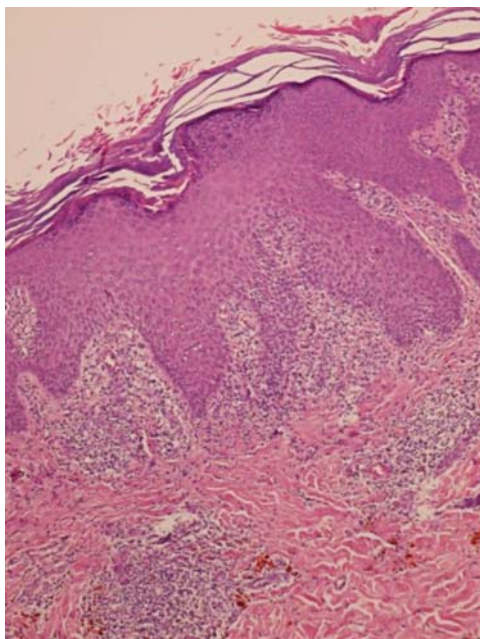


FIGURE 2: Hyperparakeratosis, chronic lichenoid inflammatory infiltrate with perivascular involvement, in addition to a deposit of pigment in the dermis compatible with lichenoid dermatitis. Hematoxylin-eosin, magnification 100x



FIGURE 4: Hyperkeratotic nodulations over the red pigment

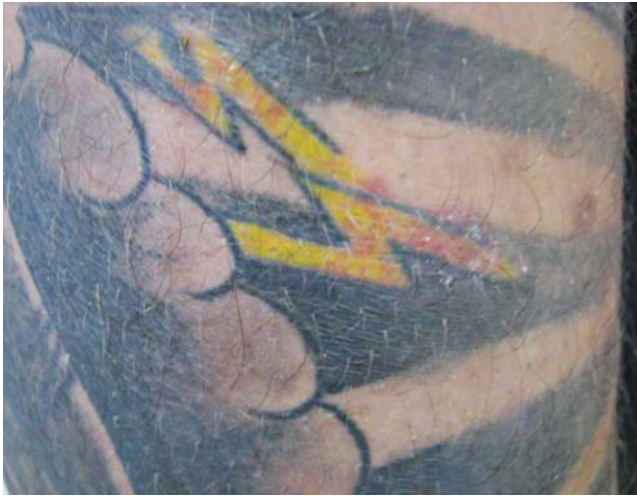

FIGURE 5: Erythematous papules over the yellow pigment: a photo-induced reaction

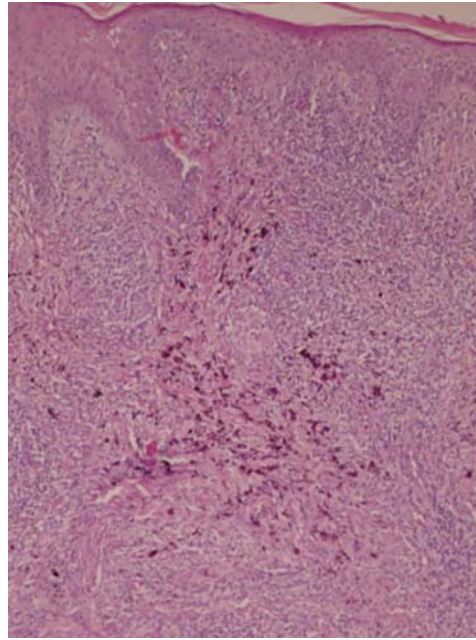


FIGURE 6: Intense, diffuse, dense, lymphocytic inflammatory infiltrate around the pigment, compatible with pseudolymphoma. Hematoxylin-eosin, magnification 100x

Reactions may be acute, secondary to a physical injury from the injection of pigments into the skin immediately following a tattoo or may occur after various months or years. In these cases, the most common reactions are allergic contact dermatitis and lichenoid dermatitis, principally due to the red pigment (mercury).<sup>2,4,5</sup> The patch test may be positive for mercury; however, it will be negative for organic red.<sup>4</sup>

Photoinduced reactions, which are associated principally with yellow pigments, generally present as erythematous, pruriginous nodules that appear following sun exposure, as occurred with the second patient described in this report.<sup>4</sup>

The granulomatous reaction is a foreign body reaction to the pigment and is associated with the use of mercury, chrome, cobalt and manganese.<sup>4</sup> It is generally limited to the colors of the tattoo and reflects a localized hypersensitivity reaction to the components of the pigments.<sup>1</sup>

Pure sarcoidal reactions are rare in tattoos. They generally occur as a reaction to the ochre dye, principally in silica-rich pigments. They may represent a nonspecific finding or a manifestation of systemic sarcoidosis.<sup>1</sup>

The pseudolymphomatous reaction presents as hardened erythematous nodules or violaceous plaques that appear on the tattoo and at histology reveal germinative, infiltrated mixed-cell centers, prin-

cipally in the superficial dermis and close to vessels. The lymphocytes are polyclonal. This type of reaction is more commonly associated with red, green and blue pigments.<sup>6</sup> Other dermatoses such as pyogenic infection, common warts and zygomycosis have also been described in tattoos. Many skin diseases appear to show a preference for tattooed skin and may present as a primary manifestation, as exacerbation of an existing lesion or may represent the Koebner phenomenon such as in lichen planus and psoriasis.<sup>7</sup>

No treatment has yet been successful. Cases have been reported of an improvement with the use of CO<sub>2</sub> laser and Q-switched Nd:YAG laser. The removal of tattoos by Q-switched Nd:YAG laser has shown better results. Nevertheless, in some cases the pigment may spread, further exacerbating the reaction. Removal generally requires multiple forms of treatment and most fail to completely remove the colors. Topical or intralesional corticosteroid therapy may also be used but recurrences are common.<sup>1,8</sup>

Two cases of reactions to tattoos were reported here. In the first case, two different reactions were found: one pseudolymphomatous reaction and one photoinduced reaction. In the second case, lichenoid dermatitis was diagnosed. This report is important because it describes the histological differences between skin reactions to pigments used in tattoos. □

## REFERENCES

1. Mortimer NJ, Chare TA, Johnston GA. Red tattoo reactions. *Clin Exp Dermatol*. 2003;28:508-10.
2. Litak J, Malcolm S, Gutierrez MA, Soriano T, Lask GP. Generalized liquenoid reaction from tattoo. *Dermatol surg*. 2007;33:736-40.
3. Sowden JM, Byrne JP, Smith AG, Hiley C, Suarez V, Wagner B, et al. Red tattoo reactions: X-ray microanalysis and patch-test studies. *Br J Dermatol*. 1991;124:576-80.
4. Adams DR, Eid MP, Badreschia S, Ammirati CT. Self assessment examination of the American Academy of Dermatology. A violaceous plaque. *J Am Acad Dermatol*. 2006;54:185-7.
5. Schwartz RA, Mathias CG, Miller CH, Rojas-Corona R, Lambert WC. Granulomatous reaction to purple tattoo pigment. *Contact Dermatitis*. 1987;16:198-202.
6. Burns T, Breathnach S, Cox N, Griffiths C. Rook's Textbook of dermatology. 7th ed. Blackwell science: London; 2004. p.39.67.
7. Morales-Callaghan AM Jr, Aguilar-Bernier M Jr, Martínez-García G, Miranda-Romero A. Sarcoid granuloma on black tattoo. *J Am Acad Dermatol*. 2006;55(5 Suppl):S71-3.
8. Argila DD, Chaves A, Moreno JC. Erbium:Yag laser therapy of lichenoid red tattoo reaction. *J Eur Acad Dermatol Venereol*. 2004;18:332-3.

---

MAILING ADDRESS / ENDEREÇO PARA CORRESPONDÊNCIA:

*Fernanda André Martins Cruz*  
*Hospital e Maternidade Celso Pierro - Serviço de Dermatologia*  
*Pontifícia Universidade Católica de Campinas/PUC-Campinas*  
*Av. John Boyd Dunlop, s/n., Jardim Ipaussurama*  
*13059-900 Campinas, SP, Brazil*  
*Telephone.: 19 3343 8496*  
*E-mail: feramcruz@yahoo.com.br*

How to cite this article/*Como citar este artigo*: Cruz FAM, Lage D, Frigério RM, Zaniboni MC, Arruda LHF. Reactions to the different pigments in tattoos: a report of two cases. *An Bras Dermatol*. 2010;85(5):708-11.