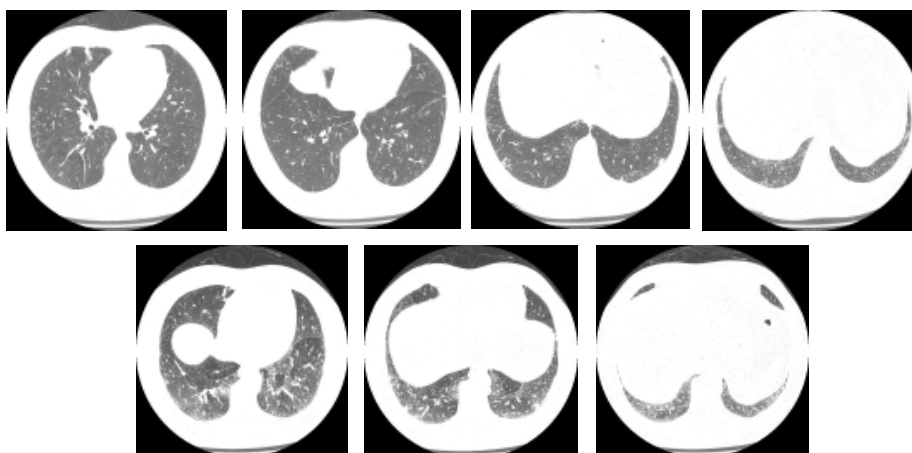


Radiological Diagnosis

Diagnosis of the case presented in the previous edition

J Bras Pneumol 2005;31(5):474.

YELLOW NAIL SYNDROME



A 66-year-old patient with a history of chronic lymphedema of the lower extremities, accompanied by recurrent pneumonia and pleural effusion. Presenting chronic cough with sputum that is colorless but abundant in the mornings.

COMMENTS

Yellow nail syndrome is a rare disorder characterized by a combination of lymphedema of the lower limbs (in 80% of cases), recurrent pneumonia, bronchiectasis, pleural (sometimes chylous) effusion (in 36%) and yellowing of the fingernails (in 89%). The etiology of the disease is unknown, and familial occurrence is rare. It is believed that the lymphedema, as well as the discoloration of the nails and the pleural effusion, are secondary to flaws in the development of the lymphatic canals (hypoplasia and dilatation). Bronchiectasis is more common in the lower lung lobes and might be accompanied by mucoid impaction (as in the case illustrated here). Its etiology is likely related to recurrent infection.

DANY JASINOWODOLINSKI; GILBERTO SZARF;
NESTOR L MÜLLER

Fleury Center for Diagnostic Medicine, São Paulo,
São Paulo, Brazil; Universidade Federal de São Paulo
(UNIFESP, Federal University of São Paulo), São
Paulo, São Paulo, Brazil, University of British
Columbia, Vancouver, British Columbia, Canada

REFERENCES

1. Moorjani N, Winter RJ, Yigsaw YA, Maiwand MO. Pleural effusion in yellow nail syndrome: treatment with bilateral pleuro-peritoneal shunts. *Respiration*. 2004;71(3):298.
2. Tanaka E, Matsumoto K, Shindo T, Taguchi Y. Implantation of a pleurovenous shunt for massive chylothorax in a patient with yellow nail syndrome. *Thorax*. 2005;60(3):254-5.
3. Alkadhi H, Wildermuth S, Russi EW, Boehm T. Yellow nail syndrome. *Respiration*. 2005;72(2):197.
4. Wiggins J, Strickland B, Chung KF. Detection of bronchiectasis by high-resolution computed tomography in the yellow nail syndrome. *Clin Radiol* 1991;43(6):377-9.
5. Norkild P, Kromann-Andersen H, Struve-Christensen E. Yellow nail syndrome-the triad of yellow nails, lymphedema and pleural effusions. *Acta Med Scand* 219:221-7.
6. Strickland J, Chung K. Detection of bronchiectasis by high-resolution computed tomography in the yellow nail syndrome. *Clin Radiol* 43(6):377-9.

**READER(S) CORRECTLY DIAGNOSING THE CASE PRESENTED IN THE SEPTEMBER/
OCTOBER 2005 ISSUE**

Adriano Rieger - Hospital Santa Catarina - Florianópolis - SC
Caio Júlio César dos Santos Fernandes - Universidade de São Paulo - São Paulo - SP
Carlos Alberto de Castro Pereira - Universidade Federal de São Paulo - São Paulo - SP
Carlos Marcelo Borges Santiago - Santa Casa de Misericórdia - Barretos - SP
Célio de Deus Simões - Policlínica Mara - Patos de Minas - MG
Cesar Higa Nomura - Massachusetts General Hospital - Boston - Estados Unidos
Cristian Cremones Vogas - Hospital Universitario Sul Fluminense - Vassouras - RJ
Edgar Fiss - Faculdade de Medicina de Pelotas - Pelotas - RS
Edson Garrido dos Santos Jacinto - Universidade Federal do Maranhão - São Luis - MA
Eduardo Rodrigues Martins Lima - Universidade Federal do Maranhão - São Luis - MA
Eduardo Walker Zettler - Pontifícia Universidade Católica do Rio Grande do Sul - Porto Alegre - RS
Elza Maria Figueiras Pedreira de Cerqueira - Universidade de Campinas - Campinas - SP
Francisco da Silva Maciel Junior - Universidade Federal do Espírito Santo - Vitória - ES
Heloisa Glass - Universidade Católica de Brasília - Brasília - DF
Jorge Luiz Zimmermann - Espaço Vital Clínica Médica - Itajaí - SC
Kennedy Kirk - Universidade Estadual do Rio de Janeiro - Rio de Janeiro - RJ
Leandro Antônio Gritti - Hospital de Caridade de Erechim - Erechim - RS
Lilian Pinto de Azevedo Oliveira - Samer Hospital - Resende - RJ
Luiz Carlos Corrêa da Silva - Pavilhão Pereira Filho - Santa Casa - Porto Alegre - RS
Luiz Homsy - Faculdade de Medicina de São José do Rio Preto - São José do Rio Preto - SP
Marcelo Alcântara Holanda - Hospital Universitário Walter Cantídio - Fortaleza - CE
Marcelo Chalhoub - Escola Bahiana de Medicina e Saúde Pública - Salvador - BA
Munira Martins de Oliveira - Hospital Júlia Kubitschek - Belo Horizonte - MG
Rene Agustín Flores Franco - Hospital General de México - Chihuahua - México
Ricardo Delduque - Hospital Emilio Carlos - Catanduva - SP
Roberto Saraiva da Silva - Família e Saúde - Belém - PA
Rogério Antonio Silva - Instituto de Doenças do Tórax - Rio de Janeiro - RJ
Rogério Lima Duarte - Hospital Emilio Carlos - Catanduva - SP
Ronaldo Adib Kairalla - Universidade de São Paulo - São Paulo - SP
Rosalvo Abreu - Hospital Santa Izabel - Salvador - BA
Suzete Mendes - Hospital Regional de Taguatinga - Brasília - DF
Virgílio Alexandre Nunes de Aguiar - Universidade Metropolitana de Santos - Santos - SP
Wagner Malheiros - Diagnóstico e Imagem - Juiná - MT
Wilson Assammi - Diagnóstico e Imagem - Juiná - MT