













# High resolution computed tomography patterns in interstitial lung disease (ILD): prevalence and prognosis

Renata Fragomeni Almeida<sup>1</sup> , Guilherme Watte<sup>2,3</sup> ,  
Edson Marchiori<sup>4</sup> , Stephan Altmayer<sup>2,3</sup> , Gabriel Sartori Pacini<sup>2</sup> ,  
Marcelo Cardoso Barros<sup>2,3</sup> , Aldo Paza Junior<sup>5</sup> , Adalberto Sperb Runin<sup>1</sup> ,  
Moacyr Christopher Garces Gamarra Salem<sup>1</sup> , Bruno Hochegger<sup>2,3</sup> 

1. Irmandade Santa Casa de Misericórdia de Porto Alegre, Porto Alegre (RS) Brasil.
2. Laboratório de Pesquisa em Imagem Médica, Departamento de Radiologia, Pavilhão Pereira Filho Hospital, Irmandade Santa Casa de Misericórdia de Porto Alegre, Porto Alegre (RS) Brasil.
3. Programa de Pós-Graduação em Medicina e Ciências da Saúde, Pontifícia Universidade Católica do Rio Grande do Sul, Porto Alegre (RS) Brasil.
4. Departamento de Radiologia, Escola de Medicina, Universidade Federal do Rio de Janeiro, Rio de Janeiro (RJ) Brasil.
5. Departamento de Radiologia, Hospital São Vicente, Passo Fundo (RS) Brasil.

Submitted: 09 May 2019.

Accepted: 25 October 2019.

Study carried out in the Santa Casa de Misericórdia de Porto Alegre, Porto Alegre (RS) Brasil.

## ABSTRACT

**Objective:** To correlate the prevalence and prognosis of each HRCT pattern of typical, probable, and indeterminate usual interstitial pneumonia (UIP) with the clinical multidisciplinary diagnosis of interstitial lung disease (ILD). **Methods:** We included all patients with a multidisciplinary diagnosis of ILD with an HRCT pattern of typical UIP, probable UIP, or indeterminate for UIP. Clinical and histopathological data, pulmonary function tests, and survival status were retrospectively obtained. The final diagnosis was validated by a multidisciplinary team. **Results:** A total of 244 patients were included in the study, with a mean age of 68 ±13 years and being 52.5% males. In a total of 106 patients with typical UIP pattern, 62% had the multidisciplinary diagnosis of IPF, 20% had chronic hypersensitivity pneumonitis (CHP), and 10% had connective tissue disease-related ILD (CTD-ILD). Out of the 114 cases with probable UIP, CTD-ILD corresponded to 39%, IPF to 31%, desquamative interstitial pneumonia to 11%, drug-related lung disease to 9%, and CHP to 8%. In the 24 patients with CT indeterminate for UIP, CTD-ILD was the final diagnosis in 33%, followed by desquamative interstitial pneumonia (21%), and IPF (13%). Patients with typical UIP were more likely to die or had lung transplantation in the follow-up (17.9% and 11.3%, respectively). **Conclusion:** IPF, CHP, and CTD-ILD were the main differential diagnoses in patients with HRCT patterns of typical, probable and indeterminate UIP. Patients with HRCT typical UIP pattern were more likely to die or had lung transplantation in the follow-up.

**Keywords:** High resolution computed tomography; Interstitial lung disease; Idiopathic pulmonary fibrosis; Usual interstitial pneumonia.

## INTRODUCTION

Idiopathic pulmonary fibrosis (IPF) represents one of the most common interstitial lung diseases (ILD), characterized by progressive, fibrotic interstitial pneumonia of unknown cause, and the finding of usual interstitial pneumonia (UIP) pattern on both high-resolution computed tomography (HRCT) and on anatomopathological exam.<sup>(1-4)</sup> IPF diagnosis is challenging, requiring multidisciplinary collaboration from pulmonologists, radiologists, and pathologists to integrate clinical data as well as interpretation of the radiological patterns of the disease.<sup>(5)</sup>

A new revision of the diagnostic recommendations of IPF based on the latest clinical trials and expert consensus was published by the ATS/ERS/JRS/ALAT in September 2018.<sup>(3)</sup> The diagnostic algorithm recommends all patients with ILD to undergo a thorough investigation to rule out specific causes of the disease, including investigation of environmental exposure, medication use, and serological tests. If no alternative cause is identified, the HRCT pattern must be considered. The radiological categories of UIP in this recent review are: UIP, probable UIP, indeterminate for UIP and alternative diagnosis.<sup>(3)</sup> The radiological

pattern of UIP is defined by bilateral reticulation and honeycombing, with peripheral traction bronchiectasis and bronchiolectasis, which are predominantly basal and subpleural.<sup>(1,3,5)</sup> Probable UIP differs from UIP by the absence of honeycombing, which are clusters of thick-walled cystic spaces of similar diameters typically located in the dorsal, basal and subpleural regions of the lung.<sup>(3)</sup> On the other hand, the indeterminate pattern presents evidence of basal and subpleural fibrosis but with other findings that do not suggest any specific diagnosis.<sup>(3)</sup> Thus, in the right clinical context, CT pattern of UIP are accurate to diagnose IPF without a biopsy.<sup>(5)</sup> However, in the case of probable UIP, indeterminate or CT pattern consistent with an alternative diagnosis, a multidisciplinary discussion can decide which other exams are necessary to establish the diagnosis, although ATS/ERS/JRS/ALAT suggests performing a surgical lung biopsy.<sup>(3)</sup>

In light of the contribution of the HRCT to the diagnosis of fibrosing ILD, our goal was to describe the prevalence and survival of the different multidisciplinary diagnosis of ILD associated with the CT patterns of UIP (UIP, probable and indeterminate).

## Correspondence to:

Renata Fragomeni Almeida. Universidade Federal de Ciências da Saúde de Porto Alegre, Rua Sarmento Leite, 245, CEP 90050-170, Porto Alegre (RS), Brasil.  
Tel.: +55 51 3303-9000/+55 51 99701-7074. E-mail: re\_fragomeni@yahoo.com.br  
Financial support: None.

## METHODS

### Study population

We included consecutive patients aged >18 years with a multidisciplinary diagnosis of IPF or any other ILD with HRCT showing a pattern of UIP, probable UIP and indeterminate for UIP, at our reference center from January 2012 to January 2016. Diagnosis was determined either by surgical lung biopsy or by multidisciplinary discussions. Histological pattern of UIP on surgical lung biopsy and clinical-radiologic diagnosis was based on the ATS/ERS/JRS/ALAT.<sup>(3)</sup> Patients were excluded if they were not followed-up at our center after the initial CT scan. Clinical data, including demographics, occupational exposure, smoking history, comorbidities at the time of the first appointment, pulmonary function tests, histopathological data, and deceased status were retrieved using medical records. This retrospective study was approved by the local ethics committee (number 1.763.960).

### CT protocols and imaging analysis

HRCT was performed with 1.0 mm thick sections throughout the entire lung during inspiration and expiration in the supine position. All CT scans were performed in 64MDCT GE LightSpeed 64 VCT (GE Healthcare, Waukesha, Wisconsin). The CT scanning protocol was spiral mode, 120 kVp, 2000 mA, 0.5- s rotation time, 0.5-mm collimation and HRCT kernel was applied. CT images were reconstructed with 1-mm slice thickness in axial, coronal and sagittal.

Paired inspiratory and expiratory images were independently evaluated by two thoracic radiologists with more than 8 years of experience. All cases had their HRCT patterns reviewed and reclassified into the three groups of UIP according to the new criteria in the 2018 ATS/ERS/JRS/ALAT guideline.<sup>(3)</sup> A UIP pattern was defined by the presence of basal and subpleural predominance plus honeycombing with or without peripheral traction bronchiectasis or bronchiolectasis. The criterion of indeterminate for UIP, according to the guideline, was the presence of basal and subpleural fibrosis with mild reticulation, ground-glass opacities and/or distortion and other findings that do not suggest a specific etiology.<sup>(3)</sup> Radiologists interobserver agreement was assessed by calculating the kappa statistic ( $\kappa$ ) and was interpreted according to a previous study.<sup>(6)</sup>

### Multidisciplinary diagnostic criteria

A multidisciplinary group with the integration of pulmonologist, rheumatologist, radiologist, and pathologist was responsible for reviewing the final clinical diagnosis in selected cases. These multidisciplinary conferences occur monthly to evaluate patients with probable or indeterminate for UIP HRCT pattern, patients with non-characteristic disease or suspected for a different etiology other than IPF or also those with clinical evolution discordant to the previously

established diagnosis. The initial approach was to rule out other causes of interstitial lung disease. Selected cases underwent surgical lung biopsy in case of a "possible UIP pattern" (per the ATS 2011 guidelines, since it is a retrospective study) when clinically tolerable by the patient<sup>(2)</sup>. Therefore, the final diagnosis was established considering the clinical, radiological and histopathological findings.

### Statistical analysis

Data were presented as frequency and percentage or mean  $\pm$  standard deviation (SD) or median (IQR). Initial group comparisons were performed using ANOVA test for continuous variables and Chi-square tests for categorical. Cox regression analysis was performed and hazard ratios (HR) were calculated to investigate the potential factors associated with higher overall mortality. Only variables that showed a  $p < 0.10$  were included in the multivariate analysis. In all other cases,  $p$  values were two-tailed and considered statistically significant with an alpha of 0.05. Statistical analyses were performed using the SPSS v.18 (IBM, Chicago, IL).

## RESULTS

A total of 244 patients were included in the study, and their characteristics are described in Table 1. Among those, 106 presented a UIP pattern, 114 had probable a UIP pattern, and 24 had an indeterminate pattern for UIP. Cases of UIP and probable UIP patterns and their histopathological correlation are shown in Figures 1 and 2. Most patients in our sample were male (52.5%), had a mean age of  $68 \pm 13$  years and were non-smokers (70.9%). The median length of follow-up was 2 years in the total sample, in which 31 (12.7%) of our total sample died, and 17 (7%) had pulmonary lung transplantation. Compared to those with probable and indeterminate pattern of UIP, patients with UIP patterns were more often smokers (37.7% vs. 24.6% and 12.5%, respectively;  $p = 0.017$ ), and were more likely to undergone lung transplantation (11.3% vs. 3.5% and 4.2%;  $p = 0.021$ ).

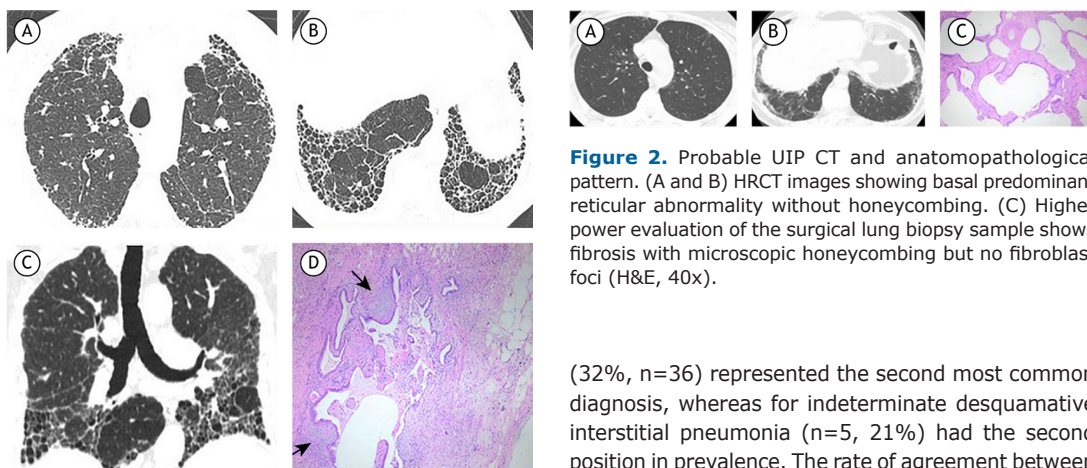
About the prevalence of final diagnosis, 43% ( $n=105$ ) of the 244 patients had IPF, 25.8% ( $n=63$ ) had CTD-ILD, followed by CHP with 12.3% ( $n=30$ ), desquamative interstitial pneumonia (7.4%,  $n=18$ ), drug-related lung disease (5.3%,  $n=13$ ), unclassifiable fibrosis (2%,  $n=5$ ), bronchiolocentric interstitial pneumonia (1.6%,  $n=4$ ), pneumoconiosis (1.2%,  $n=3$ ) and lymphoid interstitial pneumonia (1.2%,  $n=3$ ). In total, 69 patients were diagnosed by SLB and the remaining 175 by multidisciplinary consensus based on clinical and radiological findings.

The prevalence of each individual diagnosis stratified according to the CT pattern of UIP is shown in Table 2. The most prevalent diagnosis in patients with UIP pattern on HRCT were IPF ( $n=66$ , 62%) and chronic hypersensitivity pneumonitis (CHP) ( $n=21$ , 20%). On the

**Table 1.** Baseline patient characteristics.

Parameter	Total (N=244)	Probable UIP (N=114)	Indeterminate UIP (N=24)	UIP (N=106)	p
Sex					.391
Male	128 (52.5)	55 (48.2)	15 (62.5)	58 (54.7)	
Female	116 (47.5)	59 (51.8)	9 (37.5)	48 (45.3)	
Age, y	68±13	69±14	68±10	68±11	.945
Smoking history	71 (29.1)	28 (24.6)	3 (12.5)	40 (37.7)	.017
Clinical conditions					
Cardiomyopathy	46 (18.9)	20 (17.5)	3 (12.5)	23 (21.7)	.390
COPD	22 (9.0)	5 (4.4)	5 (20.8)	12 (11.3)	.021
Diabetes mellitus	71 (29.1)	28 (24.6)	3 (12.5)	40 (37.7)	.998
IPF	83 (38.4)	36 (31.6)	3 (12.5)	44 (56.4)	<.001
Lung cancer	25 (10.2)	12 (10.5)	4 (16.7)	9 (8.5)	.551
Lung transplantation	17 (7.0)	4 (3.5)	1 (4.2)	12 (11.3)	.021
PH	18 (7.4)	6 (5.3)	0	12 (11.3)	.066
CTD	43 (17.6)	23 (20.2)	4 (16.7)	16 (15.1)	.332
Lung function					
FEV <sub>1</sub> , L	1.82±0.65	1.92±0.76	1.80±0.45	1.73±0.58	.483
FEV <sub>1</sub> , %	71±20	74±20	70±20	67±20	.259
FVC, L	2,22±0.83	2,34±0.97	2,22±0.83	2,10±0.70	.500
FVC, %	68±19	70±18	68±19	66±21	.521
FEV <sub>1</sub> / FVC, ratio	1.04±0.11	1.05±0.12	1.04±0.11	1.04±0.10	.476
Follow-up	2.2±1.6	2.3±1.6	2.2±1.6	2.1±1.6	.366
Death	31 (12.7)	10 (8.8)	2 (8.3)	19 (17.9)	.037

COPD: chronic obstructive pulmonary disease; IPF: idiopathic pulmonary fibrosis; PH: pulmonary hypertension; CTD: connective tissue disease; FEV<sub>1</sub>: the forced expiratory volume in one second; FVC: forced vital capacity. Data were presented as N° (%) or mean ±SD.



**Figure 1.** UIP CT and anatomopathological pattern. (A-C) Axial and coronal HRCT images of a patient with UIP showing basal and subpleural predominance with honeycombing and reticular pattern. (D) Surgical lung biopsy demonstrating dense scarring with fibroblast foci (arrows) in a subpleural localization (H&E, 40x).

**Figure 2.** Probable UIP CT and anatomopathological pattern. (A and B) HRCT images showing basal predominant reticular abnormality without honeycombing. (C) Higher power evaluation of the surgical lung biopsy sample shows fibrosis with microscopic honeycombing but no fibroblast foci (H&E, 40x).

other hand, the most common diagnosis associated with the "probable" and "indeterminate" UIP patterns was connective tissue disease-associated interstitial lung disease (CTD-ILD) (n=44, 39%; n=8, 33%, respectively). In the group of probable UIP pattern, IPF

(32%, n=36) represented the second most common diagnosis, whereas for indeterminate desquamative interstitial pneumonia (n=5, 21%) had the second position in prevalence. The rate of agreement between radiologists was 94.05% ( $\kappa = 0.730$ ; 95% confidence interval, 0.60–0.80).

Death events during follow-up were statistically higher for UIP pattern (n=19, 17.9%) compared to probable (n=10, 8.8%) and indeterminate UIP (n=2, 8.3%) (Table 1). Cox regression analysis is shown in Table 3. In the multivariate analysis, the UIP pattern on HRCT (HR = 2.44, 95% CI 1.05-5.64) and lung cancer (HR = 4.20, 95% CI 1.79-9.82) were the only variables positively associated with higher mortality after controlling for age, smoking history, and cardiomyopathy.

**Table 2.** Distribution of prevalence ILD according to the HRCT pattern.

Final diagnosis	Total (N=244)	Probable UIP (N=114)	Indeterminate UIP (N=24)	UIP (N=106)	p
Drug-related lung disease	13 (5.3)	10 (8.7)	3 (12.5)	-	0.015
CTD	63 (25.8)	44 (38.6)	8 (33.3)	11 (10.3)	<0.001
IPF	105 (43)	36 (31.5)	3 (12.5)	66 (62.2)	<0.001
HP	30 (12.2)	9 (7.8%)	-	21 (19.9)	0.004
DIP	18 (7.3)	13 (11.4%)	5 (20.8)	-	<0.001
LIP	3 (1.2)	-	3 (12.5)	-	<0.001
BIP	4 (1.6)	2 (1.7%)	2 (8.3)	-	0.015
Unclassified	5 (2)	-	-	5 (4.7)	0.036
Pneumoconiosis	3 (1.2)	-	-	3 (2.9)	0.138

IPF: idiopathic pulmonary fibrosis; CTD: connective tissue disease; HP: Hypersensitivity pneumonitis; DIP: Desquamative interstitial pneumonia; LIP: Lymphoid interstitial pneumonia; BIP: Bronchiolocentric interstitial pneumonia. Data were presented as N° (%) or mean  $\pm$ SD.

**Table 3.** Cox regression analysis for overall mortality among HRCT findings and other independent factors.

Parameter	Univariate analysis <sup>a</sup>		Multivariate analysis <sup>b</sup>	
	HR (95% CI)	p	HR (95% CI)	p
HRCT findings		.026		.037
Indeterminate UIP	1.44 (0.30-6.89)		1.72 (0.36-8.19)	
UIP	2.66 (1.10-6.42)		2.44 (1.05-5.64)	
Female	1.44 (0.65-3.17)	.365		
Age, y	1.02 (0.99-1.06)	.107	1.01 (0.98-1.04)	.347
Smoking history	1.77 (0.79-3.95)	.017	1.95 (0.88-4.28)	.109
Clinical conditions				
Cardiomyopathy	2.94 (1.32-6.51)	.008	2.05 (0.93-4.50)	.077
COPD	1.32 (0.39-4.41)	.646		
DM	0.73 (0.25-2.07)	.558		
PH	1.40 (0.43-4.49)	.571		
Lung cancer	4.68 (2.05-10.6)	<.001	4.20 (1.79-9.82)	.001
Lung function				
FEV <sub>1</sub> , %	0.99 (0.96-1.03)	.888		
FVC, %	0.98 (0.94-1.02)	.339		
FEV <sub>1</sub> / FVC, ratio	3.89 (0.37-40.0)	.258		

HRCT: high resolution computed tomography; HR: hazard ratio; UIP: usual interstitial pneumonia; COPD: chronic obstructive pulmonary disease; PH: pulmonary hypertension; FEV<sub>1</sub>: the forced expiratory volume in one second; FVC: forced vital capacity; DM: Diabetes mellitus; CI = confidence interval. <sup>a</sup>All parameters at a significance level of p-value less than 0.10 in the univariate analysis were included in a multivariable model; <sup>b</sup>Model adjusted for HRCT findings, age, smoking history, cardiomyopathy, lung cancer, lung transplantation and CTD.

## DISCUSSION

Our study correlated the final multidisciplinary diagnosis with HRCT patterns of UIP, probable UIP, and indeterminate for UIP, based on clinical, radiological and pathological criteria to diagnose UIP of the latest ATS/ERS/JRS/ALAT guideline.<sup>(3)</sup> The majority of patients with typical UIP pattern had a final multidisciplinary diagnosis of IPF with CHP and CTD-ILD being the most prevalent differentials with this pattern. Most patients (97.1%) with a final multidisciplinary diagnosis of IPF had a typical or probable UIP pattern on CT. Notably, three patients with indeterminate UIP pattern were also diagnosed with IPF after a multidisciplinary evaluation. Patients with UIP pattern had a significantly higher mortality compared to the other two HRCT patterns.

Few studies have reported the general prevalence of interstitial lung diseases since their diagnosis is

difficult in some cases and requires a specialized multidisciplinary team. It is known that the prevalence and etiological distribution of the ILD in a population varies according to the region worldwide. Most current studies are more focused on IPF; they determined the prevalence of IPF is higher in the United States and Europe (ranging from 10 to 60 cases per 100,000), compared to South America and East Asia,<sup>(1,7-12)</sup> and is indeed actually raising compared to previous years.<sup>(7-9)</sup> One explanation for this fact is due to an increase in knowledge about the disease, with greater awareness of diagnosis and treatment.<sup>(9)</sup> While in North America IPF, CTD-ILD, and CPH represent the most prevalent forms of ILD (corresponding to 20% each), a study in a French population put CTD-ILD (16%) and IPF (11.6%) as the top etiologies of ILD.<sup>(1,10)</sup> In contrast, the distribution of ILD in an Indian population was



47.3% of CHP, 13.9% of CTD-ILD, and 13.7% of IPF.<sup>(13)</sup> The distribution of ILD in our study mirrored that of the American studies, having IPF, CHP and CTD-ILD, as the most prevalent differential diagnoses of fibrosing ILD.

Our results are also in agreement with previous studies that have shown a high concordance between UIP pattern on HRCT and a multidisciplinary diagnosis of IPF.<sup>(5,14-17)</sup> Chung et al.<sup>(18)</sup> showed that the correspondence of histopathological diagnosis of UIP is more often seen in those with definite and probable UIP on CT, compared to those with an indeterminate pattern. In a study with 214 subjects with IPF, Yagihashi et al.<sup>(19)</sup> found that 97,1% of the patients with an HRCT pattern of UIP had histologically definite or probable UIP. But they also showed that a large group of patients (94.7%) with “inconsistent with UIP” pattern on HRCT ended up with a pathological diagnosis of UIP, suggesting that the term “inconsistent” is actually misleading and not accurate. Likewise, a study with 59 subjects performed in a center with expertise in ILD demonstrated a high specificity of diagnosis of a new-onset IPF based on a clinical assessment or HRCT features alone, despite a relatively low sensitivity.<sup>(20)</sup>

It should be highlighted that HRCT alone without the appropriate clinical context cannot accurately establish the diagnosis of IPF since the pattern of UIP can be seen in other causes of ILD,<sup>(5)</sup> as demonstrated in our study. In light of that, both ATS/ERS/JRS/ALAT guideline and Fleischner Society’s review emphasize the importance of differentiating CHP and CTD-ILD from IPF in patients with advanced fibrosing ILD,<sup>(3,5)</sup> in which the CT features often overlaps.<sup>(5,21)</sup> Although CHP is characterized by upper and middle-lobe predominant and peribronchovascular fibrosis with ground-glass opacities, poorly defined centrilobular nodules, mosaic attenuation and air trapping, it may eventually be subpleural and present honeycombing, mimicking UIP.<sup>(22, 23)</sup> In our service we use the diagnostic algorithm for CHP suggested by Vasakova et al.<sup>(22)</sup> that includes evaluation of occupational and environmental history, physical examination, HRCT pattern, serum specific IgGs, bronchoalveolar lavage (BAL) and lung biopsy in selected cases. If the patient has a positive history of exposure and/or IgGs with typical HP HRCT pattern and BAL showing lymphocytosis, the diagnosis of HP can be made with confidence. Otherwise, a biopsy is indicated.<sup>(22)</sup>

The same issue is also true for connective tissue disease. Chung et al.<sup>(24)</sup> recently demonstrated that 57.4% of patients with interstitial pneumonia with autoimmune features (IPAF) presented with UIP HRCT features. ATS/ERS/JRS/ALAT recommends that all

patients with ILD should undergo serological tests to rule out CTD, although they do not have a consensus on which tests to perform routinely.<sup>(3)</sup> In our service, our initial approach includes serologies for C-reactive protein, erythrocyte sedimentation rate, antinuclear antibodies and rheumatoid factor.<sup>(2,25)</sup> Young patients, females and patients with signs and symptoms of CTD or positive serological tests are evaluated by a rheumatologist.<sup>(2,3,25)</sup> The prognosis of these diseases in cases of advanced fibrosis seems to be the same as for IPF, but when diagnosed in the early stages and treated correctly, it is substantially better.<sup>(2,23)</sup> These results confirm the importance of a multidisciplinary approach, correlating the clinical, radiological and pathological findings, especially in those patients with a non-characteristic clinical-radiological profile.

The patients with CT pattern of typical UIP were more likely to die or had lung transplantation compared to the other two patterns of UIP. This result is expected given the higher mortality of patients with IPF and also previous articles demonstrated worse outcome in those patients with definitive UIP on HRCT according to the 2011 ATS guidelines.<sup>(16,26-28)</sup> This fact may occur because UIP pattern on HRCT is more common in patients with a late stage of the disease, unlike the early stages, when radiological findings may be more atypical.<sup>(16,26-28)</sup>

Our study has a few limitations. First are the limitations inherent to the retrospective nature of the study. Second, since the patients were recruited in a single transplant reference center, the regional variability influences the results, because environmental factors, ethnicity, cultural habits and occupational risks are known to be related to the development of interstitial lung diseases.<sup>(9,10)</sup> Third, we do not have the histopathological data of all patients in particular to those with IPF, given the recent literature that supports withholding unnecessary biopsies to those patients. Thus, some degree of clinical uncertainty is often present in the benefit of the patient and also acknowledged by the Fleischer Society<sup>(5)</sup> and the ATS/ERS/JRS/ALAT guidelines.<sup>(3)</sup> We did not include patients with HRCT finding compatible with an alternative diagnosis, which could contribute to the overall distribution of the ILDs in our study.

In summary, we presented the prevalence of different multidisciplinary diagnosis of ILDs according to the latest HRCT patterns of UIP, probable UIP, and indeterminate for UIP by the 2018 ATS/ERS/JRS/ALAT guidelines. CHP and CTD-ILD were the primary differential diagnoses of IPF in patients with UIP pattern. Also, patients with HRCT typical UIP pattern were more likely to die or had lung transplantation in the follow-up.

## REFERENCES

- Lederer DJ, Martinez FJ. Idiopathic pulmonary fibrosis. *N Engl J Med.* 2018;378(19):19. <http://dx.doi.org/10.1056/NEJMra1705751>. PMID:29742380.
- Raghu G, Collard HR, Egan JJ, Martinez FJ, Behr J, Brown KK, et al. An official ATS/ERS/JRS/ALAT statement: idiopathic pulmonary fibrosis: evidence-based guidelines for diagnosis and management. *Am J Respir Crit Care Med.* 2011;183(6):788-824. <http://dx.doi.org/10.1164/rccm.2009-040GL>. PMID:21471066.
- Raghu G, Remy-Jardin M, Myers JL, Richeldi L, Ryerson CJ, Lederer DJ, et al. Diagnosis of idiopathic pulmonary fibrosis. An official ATS/ERS/JRS/ALAT clinical practice guideline. *Am J Respir Crit Care Med.* 2018;198(5):e44-68. <http://dx.doi.org/10.1164/rccm.201807-1255ST>. PMID:30168753.

4. Hewson T, McKeever TM, Gibson JE, Navaratnam V, Hubbard RB, Hutchinson JP. Timing of onset of symptoms in people with idiopathic pulmonary fibrosis. *Thorax*. 2018;73(7):683-5. <http://dx.doi.org/10.1136/thoraxjnl-2017-210177>. PMID:29021387.
5. Lynch DA, Sverzellati N, Travis WD, Brown KK, Colby TV, Galvin JR, et al. Diagnostic criteria for idiopathic pulmonary fibrosis: a Fleischner Society White Paper. *Lancet Respir Med*. 2018;6(2):138-53. [http://dx.doi.org/10.1016/S2213-2600\(17\)30433-2](http://dx.doi.org/10.1016/S2213-2600(17)30433-2). PMID:29154106.
6. Landis JR, Koch GC. The measurement of observer agreement for categorical data. *Biometrics*. 1977;33(1):159-74. <http://dx.doi.org/10.2307/2529310>. PMID:843571.
7. Raghu G, Chen SY, Hou Q, Yeh WS, Collard HR. Incidence and prevalence of idiopathic pulmonary fibrosis in US adults 18-64 years old. *Eur Respir J*. 2016;48(1):179-86. <http://dx.doi.org/10.1183/13993003.01653-2015>. PMID:27126689.
8. Navaratnam V, Fleming KM, West J, Smith CJ, Jenkins RG, Fogarty A, et al. The rising incidence of idiopathic pulmonary fibrosis in the U.K. *Thorax*. 2011;66(6):462-7. <http://dx.doi.org/10.1136/thx.2010.148031>. PMID:21525528.
9. Strongman H, Kausar I, Maher TM. Incidence, prevalence, and survival of patients with idiopathic pulmonary fibrosis in the UK. *Adv Ther*. 2018;35(5):724-36. <http://dx.doi.org/10.1007/s12325-018-0693-1>. PMID:29644539.
10. Duchemann B, Annesi-Maesano I, Jacobe de Naurois C, Sanyal S, Brillet PY, Brauner M, et al. Prevalence and incidence of interstitial lung diseases in a multi-ethnic county of Greater Paris. *Eur Respir J*. 2017;50(2):1602419. <http://dx.doi.org/10.1183/13993003.02419-2016>. PMID:28775045.
11. Karakatsani A, Papakosta D, Rapti A, Antoniou KM, Dimadi M, Markopoulou A, et al. Epidemiology of interstitial lung diseases in Greece. *Respir Med*. 2009;103(8):1122-9. <http://dx.doi.org/10.1016/j.rmed.2009.03.001>. PMID:19345567.
12. Kreuter M, Herth FJF, Wacker M, Leidl R, Hellmann A, Pfeifer M, et al. Exploring clinical and epidemiological characteristics of interstitial lung diseases: rationale, aims, and design of a nationwide prospective registry: the EXCITING-ILD Registry. *BioMed Res Int*. 2015;2015:123876. <http://dx.doi.org/10.1155/2015/123876>. PMID:26640781.
13. Singh S, Collins BF, Sharma BB, Joshi JM, Talwar D, Katiyar S, et al. Interstitial lung disease (ILD) in India: results of a prospective registry. *Am J Respir Crit Care Med*. 2017;195(6):801-13. <http://dx.doi.org/10.1164/rccm.201607-1484OC>. PMID:27684041.
14. MacDonald SLS, Rubens MB, Hansell DM, Copley SJ, Desai SR, du Bois RM, et al. Nonspecific interstitial pneumonia and usual interstitial pneumonia: comparative appearances at and diagnostic accuracy of thin-section CT. *Radiology*. 2001;221(3):600-5. <http://dx.doi.org/10.1148/radiol.2213010158>. PMID:11719652.
15. Silva CI, Müller NL, Lynch DA, Curran-Everett D, Brown KK, Lee KS, et al. Chronic hypersensitivity pneumonitis: differentiation from idiopathic pulmonary fibrosis and nonspecific interstitial pneumonia by using thin-section CT. *Radiology*. 2008;246(1):288-97. <http://dx.doi.org/10.1148/radiol.2453061881>. PMID:18096541.
16. Flaherty KR, Thwaite EL, Kazerooni EA, Gross BH, Toews GB, Colby TV, et al. Radiological versus histological diagnosis in UIP and NSIP: survival implications. *Thorax*. 2003;58(2):143-8. <http://dx.doi.org/10.1136/thorax.58.2.143>. PMID:12554898.
17. Hunninghake GW, Lynch DA, Galvin JR, Gross BH, Müller N, Schwartz DA, et al. Radiologic findings are strongly associated with a pathology diagnosis of usual interstitial pneumonia. *Chest*. 2003;124(4):1215-23. <http://dx.doi.org/10.1378/chest.124.4.1215>. PMID:14555549.
18. Chung JH, Chawla A, Peljto AL, Cool CD, Groshong SD, Talbert JL, et al. CT scan findings of probable usual interstitial pneumonitis have a high predictive value for histologic usual interstitial pneumonitis. *Chest*. 2015;147(2):450-9. <http://dx.doi.org/10.1378/chest.14-0976>. PMID:25317858.
19. Yagihashi K, Huckleberry J, Colby T, Tazelaar HD, Zach J, Sundaram B, et al. Radiologic-pathologic discordance in biopsy-proven usual interstitial pneumonia. *Eur Respir J*. 2016;47(4):1189-97. <http://dx.doi.org/10.1183/13993003.01680-2015>. PMID:26917616.
20. Raghu G, Mageto YN, Lockhart D, Schmidt RA, Wood DE, Godwin JD. The Accuracy of the Clinical Diagnosis of New-Onset Idiopathic Pulmonary Fibrosis and Other Interstitial Lung Disease. *Chest*. 1999;116(5):1168-74. <http://dx.doi.org/10.1378/chest.116.5.1168>. PMID:10559072.
21. Silva CI, Müller NL, Lynch DA, Curran-Everett D, Brown KK, Lee KS, et al. Chronic hypersensitivity pneumonitis: differentiation from idiopathic pulmonary fibrosis and nonspecific interstitial pneumonia by using thin-section CT. *Radiology*. 2008;246(1):288-97. <http://dx.doi.org/10.1148/radiol.2453061881>. PMID:18096541.
22. Vasakova M, Morell F, Walsh S, Leslie K, Raghu G. Hypersensitivity pneumonitis: perspectives in diagnosis and management. *Am J Respir Crit Care Med*. 2017;196(6):680-9. <http://dx.doi.org/10.1164/rccm.201611-2201PP>. PMID:28598197.
23. Vasakova M, Selman M, Morell F, Sterclova M, Molina-Molina M, Raghu G. Hypersensitivity Pneumonitis: current concepts of pathogenesis and potential targets for treatment. *Am J Respir Crit Care Med*. 2019;200(3):301-8. <http://dx.doi.org/10.1164/rccm.201903-0541PP>. PMID:31150272.
24. Chung JH, Montner SM, Adegunsoye A, Lee C, Oldham JM, Husain AN, et al. CT findings, radiologic-pathologic correlation, and imaging predictors of survival for patients with interstitial pneumonia with autoimmune features. *AJR Am J Roentgenol*. 2017;208(6):1229-36. <http://dx.doi.org/10.2214/AJR.16.17121>. PMID:28350485.
25. Jee AS, Adelstein S, Bleasel J, Keir GJ, Nguyen M, Sahhar J, et al. Role of autoantibodies in the diagnosis of Connective-Tissue Disease ILD (CTD-ILD) and Interstitial Pneumonia with Autoimmune Features (IPAF). *J Clin Med*. 2017;6(5):51. <http://dx.doi.org/10.3390/jcm6050051>. PMID:28471413.
26. Sumikawa H, Johkoh T, Colby TV, Ichikado K, Suga M, Taniguchi H, et al. Computed tomography findings in pathological usual interstitial pneumonia: relationship to survival. *Am J Respir Crit Care Med*. 2008;177(4):433-9. <http://dx.doi.org/10.1164/rccm.200611-1696OC>. PMID:17975197.
27. Travis WD, Matsui K, Moss J, Ferrans VJ. Idiopathic nonspecific interstitial pneumonia: prognostic significance of cellular and fibrosing patterns: survival comparison with usual interstitial pneumonia and desquamate interstitial pneumonia. *Am J Surg Pathol*. 2000;24(1):19-33. <http://dx.doi.org/10.1097/0000478-200001000-00003>. PMID:10632484.
28. Lee JS, Gong G, Song KS, Kim DS, Lim TH. Usual interstitial pneumonia: relationship between disease activity and the progression of honeycombing at thin-section computed tomography. *J Thorac Imaging*. 1998;13(3):199-203. <http://dx.doi.org/10.1097/00005382-199807000-00007>. PMID:9671423.