

# Intermittent annular reduction with Alfieri's repair in the treatment of mitral insufficiency in children: initial results

*Redução anular intermitente com plastia de Alfieri no tratamento da insuficiência mitral em crianças: resultados iniciais*

Moise DALVA<sup>1</sup>, Grace Caroline Van Leeuwen BICHARA<sup>2</sup>, Carlos Edson Campos CUNHA FILHO<sup>3</sup>, Gustavo Fernandes CARNEIRO<sup>3</sup>, Gustavo Niankowsky SALIBA<sup>3</sup>, José Arteaga CAMACHO<sup>3</sup>, José Viera ZÁRATE<sup>3</sup>, Renán Prado LÍMACO<sup>3</sup>

RBCCV 44205-1100

## Abstract

**Objective:** Mitral valve insufficiency must be treated by repair whenever as possible as it provides better results - especially within the pediatric population in order to avoid valve replacement inconvenients. The aim of this study is to describe mitral valve repair technique based on an anatomical and functional approach.

**Methods:** During a 13 months period, eight children (age ranged from 2 and 12 years old  $6.37 \pm 3.66$ ) with mitral valve insufficiency underwent intermittent anterior and posterior annuloplasty associated with Alfieri's repair - performed by placing a stitch between the anterior and posterior leaflets in the point of maximal regurgitation thus creating a double orificial mitral valve.

**Results:** There were no surgical deaths. All patients underwent postoperative echocardiography. Three patients showed mild insufficiency and five patients showed no insufficiency. The time in intensive care unit ranged from 2

to 4 days ( $2.5 \pm 0.75$ ), and the time of stay in hospital ranged from 5 to 8 days ( $6.37 \pm 1.06$ ).

**Conclusion:** In spite of the little sample size, the proposed technique proved itself to be simple and effective in the treatment of single mitral valve insufficiency within the pediatric population. In addition, it also yielded satisfactory immediate results. Long-term follow-up is nevertheless necessary in order to evaluate long-term results.

**Descriptors:** Heart defects, congenital. Child. Mitral valve.

## Resumo

**Objetivo:** A insuficiência mitral com indicação cirúrgica na faixa etária pediátrica deve ser tratada por meio de plastia sempre que possível, evitando-se os inconvenientes da substituição valvar. O objetivo deste trabalho é propor técnica de plastia mitral baseada em abordagem funcional e anatômica.

1. PhD Student – Pediatric Cardiovascular Surgeon (Responsible for the Pediatric Cardiac Surgery and Congenital Heart Diseases Department at the Santa Marcelina Hospital)
2. Pediatric Hemodynamicist (Responsible for the Postoperative and Pediatric Hemodynamic Department - Santa Marcelina Hospital)
3. Cardiovascular Surgeon – Santa Marcelina Hospital.

This study was carried out at the Santa Marcelina Hospital, Itaquera, São Paulo, SP, Brazil.

Correspondence address:

Dr. Moise Dalva - Rua Santa Marcelina, 177 - Itaquera - São Paulo - SP, Brasil. ZIP Code: 08270-070.

E-mail: moise.dalva@gmail.com

Article received on January 8<sup>th</sup>, 2009

Article accepted on June 23<sup>rd</sup>, 2009

**Métodos:** Durante período de 13 meses, foram operadas oito crianças (idade de 2 a 12 anos, média de  $6,37 \pm 3,66$  anos) portadoras de insuficiência mitral com realização de anuloplastia anterior e posterior de forma intermitente, associadas à plastia de Alfieri (passagem de ponto entre as cúspides no ponto de maior regurgitação, formando valva mitral biorificial).

**Resultados:** Não houve óbito nesta série. Ecocardiografia de controle pós-operatório foi realizada em todos os pacientes, com insuficiência mitral discreta em três pacientes, e sem evidência de insuficiência em cinco

pacientes. O tempo de permanência em unidade de terapia intensiva variou de 2 a 4 dias ( $2,5 \pm 0,75$ ), e o tempo de internação hospitalar variou de 5 a 8 dias ( $6,37 \pm 1,06$ ).

**Conclusão:** Apesar do tamanho limitado da amostra, a opção proposta revelou-se eficaz na avaliação imediata do tratamento da insuficiência mitral isolada em crianças. O acompanhamento dos pacientes faz-se necessário para avaliação dos resultados em longo prazo.

**Descritores:** Cardiopatias congênitas. Criança. Valva mitral.

## INTRODUCTION

Mitral regurgitation consists of a multifactorial disease, due to various mechanisms involved in its genesis, as regards the etiology, mechanical and functional aspects.

Although it is widely covered the fact that the accomplishment of reconstructive operations through plasty techniques presents the best functional result and less morbid impact in all patients [1] in the pediatric population, this option is even more true because of the inconvenience of performing valve replacement.

Surgical techniques of mitral valve repair are continually evolving, showing durable and reproducible results [2], but no technique of repair can be taken as universal, as the multitude of diseases and the great complexity of the entire mitral apparatus requires individualized maneuvers in order to achieve a successful correction surgery.

The aim of this study is to propose an innovative mitral valve repair technique, based on anatomical and functional concepts, whose major goal is to provide mitral competency in the pediatric population.

## METHODS

During 13 months (March 2007 to April 2008) eight patients with a severe mitral regurgitation with age ranged from 2 to 12 years with a mean of  $6.37 \pm 3.66$  years underwent surgery in our Service. None of the patients presented other cardiac anomalies. After admission, the patients underwent echocardiography witnessed by the surgical team, which aimed to examining the mechanisms involved in the genesis of the insufficiency, with special attention to enlargement of the annulus, the presence of a regurgitant jet and volume dilation of the left atrial and ventricular cavities.

One patient (12 years) was in functional class III, according to the criteria of the *New York Heart Association* (NYHA), two patients were in functional class II and the remaining were in functional class I. Five patients were

classified as patients with mitral regurgitation of rheumatic etiology. All patients' escorts signed written informed consent. The technique used consisted of median sternotomy, establishment of cardiopulmonary bypass (CPB) by aortic cannulation of the aorta, vena cava and inferior vena cava, cooling of the patient at 30 degrees, aortic clamping and antegrade cardioplegia, occlusion of venous cannulas, right atriotomy and opening of the interatrial septum, in order to provide appropriate exposure of the mitral valve. From this point, continence test was performed using induction of saline solution in order to evaluate the failure mechanism under direct vision.

The mitral annulus was considered dilated in all cases and its correction was performed using as parameter the diameter of the tricuspid annulus, being performed total bridging anuloplasty, which consists of performing an imaginary division of the annulus into four quadrants, from the inter-commissural region, by designating the quadrants as right anterior (RA), left anterior (LA), right posterior (PD) and left posterior (PE), from the surgeon's vision. Each quadrant was reduced individually by pexy of bovine pericardium strip with separated polypropylene sutures passed through the annulus, attempting to maintain the integrity of the annular geometry (Figure 1). From this point, Alfieri's repair was performed, which consists of fixation with polypropylene stitch anchored on a small patch of bovine pericardium from the leaflet anterior to the posterior leaflet in its mid-point (Figure 2), to prevent prolapse of both leaflets, which may occur due to the primary failure mechanism or as a consequence of the reduction in annular diameter. Such maneuver determines the formation of two orifices of blood flow from the left atrium to the left ventricle.

After completion of the repair, test with saline induction was performed, and the repair was considered continent in every case, by proceeding then the warming of the patient, suture of the interatrial septum, suture of the right atrium, fulfillment of maneuvers to remove intracavitary air, opening of the aortic clamp, restoration of heart rate, weaning from

CPB and completion of the surgery in the usual way. The CPB time ranged from 50 to 75 minutes, averaging  $61.75 \pm 8.51$  minutes, and anoxia time ranged from 40 to 55 minutes, averaging  $48.25 \pm 4.92$  minutes.

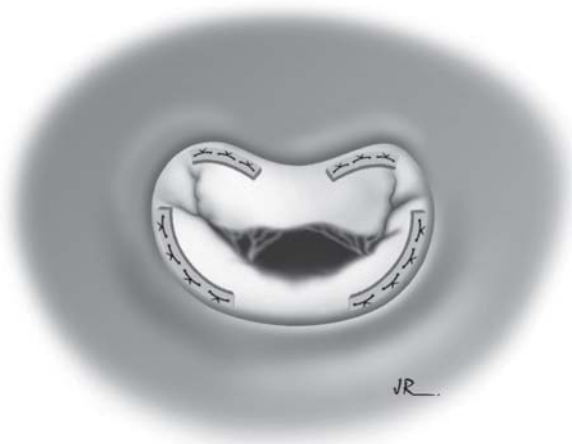


Fig. 1 – **Intermittent Annuloplasty**: Plications are performed using bovine pericardium strips on the various annulus segments

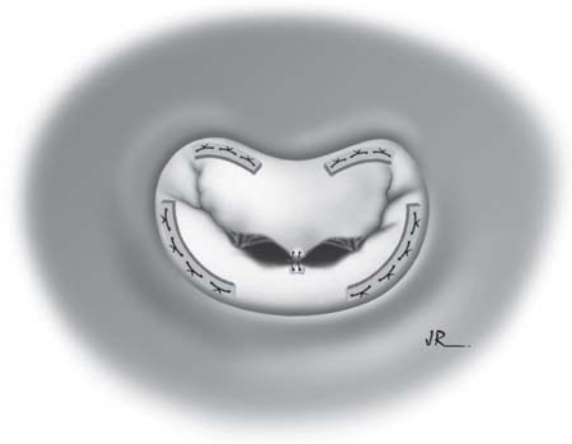


Fig. 2 – **Alfieri's repair**: approximation of the anterior and posterior leaflets is performed in the point of maximal regurgitation, in order to avoid prolapse of the leaflets over the valve plane

## RESULTS

There were no deaths in this series. No patient presented significant complications after the surgery. The length of stay in intensive care unit ranged from 2 to 4 days, averaging  $2.5 \pm 0.75$  days, and hospital stay ranged from 5 to 8 days,

averaging  $6.37 \pm 1.06$  days. No patient presented neurological events or worsening of renal function, and extubation was performed on the same day in five cases and the first day in the other patients. Postoperative control echocardiography was performed before hospital discharge, which revealed mild insufficiency in three patients, and no evidence of failure in five patients. There was no evidence of postoperative mitral stenosis in this series.

The period of follow-up ranged from 1 to 11 months and all patients were in functional class I.

## DISCUSSION

When feasible, the fulfillment of mitral repair should be considered standard treatment for all patients with mitral regurgitation, particularly the pediatric patients, because of better functional results, lower incidence of infective endocarditis [3], low risk of thromboembolism [4] and better left ventricular performance through the time [5]. Also, one must consider that the techniques of valve replacement in children generate several disadvantages, such as the need for frequent re-operations due to primary failure of biological valves [6] or possible need for anti-coagulation in cases of use of mechanical prosthesis. The results with mitral valve replacement by biological or mechanical prostheses in children are not encouraging [7], with high mortality and complications, particularly in patients aged under two years, whose 30-day mortality was 42% in casuistic review presented [8] by the group of Great Ormond Street Hospital for Children, London.

Currently, mitral valve repair can be performed with low morbidity and mortality, mainly due to the great improvement experienced with the development of new reconstructive techniques, which evolves continuously [9]. It is assumed that the conservation of the sub-valvular apparatus is an important part of good results in terms of maintenance of left ventricular function [10].

A universal technique for performing mitral valve does not exist, because of multiple factors involved in this entity.

The mitral valve anatomy in humans has been detailly studied [11]. The mitral valve is bicuspid, being composed of the left atrioventricular annulus, the anterior and posterior leaflet, which are linked by cordae tendinae to the anterolateral and posteromedial papillary muscles. The combined area of the two leaflets is approximately twice the area of the mitral orifice, a fact that allows a wide contact area between the two leaflets. The anterior is the largest, with roughly triangular shape, with its base occupying about one third of the valve annulus. The posterior leaflet is smaller and its insertion in the valve annulus occupies about two thirds of the diameter of this annulus. Although traditionally considered as an inert structure with respect to the dynamics of the valve closure, the valve annulus

has been its role redimensioned by recent studies, and it has been concluded that its function is much more effective than mere passive support where the leaflets are inserted, because there is an effective decrease of its circumference during systole, which reduces the area to be closed [12].

The observation of preoperative echocardiography by the surgical team is of capital importance in order to the physiopathology of each case is understood based on the various anatomical elements, allowing the correction plan for each individual case.

When the surgery for mitral valve replacement is performed, one should attempt to preserve the posterior leaflet with its sub-valvular apparatus, in order to optimize left ventricular function over time, but this is not always possible due to the fact that sometimes the structure of the sub-valvular apparatus has abnormalities that require its excision to obtain appropriate size of the left ventricle inflow tract. Sometimes it is necessary to implant the prosthesis in the supra-annular position, because the native ring can not contain even the smallest available prosthesis [8], which can cause greater inconvenience.

In children, the mechanism involved in the genesis of isolated mitral failure is often multifactorial, with predominance of those of rheumatic or degenerative cause, which can affect the leaflets, the annulus or sub-valvular apparatus [13].

Since the seminal studies of Carpentier [14,15], it is known that the approach for correction of mitral failure should be guided by restoration of its functional integrity, often in detriment of restoration of the original anatomy. This concept has revolutionized the treatment of this disease, benefiting large numbers of patients, who had the chance to avoid valve replacement with all the obstacles [16].

The mechanism concerning the closure of the mitral valve has not been fully elucidated. The left atrio-ventricular annulus, considered inert element in the dynamic valve ring, does not serve only as support for the leaflets, since it presents dynamic behavior with active reduction in its circumference during systole [17].

The classical concept on which the anterior portion of the mitral annulus does not dilate has been modified based on well founded anatomical studies, which proved that even the anterior portion of the mitral annulus in its commissural portion, which is inserted in the fibrous skeleton, presents variable level of dilation and, therefore, can present active component in the genesis of mitral failure [18,19]. Although this fact has been specifically proved in adult patients with dilated cardiomyopathy of idiopathic origin, the theoretical basis of its genesis has led us to include the anterior portion of the annulus as an important element in performing procedures of mitral valve repair.

In 1995, Alfieri et al. [9] proposed technique of

correction of mitral failure which consisted of approximating the free edges of the anterior and posterior leaflets at the point of greater failure, creating a situation of bi-orificial mitral valve. This technique gained wide acceptance in the literature because of its applicability, reproducibility, and excellent early and late results in patients with mitral failure of various etiologies, including difficult-to-treat cases [20,21]. The Alfieri's concept was also adapted to be performed through percutaneous approach [22] but these results were not satisfactory for this method, probably due to the performance of concomitant annuloplasty, a factor seen as essential for success of the technique [23].

Our series, although small, confirms the feasibility and simplicity of the proposed repair. The reduction technique of the annulus in its entire length with small strips of bovine pericardium, intermittently, has two purposes, namely: to maintain the geometry of the annulus with its original characteristics and allow for growth - purposes that would not be achieved if the repair was performed using another approach, because the ring entirely non-biodegradable rigid or flexible maintains appropriate annular geometry, but such type of ring does not allow growth. Segmental rings for repair of the posterior portion of the annulus present good surgical outcomes [24,25], but allow growth only of the anterior portion, which can lead to a situation of geometrical misfit over time. Mitral repair through techniques that use bovine pericardium should provide bridging, in order to allow growth.

The proposed technique is based on physiological re-establishment of the valve function. Intermittent repair allows morphological adaptation to the mitral annulus with support of its whole structure. The Alfieri's repair technique provides excellent coaptation of both leaflets, with virtual disappearance of the regurgitant jet. The theoretical concern on appearance of mitral stenosis related to this technique was not confirmed by the literature, and the method is used liberally in several departments, with large number of casuistics accumulated.

## CONCLUSION

Although the case presented is numerically small, the results indicate that the proposed technique is effective in the treatment of mitral regurgitation in pediatric age group in terms of immediate results. The long-term follow-up is needed to assess its durability and the presence of any complications.

## ACKNOWLEDGMENTS

The authors thank Mr. Argemiro Falcetti Jr. for designing the illustrations and Mr. Marcos Roberto Visconti for reviewing the manuscript.

REFERENCES

1. Aharon AS, Laks H, Drinkwater DC, Chugh R, Gates RN, Grant PW et al. Early and late results of mitral valve repair in children. *J Thorac Cardiovasc Surg.* 1994;107(5):1262-70.
2. Enriquez-Sarano M, Schaff HV, Orszulak TA, Tajik AJ, Bailey KR, Frye RL. Valve repair improves the outcome of surgery for mitral regurgitation. A multivariate analysis. *Circulation.* 1995;91(4):1022-8.
3. Yun KL, Miller DC. Mitral valve repair versus replacement. *Cardiol Clin.* 1991;9(2):315-27.
4. Galloway AC, Colvin SB, Baumann FG, Harty S, Spencer FC. Current concepts of mitral valve reconstruction for mitral insufficiency. *Circulation.* 1988;78(5 Pt 1):1087-98.
5. Mendez CA, Buena PFMFV. *Plastia da valva mitral - Série monografias Dante Pazzanese Vol V- 2000.*
6. Dunn JM. Porcine valve durability in children. *Ann Thorac Surg.* 1981;32(4):357-68.
7. Erez E, Kanter KR, Isom E, Williams WH, Tam VK. Mitral valve replacement in children. *J Heart Valve Dis.* 2003;12(1):25-9.
8. Beierlein W, Becker V, Yates R, Tsang V, Elliott M, de Leval M, et al. Long-term follow-up after mitral valve replacement in childhood: poor event-free survival in the young child. *Eur J Cardiothorac Surg.* 2007;31(5):860-5.
9. Fucci C, Sandrelli L, Pardini A, Torracca L, Ferrari M, Alfieri O. Improved results with mitral valve repair using new surgical techniques. *Eur J Cardiothorac Surg.* 1995;9(11):621-6.
10. Bonchek LI, Olinger GN, Siegel R, Tresch DD, Keelan MH Jr. Left ventricular performance after mitral reconstruction for the mitral regurgitation. *J Thorac Cardiovasc Surg.* 1984;88(1):122-7.
11. Roberts WC. Morphologic features of the normal and abnormal mitral valve. *Am J Cardiol.* 1983;51(6):1005-28.
12. Wilcox BR, Anderson RH. *Surgical anatomy of the heart.* New York: Raven Press; 1985.
13. Vlad P. Mitral valve anomalies in children. *Circulation.* 1971;43(4):465-6.
14. Carpentier A, Deloche A, Dauptain J, Soyfer R, Blondeau P, Piwnicka A, et al. A new reconstructive operation for correction of mitral and tricuspid insufficiency. *J Thorac Cardiovasc Surg.* 1971; 61(1):1-13.
15. Carpentier A. Cardiac valve surgery: the "French correction". *J Thorac Cardiovasc Surg.* 1983;86(3):323-37.
16. Chavaud S, Fuzellier JF, Houel R, Berrebi A, Mihaileanu S, Carpentier A. Reconstructive surgery in congenital mitral valve insufficiency (Carpentier's techniques): long-term results. *J Thorac Cardiovasc Surg* 1998;115(1):84-92.
17. Perloff JK, Roberts WC. The mitral apparatus. Functional anatomy of mitral regurgitation. *Circulation.* 1972;46(2):227-39.
18. Hueb AC, Jatene FB, Moreira LF, Pomerantzeff PM, Kallás E, de Oliveira SA. Ventricular remodeling and mitral valve modifications in dilated cardiomyopathy: new insights from anatomic study. *J Thorac Cardiovasc Surg.* 2002;124(6):1216-24.
19. Glasson JR, Komeda MK, Daughters GT, Niczyporuk MA, Bolger AF, Ingels NB, et al. Three-dimensional regional dynamics of the normal mitral annulus during left ventricular ejection. *J Thorac Cardiovasc Surg.* 1996;111(3):574-85.
20. Alfieri O, Maisano F, De Bonis M, Stefano PL, Torracca L, Oppizzi M, et al. The double-orifice technique in mitral valve repair: a simple solution for complex problems. *J Thorac Cardiovasc Surg* 2001;122(4): 674-81.
21. Alfieri O, De Bonis M, Lapenna E, Regesta T, Maisano F, Torracca L, et al. "Edge-to-edge" repair for anterior mitral valve leaflet prolapse. *Semin Thorac Cardiovasc Surg.* 2004;16(2):182-7.
22. Fann JI, St Goar FG, Komtebedde J, Oz MC, Block PC, Foster E, et al. Beating heart catheter-based edge-to-edge mitral valve procedure in a porcine model: efficacy and healing response. *Circulation.* 2004; 110(8): 988-93.
23. Timek TA, Nielsen SL, Lai DT, Liang D, Daughters GT, Ingels NB Jr, et al. Effect of chronotropy and inotropy on stitch tension in the edge-to-edge mitral repair. *Circulation* 2007;116(11 Suppl): I-276-81.
24. Cordeiro CO, Gregori F Jr, Gregori TEF, Murakami AN, Abrão A. Resultados da operação reconstrutora da valva mitral em pacientes com idade inferior a 15 anos. *Rev Bras Cir Cardiovasc.* 2004;19(2):115-9.
25. Volpe MA, Braile DM, Vieira RW, Souza DR. Mitral valve repair with a malleable bovine pericardium ring. *Arq Bras Cardiol.* 2000;75(5):389-96.