

# Extracorporeal membrane oxygenation as a support for TGA/IVS with low cardiac output syndrome and pulmonary hemorrhage

*Oxigenação extracorpórea por membrana como suporte para TGA/IVS com síndrome de baixo débito e hemorragia pulmonar*

Xiaoyang Hong<sup>1,2</sup>, Zhichun Feng<sup>1</sup>, Gengxu Zhou<sup>3</sup>, Xuan Xu<sup>3</sup>

DOI: 10.5935/1678-9741.20130041

RBCCV 44205-1470

## Abstract

A 15-day-old neonate with complete transposition of the great arteries/intact ventricular septum was admitted with life-threatening hypoxemia and heart arrest. After successful resuscitation, heart beat recovered but blood lactate began to arise and maintained above 15 mmol/L 6 hours later. Emergency arterial switch operation was done at 20 hours after resuscitation. Planned extracorporeal membrane oxygenation support was employed postoperatively. The baby experienced severe pulmonary hemorrhage and severe hypoxemia after weaning from cardiopulmonary bypass, which were treated with extracorporeal membrane oxygenation support.

**Descriptors:** Extracorporeal membrane oxygenation. Transposition of great vessels. Low cardiac output. Cardiopulmonary bypass. Extracorporeal circulation.

## Resumo

Um recém-nascido de 15 dias de idade, com transposição completa das grandes artérias/septo ventricular intacto, foi internado com hipoxemia com risco de vida e parada cardíaca. Após a reanimação bem sucedida, o coração voltou a bater, mas o lactato elevou-se e manteve-se acima de 15 mmol/L, 6 horas após. Operação de emergência para correção da transposição das grandes artérias foi realizada 20 horas após a ressuscitação. Suporte de oxigenação por membrana extracorpórea foi empregado no pós-operatório. O bebê apresentou hemorragia pulmonar e hipoxemia graves após desconexão da circulação extracorpórea, que foram tratadas com suporte da oxigenação por membrana extracorpórea.

**Descritores:** Oxigenação por Membrana Extracorpórea. Transposição dos grandes vasos. Baixo débito cardíaco. Ponte cardiopulmonar. Circulação extracorpórea.

## INTRODUCTION

Arterial switch operation (ASO) has long been as a treatment of choice for neonates with transposition of the great arteries/intact ventricular septum (TGA/IVS) achieving

favorable clinical outcome. Unfortunately, in some patients, the treatment of TGA/IVS is usually delayed. Under this condition, the ASO was inapplicable for them, because the left ventricle is unable to accommodate the systemic pressure [1]. Here in, we reported our experience in the treatment

1. Dr./Affiliated Bayi Children Hospital, Beijing Military General Hospital, Beijing 100007, China (Director) – drafting the article and revising it critically for important intellectual content.
2. Dr./Affiliated Bayi Children Hospital, Beijing Military General Hospital, Beijing 100007, China; Affiliated Bayi Children Hospital, Bayi Clinical Medical Institute, Southern Medical University 100007, China – substantial contributions to conception and design, acquisition of data, or analysis and interpretation of data.
3. Dr./Affiliated Bayi Children Hospital, Beijing Military General Hospital, Beijing 100007, China – acquisition of data, or analysis and interpretation of data.

Work carried out at Affiliated Bayi Children Hospital, Beijing Military General Hospital, Beijing, China.

Correspondence address:

Dr. Zhichun Feng, Affiliated Bayi Children Hospital, Beijing Military General Hospital – 100007 – Beijing, China  
E-mail: feng5201314@yahoo.com.cn

Article received on September 28<sup>th</sup>, 2012

Article accepted on January 28<sup>th</sup>, 2013

Abbreviations, acronyms & symbols	
ACT	Activated clotting time
ASO	Arterial switch operation
CPB	Cardiopulmonary bypass
ECMO	Extracorporeal membrane oxygenation
H <sub>2</sub> O	Water
Hct	Hematocrit
LCOS	Low cardiac output syndrome
PCICU	Pediatric cardiac intensive care unit
PCO <sub>2</sub>	Partial pressure of carbon dioxide
PDA	Patent ductus arteriosus
PEEP	Positive end-expiratory pressure
PO <sub>2</sub>	Partial pressure of oxygen
TGA/IVS	Transposition of the great arteries/Intact ventricular septum

CLINICAL CASE

A male neonate with TGA/IVS was admitted into the Pediatric Cardiac Intensive Care Unit (PCICU) of our hospital due to life threatening hypoxemia. He was 15-day old and 3.6 kg in body weight on admission. Patent foramen and patent ductus arteriosus were normal (2 mm and 2.3 mm in diameter, respectively) and the ventricular septum obviously deviated to the left ventricle by bed-side trans-thoracic echocardiography. Blood gas analysis showed the partial pressure of carbon dioxide (PCO<sub>2</sub>) and partial pressure of oxygen (PO<sub>2</sub>) was 37 mmHg and 9 mmHg, respectively, the lactate level was 1.5 mmol/L on admission. The prostaglandin E1 was used immediately after admission. At 5 hours after admission, the PCO<sub>2</sub> and PO<sub>2</sub> were 51 mmHg and 7 mmHg, respectively, and the lactate level was 7.0 mmol/L as shown in arterial blood gas analysis. At 10 hours after admission, heart arrest

of a 15-day-old newborn with TGA/IVS by mechanical circulatory support for severe low cardiac output syndrome (LCOS) and pulmonary hemorrhage after ASO.

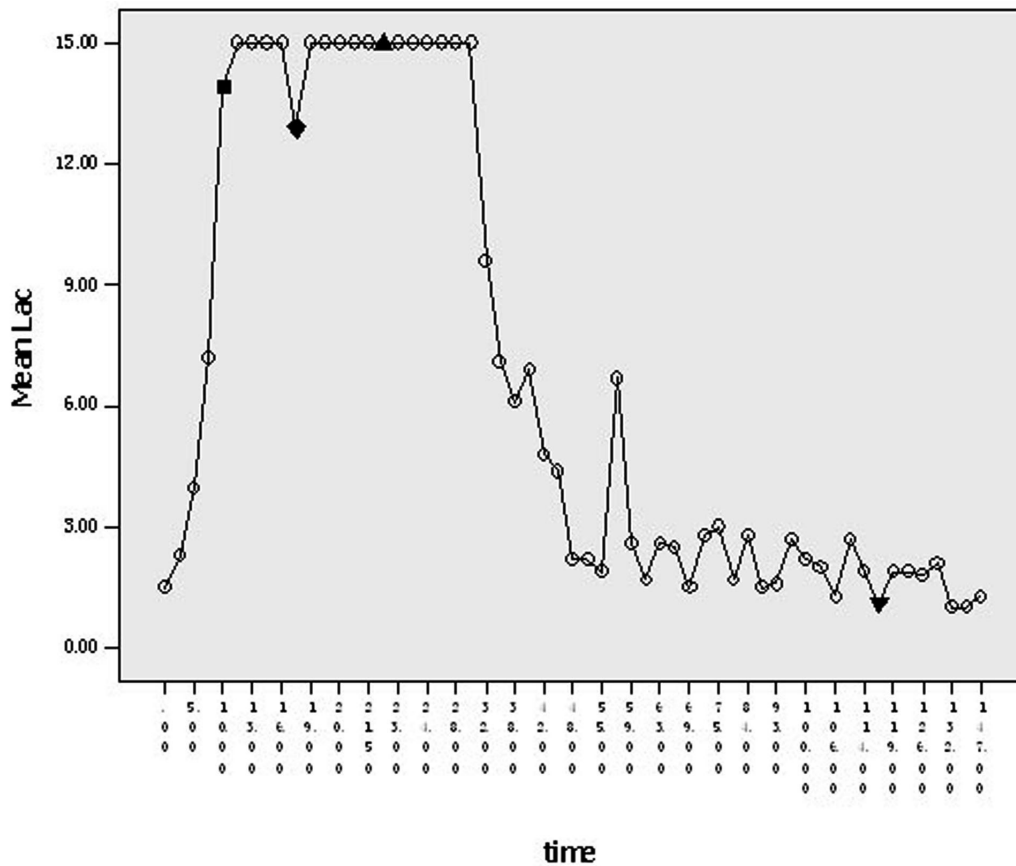


Fig. 1 – Lactate level at 25 hours after surgery  
 ■: time of cardiac arrest occurring; ◆: time of ASO; ▲: time of CPB discontinuation and ECMO initiation;  
 ▼: time of ECMO discontinuation

occurred. After resuscitation, inotropic agents (dopamine and epinephrine) were continuously infused. The lactate level gradually increased to 13.6 mmol/L, and  $PO_2$  was elevated to 9 mmHg.

At 19 hours after admission, this patient received ASO under moderate hypothermia CPB with ultrafiltration. The blood flow in cardiopulmonary bypass (CPB) was adjusted from 150 to 200 ml/kg/min, and the activated clotting time (ACT) was controlled from 450 s to 650 s. The lactate level was maintained at >15 mmol/L for 9 hours and the LV/RV at 0.5 hour before surgery. The time of aorta cross clamp and total CPB was 80 min and 175 min, respectively. After releasing of aortic clamp, the heart beat with sinus rhythm was observed at 130 beats/min. After surgery, the lactate level was still at a high level (>15 mmol/L), and pulmonary hemorrhage occurred. The estimated amount of blood loss from the trachea tube was 100 ml.

Then, the positive end-expiratory pressure (PEEP) was increased from 3 cm  $H_2O$  to 8 cm  $H_2O$  aiming to control the pulmonary hemorrhage. The heart beat or blood pressure was unstable although the volume load and hematocrit (Hct=31%) was acceptable and inotropic agents (dopamine: 10  $\mu$ g/kg/min, epinephrine: 0.15  $\mu$ g/kg.min) were continuously infused during the weaning from CPB. Because of LCOS and pulmonary hemorrhage, extracorporeal membrane oxygenation (ECMO) was prepared for cardiopulmonary support. A 10-Fr aortal cannula and a 16-Fr right atrium cannula were cut off from the CPB system and connected to the ECMO circuit immediately (Medtronic Inc. Minneapolis, MN, USA). The ECMO system was composed of a heparin-

coated circuit, hollow fiber oxygenator and centrifugal pump (Medtronic Inc. Minneapolis, MN, USA). The ECMO blood flow rate was maintained at 0.6 l/min and this neonate was transferred to PCICU with delayed wound closure.

The serum lactate level was still remained at >15 mmol/L for 9 hours after surgery in PCICU, and there after decreased gradually. The lactate level was 2.2 mmol/L at 25 hours after surgery (Figure 1). The patient regained clear consciousness at 16 hours. With favorable urine output, acceptable arterial blood pressure (70-80/30-40 mmHg) and favorable findings in chest X-ray (Figure 2A and 2B), the patient weaned off the ECMO after 96 hours support, and the wound was closed simultaneously. During the ECMO support, heparin was used to maintain ACT at 160-250 s. Platelets were infused daily to keep the platelet level at >50000/L. This patient was extubated at 6 days after operation and discharged eventually.

## DISCUSSION

Now, ASO is the treatment of choice for TGA/IVS in neonates. However, in China, the treatment of TGA/IVS is usually delayed and the pulmonary arterial pressure is significantly declined in these neonates. Thus, the left ventricle is unable to accommodate the systemic pressure after ASO. Under this situation, rather than ASO, two-stage ASO is performed [1]. However, many authors thought that the degradation of left ventricle was reversible, and were more inclined to perform primary ASO followed by ECMO support [2-4].

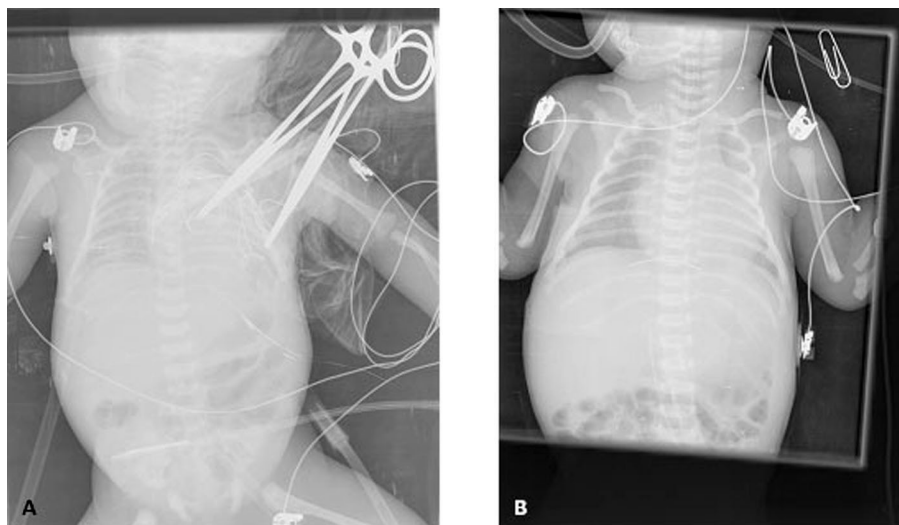


Fig. 2 – A: Anteroposterior chest X-ray (POD1 after ECMO initiation). B: Anteroposterior chest X-ray (POD6 after ECMO discontinuation)

In the present case, the patient gradually deteriorated after admission, and the life-threatening hypoxemia resulted in cardiac arrest and high level lactate. We speculated that the patent ductus arteriosus (PDA) was almost closed. Echocardiography after admission showed the ventricular septal obviously deviated to the left ventricle. Considering this, rapid two-stage ASO was infeasible for this patient. Thus, ECMO was prepared before ASO. Although the use of EMCO-based left ventricle support for TGA/IVS after ASO has been reported previously [5], to our knowledge EMCO used in such critical TGA/IVS patient who had high level lactate (>15 mmol/L) before ASO and pulmonary hemorrhage after ASO has not been reported in previous studies.

In this patient, the ventricular septum deviated toward the left, and the LV/RV was 0.5, suggesting that the left ventricle may not endure the systemic pressure if the ASO is performed under CPB. On the other hand, life-threatening hypoxemia and high lactate level might make his cardiopulmonary function worse after operation, and rapid two-stage ASO was not feasible for life-saving. Because ECMO is able to provide both cardiac and pulmonary support immediately, ECMO was performed after the ASO was finished, and pulmonary hemorrhage was found. ECMO was performed as soon as CPB discontinued. Massive transfusion had to be done, and this resulted in hypothermia, which may recover after treatment with the heat-exchanger of the ECMO system. The time of initiation of ECMO is crucial for life saving.

In this case, ECMO was performed as soon as possible in the operation room. Recent reports [6,7] revealed that ECMO in operation room could avoid the prolonged hypoperfusion and multiorgan failure. In the support with ECMO, the heparin-coated circuit could omit the use of heparin, and platelets were transfused daily to keep the platelet at > 50000/L, which may improve the coagulation. After 92 hours ECMO support, this patient's hemodynamics was stable enough and weaned from ECMO. Then, the wound was closed in the PCICU.

## REFERENCES

1. Lacour-Gayet F, Piot D, Zoghbi J, Serraf A, Gruber P, Macé L, et al. Surgical management and indication of left ventricular retraining in arterial switch for transposition of the great arteries with intact ventricular septum. *Eur J Cardiothorac Surg.* 2001;20(4):824-9.
2. Sarris GE, Chatzis AC, Giannopoulos NM, Kirvassilis G, Berggren H, Hazekamp M, et al. The arterial switch operation in Europe for transposition of the great arteries: a multi-institutional study from the European Congenital Heart Surgeons Association. *J Thorac Cardiovasc Surg.* 2006;132(3):633-9.
3. Bisoi AK, Sharma P, Chauhan S, Reddy SM, Das S, Saxena A, et al. Primary arterial switch operation in children presenting late with d-transposition of the great arteries and intact ventricular septum. When is it too late for a primary arterial switch operation? *Eur J Cardiothorac Surg.* 2010;38(6):707-13.
4. Kang N, de Leval MR, Elliott M, Tsang V, Kocyildirim E, Sehic I, et al. Extending the boundaries of the primary arterial switch operation in patients with transposition of the great arteries and intact ventricular septum. *Circulation.* 2004;110(11 Suppl 1):II123-7.
5. Shah SA, Shankar V, Churchwell KB, Taylor MB, Scott BP, Bartilson R, et al. Clinical outcomes of 84 children with congenital heart disease managed with extracorporeal membrane oxygenation after cardiac surgery. *ASAIO J.* 2005;51(5):504-7.
6. Ko WJ, Lin CY, Chen RJ, Wang SS, Lin FY, Chen YS. Extracorporeal membrane oxygenation support for adult postcardiotomy cardiogenic shock. *Ann Thorac Surg.* 2002;73(2):538-45.
7. Chaturvedi RR, Macrae D, Brown KL, Schindler M, Smith EC, Davis KB, et al. Cardiac ECMO for biventricular hearts after paediatric open heart surgery. *Heart.* 2004;90(5):545-51.