

Transanal total mesorectal excision combined with laparoscopic dissection: perioperative results and assessment of the mesorectal quality.

Excisão total de mesorreto transanal combinada à dissecação laparoscópica: resultados perioperatórios e avaliação da qualidade do mesorreto.

MARLLUS BRAGA SOARES, TCBC-RJ¹; MARCOS BETTINI PITOMBO, TCBC-RJ²; JOÃO DE AGUIAR PUPO NETO, ECBC -RJ³; ISIS ALVES GALVÃO⁴

A B S T R A C T

Objective: to assess the perioperative and postoperative results of transanal total mesorectal excision, as well as the quality of the specimens obtained by this technique. **Methods:** we conducted a prospective, descriptive study in consecutive patients with rectal adenocarcinoma located up to 10cm from the anal verge, without distant metastasis, subjected or not to neoadjuvant chemoradiotherapy. We evaluated the presence of technical difficulties, conversion to open abdominal route, surgical time and intra and postoperative complications. Through histopathological analysis, we assessed the quality of the mesorectum, involvement of the proximal and distal margins and positivity of the circumferential, classifying quality of the mesorectum as complete, partially complete or incomplete resection. **Results:** between December 2016 and May 2019, 41 patients underwent transanal total mesorectal excision, of which 75% were classified as clinical stage III, 13% clinical stage II and 12% clinical stage I. The average distance between the anal verge and the lower border of the tumor was 6.2cm. Forty percent of the tumors were in the anterior rectal wall and 17% were circumferential. The average operative time was 189 minutes. The average hospital stay was 4.6 days. There were no in-hospital deaths. Eighty-two percent of the specimens were classified as complete resection. **Conclusion:** transanal total mesorectal excision demonstrates adequate specimen quality and surgical margins, being associated with lower rates of perioperative complications, acceptable surgical time and short hospitalization.

Keywords: Transanal Endoscopic Surgery. Transanal Endoscopic Microsurgery. Rectal Neoplasms. Colorectal Surgery.

INTRODUCTION

Rectal adenocarcinoma is classified as one up to 15cm from the anal verge, accounting for about 30% of all colorectal cancers. Surgical rectum anterior resection with total mesorectal excision (TME), associated or not with neoadjuvant chemoradiotherapy, is the curative approach in most cases. TME is considered the gold standard surgical treatment for rectal adenocarcinoma, and the most important factor for disease recurrence is the compromise of the circumferential margin^{1,2}.

The importance of surgical radicality in the treatment of rectal cancer has been demonstrated countless times since the initial publications by Heald *et al.*^{3,4}. Since then, a significant reduction in local disease recurrence has been observed.

Many studies suggest that the quality of the mesorectum obtained through TME may be a determinant prognostic factor³⁻⁶. Over the years, the TME has migrated from the traditional laparotomic technique to the laparoscopic one, adding to the procedure the benefits of this access route⁷. Laparoscopy provides better anatomical visualization of the pelvic cavity, facilitating the mobilization of the rectum. However, this access route has laparotomic conversion rates between 10% and 30%⁷⁻⁹. Such conversions are mainly associated with the presence of large tumors and narrow pelvis male patients, which hampers distal tumor dissection.

The surgical technique of transanal total mesorectal excision (TaTME) was developed in order to improve the quality of the TME procedure for patients with middle and lower rectal cancer.

1 - São José do Avaí Hospital, Proctology Service, Itaperuna, RJ, Brazil.

2 - Rio de Janeiro State University, School of Medical Sciences, Department of General Surgery, Rio de Janeiro, RJ, Brazil.

3 - Federal University of Rio de Janeiro, School of Medicine, Department of Surgery, Rio de Janeiro, RJ, Brazil.

4 - São José do Avaí Hospital, Nutrition Service, Itaperuna, Rio de Janeiro, Brazil.

In TaTME, the distal pelvic portion of the mesorectum is approached through the anus with the aid of an endoscopic platform for natural orifice transluminal endoscopic surgery (NOTES). This technique was initially described as a procedure performed by transanal direct vision¹⁰, and later using a transanal endoscopic microsurgery device (TEO, STORZ®)¹¹. Over the years, after the initial publications, numerous other cases have been reported around the world¹²⁻¹⁷.

In theory, TaTME facilitates mesorectal dissection, reducing the need for definitive colostomy and conversion to laparotomy. In addition, TaTME aims to increase indices of complete mesorectal resection, better determination of the distal margin, and lower rates of circumferential margin involvement compared with abdominal TME¹⁶. This "bottom to top" procedure potentially generates a new surgical approach option, especially in cases with very low tumors, obese patients and narrow pelvises¹⁶.

This study aimed to evaluate the perioperative and postoperative (in-hospital) results related to TaTME, as well as the quality of the specimens obtained by TaTME by histologically analyzing the quality of the mesorectum, involvement of the proximal and distal margins, and positivity of the circumferential margin.

METHODS

We conducted a prospective, descriptive study of consecutive patients, with rectal adenocarcinoma located up to 10cm from the anal verge, without distant metastasis, submitted or not to neoadjuvant chemoradiotherapy. We excluded from the study patients with distant metastases with indication for endoanal tumor resection that had direct invasion of other organs or of the levator ani muscle.

The patients included in the study, who had agreed to participate in the study, did so by signing a specific informed consent term. This work was performed at São José do Avaí Hospital, Itaperuna, RJ, Brazil, and approved by the Institutional Ethics Committee with the following reference CAAE 89904818.5.0000.8044.

Regarding the TaTME surgery, we evaluated type of surgery, presence of technical difficulties, conversion rate to open abdominal route, surgical time, and intra and postoperative complications. The specimens obtained by TaTME were analyzed by a research pathologist. The quality of the mesorectum was classified as complete, partially complete or incomplete resection according to the protocol described by Quirke *et al.*¹⁷.

The distal margin was determined by the distance between the lower edge of the tumor and the rectal resection edge, and was considered compromised when less than 5mm. The circumferential margin was classified as positive when less than 1mm.

In the patients selected for this study, we evaluated specific aspects such as demographic data, body mass index (BMI), pre- and post-neoadjuvant clinical staging, postoperative clinical complications, and mortality.

We also used pelvic magnetic resonance imaging descriptive data, both pre-neoadjuvant and post-neoadjuvant therapy. These were the distance in centimeters between the anal verge and the lower tumor edge, the caudal-cranial size in centimeters, the location in the rectal wall, the depth of the rectus invasion (T stage), lymph node involvement (N stage), presence of mesorectal fascia invasion in millimeters (circumferential margin), and degree of tumor regression by the Dworak scale¹⁸.

All selected patients underwent preoperative radiological staging, which included computed tomography of the chest and upper abdomen associated with pelvic nuclear magnetic resonance.

The patients undergoing neoadjuvant therapy underwent chemotherapy with 380mg/m² 5-Fluouracil and 20mg/m² Leucovorin for five continuous days (D1 to D5) during the first and fifth weeks of radiotherapy. Radiotherapy consisted of 28 split sessions over five weeks, totaling 5040cGy.

TaTME took place after 12 weeks of completion of the last radiotherapy session, and all patients underwent new radiographic staging by pelvic nuclear magnetic resonance at the end of that period.

TaTME surgeries were performed by a single team, and the transanal time was started only after the end of the abdominal time. For the abdominal time the patient was placed in Lloyd-Davis position, pneumoperitoneum instilled with transumbilical Veres needle, with standardized technique of insertion and placement of laparoscopic access ports, as well as dissection and ligation of the inferior mesenteric vessels.

Rectal dissection in the abdominal time was performed down to certain anatomical landmark, which differs between genders. In women, the dissection progressed until the visualization of the anterior recto-vaginal septum; in men, until visualization of seminal vesicles. After rectal dissection, a loop ileostomy was performed in a previously determined site on the abdominal wall and the patient was placed in a forced lithotomy position, aiming at wide exposure of the perineal region.

Prior to the coupling of the transanal natural orifice surgery device, we used a transanal fenestrated anoscope to determine the appropriate distance between the distal rectal dissection and the distal tumor margin. Then we applied an airtight purse-string suture to the rectum with 0 Prolene® thread in the proper height so as to leave at least 1cm between the suture and the tumor distal edges (determining the distal margin).

For the transanal time, we used a disposable flexible platform (Gelpoint®/Applied Medical) fixed at the anal margin with a single suture of 2-0 Nylon® thread on both sides. We used the same 30°/10mm scope used for the abdominal dissection for the transanal time. The intermittent CO₂ insufflator continuously kept the pressure at 20mmHg. We started the transanal dissection by the posterior rectal plane, progressing to the right lateral plane, moving to the left lateral plane and ending at the anterior plane, until reaching the previously performed abdominal dissection plane.

We performed the colorectal or coloanal anastomosis manually, with 3-0 Vycril® suture under direct vision, leaving the pelvic drain externalized by the left ischioanal fossa.

RESULTS

Between December 2016 and May 2019, 41 patients underwent TaTME, of whom 55% were men. The mean age was 62 years (33-74), the average BMI was 26.2kg/m² (19-35) and 75% of the patients were classified as clinical stage III, 13% clinical stage II, and 12% clinical stage I; 25% of patients did not receive neoadjuvant chemoradiotherapy (Table 1).

The average distance between the anal border and the tumor lower edge was 6.2cm (3-8.8). The average tumor size assessed by pre-neoadjuvant therapy MRI was 5cm (2-12); 16% of patients had mesorectal fascia involvement; 40% of the tumors were in the anterior rectal wall, 25% in the posterior rectal wall, 18% in the lateral rectal walls, and 17% were circumferential (Table 2).

The average interval between the end of neoadjuvant chemoradiotherapy and surgery was 13.4 weeks of (12-20). In the group of patients undergoing chemoradiotherapy, all showed a reduction in clinical staging at MRI reevaluation

after 12 weeks, and in 26% there was complete clinical response to neoadjuvant chemoradiotherapy (Dworak grade 4).

The average operative time was 189 minutes (135-322). Four patients underwent TaTME associated with inter-sphincteric resection of the internal anal sphincter. There were two intraoperative complications, one lesion of the urethra during the transanal dissection and one lesion of the posterior vaginal wall. Only one patient required conversion from the transanal to the laparoscopic approach due to the difficulty of progression during the rectum caudo-cranial dissection (Table 3).

Table 1. *Patient-related data and clinical staging.*

Patients' evaluation	Data
Average age in years (range)	62 (33-74)
Average body mass index in kg/m ² (range)	26.2 (19-35)
Initial clinical staging	
Stage I	12%
Stage II	13%
Stage III	75%

Table 2. *Tumor-related pelvic nuclear magnetic resonance data.*

Tumor evaluation	Data
Average tumor height in centimeters (range)	6.2 (3-8.8)
Inferior rectum	26%
Middle rectum	74%
Average tumor diameter in centimeters (range)	5 (2-12)
Involvement of mesorectal fascia	16%

Table 3. *Surgery and intra and postoperative complications.*

Evaluation of surgery and complications	Data
Average surgery time in minutes	189 (135-322)
Intraoperative complications	6%
Conversion to laparoscopy	3%
Conversion to laparotomy	0%
Average hospital time in days (range)	4.6 (2-12)
Postoperative complications	20%
Reoperations	3%
Deaths	0%

The average hospital stay was 4.6 days (2-12). There was one complication in the immediate postoperative period due to bleeding from the inferior mesenteric artery, requiring surgical reintervention. Four patients had adynamic ileus. Two patients had nosocomial pneumonia, both of whom stayed twelve days for complete antibiotic therapy. There were no deaths (Table 3).

Specimens were classified as complete resection in 82% of cases and as partially complete resection in 18%. There was no incomplete resection in the evaluated mesorectums. The average distal margin was 2.4cm (0.6-6.8). All specimens had negative circumferential margin. The average number of lymph nodes in the specimens was 16 (12-26) (Table 4).

DISCUSSION

The great evolution of surgery for rectal cancer was undoubtedly due to the concept of total mesorectal excision with negative circumferential margin, instituted by Richard Heald, in the 1980s³. The advancement of minimally invasive approaches have added benefits to the technique, making the laparoscopic rectal anterior resection with total mesorectal excision the surgery of choice for the vast majority of surgeons.

However, in 2015, two large prospective randomized studies failed to demonstrate the superiority of the laparoscopic pathway compared with the laparotomic one. Since then, many questions have been raised about the real oncological safety of the laparoscopic total mesorectal excision¹⁹⁻²¹.

In obese, male, narrow-pelvis patients, the technical difficulty of the total mesorectal excision by laparoscopy was more evident. In this context, there was a resurgence of the use of the transanal route as a way to approach such cases, in an attempt to promote greater oncological safety.

In 1988, Gerard Marks described the technique of transanal resection of the rectum without direct view of the structures, the Transanal Abdominal Transanal Proctectomy (TATA)²². In 2010, Patricia Sylla describes a similar technique in porcine models with use of a video platform, enabling direct view of the structures, later replicated for patients with rectal cancer¹¹.

The decision to study this technique lies in the possibility to offer new safe treatment options for rectal cancer patients, as well as in the controversy around this subject in the academic world. The option to perform the procedure with only one team sought to reduce surgical costs, with fewer participants and only one complete laparoscopy surgery set.

Table 4. Histopathological evaluation of the specimen.

Specimen evaluation	Data
Complete resection	82%
Partially complete resection	18%
Incomplete resection	0%
Average distal margin in centimeters (range)	2.4 (0.6-6.8)
Negative circumferential margin	100%
Average number of lymph nodes (range)	16 (12-26)

We opted for the use of a disposable flexible platform (Gelpoint®/Applied Medical) because we believe that it offers a better field of work for transanal surgery and allows the use of the same material used in the laparoscopic surgery time, including the 10mm, 30° scope.

Our strategy was to initiate by the laparoscopic time and then to perform the transanal time because we were in a single team, which facilitated the following logistics: 1) abdominal dissection time; 2) loop ileostomy; 3) patient repositioning; 4) patient replacement of surgical drapes; 5) transanal dissection time; 6) transanal rectal specimen extraction; 7) colorectal or coloanal anastomosis.

Even working with a single team, the mean operative time of the study was 189 minutes, which was adequate when compared with data available in the literature for other cases of total transanal mesorectal excision cases, in which the average operative times reached 304 minutes^{15,23,24}. Those procedures in which there was greater difficulty and required longer operative time corresponded to the first 12 patients (Figure 1). In these first cases, there were also major intraoperative complications, such as urethral injury (patient 2), posterior vagina wall lesion (patient 5) and conversion of the transanal to laparoscopic approach due to difficulty in the caudal-cranial dissection (patient 8).

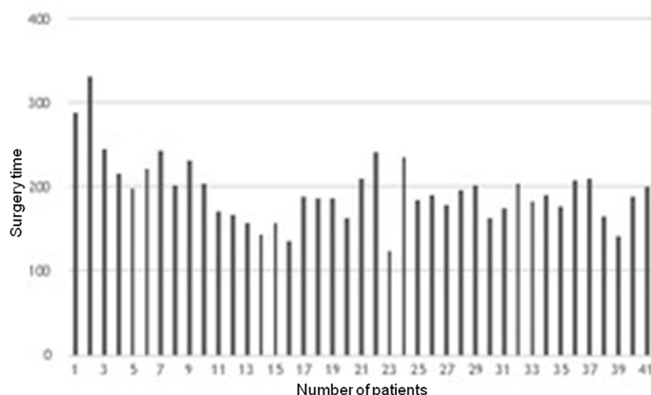


Figure 1. Relationship between number of patients and operative time.

Surgical time was also increased in patients with body mass index above 29kg/m² (Figure 2). We found a Pearson's correlation coefficient (r) of 0.4839 (95%CI: 0.21-0.69; $t=3.4535$; $GI: 39$; $p=0.0013$) and considered moderately positive. In these patients, the more caudally the pelvic dissection progressed, the more "comfortable" the transanal dissection was. When specifically evaluating this subgroup (13 patients), we noted that there was no impact on the quality of the mesorectum in the postoperative histopathological evaluation. Of these, 85% were classified as complete resection and 15% as partially complete.

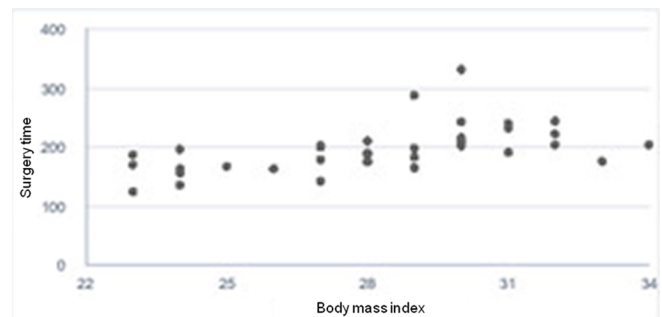


Figure 2. Relationship between body mass index and operative time.

As TaTME is still a subject of studies and the vast majority of patients received neoadjuvant chemoradiotherapy, we decided to perform loop ileostomy in all patients. In 26% of patients there was a complete clinical response indicated by post-neoadjuvant MRI, a fact confirmed by pathological study of the specimen in 78% of the sample.

Evaluation of the rectal specimen obtained by TaTME surgery showed that approximately 82% of the cases (33 patients) were classified as complete resection, with negative circumferential margin. These findings are the most prominent in this study, since they are directly related to locoregional recurrence and disease-free survival.

When comparing the quality of the mesorectum obtained by TaTME in the present study with the findings available in the literature related to the use of the exclusive laparoscopic approach, we observed similar rates of complete mesorectal resection. Also noteworthy was the lack of circumferential margin compromise in the present study, a finding not shown by other prospective randomized studies on total laparoscopic mesorectal excision, among which we cite the CLASSIC Trial, with 16% circumferential margin compromise, the COLOR II trial and ACOSOG Trial, both with 10%, the ALaCaRT Trial, with 7%, and the Korean Trial, with 2.9%^{20,21,25-27}.

This study demonstrated that total transanal mesorectal excision combined with laparoscopic dissection showed good results regarding mesorectal quality analysis, with adequate surgical margins, being associated with low rates of perioperative complications, acceptable surgical time and short hospitalization time. This surgery is presented as part of the surgical armamentarium in the treatment of lower and middle rectum cancer, but still requires new prospective, randomized, multicenter studies, with long-term oncologic and functional results.

R E S U M O

Objetivo: avaliar os resultados perioperatórios e pós-operatórios relacionados à excisão total do mesorreto transanal, bem como, qualidade dos espécimes obtidos pela excisão total do mesorreto transanal através da análise histopatológica da qualidade do mesorreto, acometimento das margens proximal e distal e positividade da margem circumferencial. **Métodos:** estudo prospectivo, descritivo, em pacientes consecutivos portadores de adenocarcinoma de reto localizados até 10cm da borda anal, sem metástase à distância, submetidos ou não à quimioterapia e radioterapia neoadjuvantes. Foram avaliados a presença de dificuldades técnicas, índice de conversão para via abdominal, tempo cirúrgico e intercorrências intra e pós-operatórias. A qualidade do mesorreto foi classificada em ressecção completa, parcialmente completa ou incompleta. **Resultados:** entre dezembro de 2016 e maio de 2019, 41 pacientes foram submetidos à excisão total do mesorreto transanal, dos quais 75% foram classificados como estágio clínico III, 13% estágio clínico II e 12% estágio clínico I. A média de distância entre borda anal e borda inferior do tumor foi de 6,2cm. Quarenta por cento dos tumores encontravam-se na parede retal anterior e 17% foram classificados como circumferenciais. A média de tempo operatório foi de 189 minutos. A média de internação hospitalar foi de 4,6 dias. Não houve óbitos intra-hospitalares. Oitenta e dois por cento dos espécimes foram classificados como ressecção completa. **Conclusão:** a excisão total do mesorreto transanal demonstra adequada qualidade do mesorreto e adequadas margens cirúrgicas, estando associada a baixos índices de complicações perioperatórias, tempo cirúrgico aceitável e curto tempo de hospitalização.

Descritores: Cirurgia Endoscópica Transanal. Microcirurgia Endoscópica Transanal. Neoplasias Retais. Cirurgia Colorretal.

REFERENCES

1. Bosch SL, Nagtegaal ID. The importance of the pathologist's role in assessment of the quality of the mesorectum. *Curr Colorectal Cancer Rep.* 2012;8(2):90-8.
2. Nagtegaal ID, Marijnen CA, Kranenbarg EK, van de Velde CJ, van Krieken JH; Pathology Review Committee; Cooperative Clinical Investigators. Circumferential margin involvement is still an important predictor of local recurrence in rectal carcinoma: not one millimeter but two millimeters is the limit. *Am J Surg Pathol.* 2002;26(3):350-7.
3. Heald RJ, Husband EM, Ryall RD. The mesorectum in rectal cancer surgery-the clue to pelvic recurrence? *Br J Surg.* 1982;69(10):613-6.
4. Heald RJ. The 'Holy Plane' of rectal surgery. *J R Soc Med.* 1988;81(9):503-8.
5. Heald RJ, Moran BJ, Ryall RD, Sexton R, MacFarlane JK. Rectal cancer: the Basingstoke experience of total mesorectal excision, 1978-1997. *Arch Surg.* 1998;133(8):894-9.
6. Mercury Study Group. Diagnostic accuracy of preoperative magnetic imaging in predicting curative resection of rectal cancer: prospective observational study. *BMJ.* 2006;333(7572):779.

7. van der Pas MH, Haglind E, Cuesta MA, Fürst A, Lacy AM, Hop WC, Bonjer HJ; COLOrectal cancer Laparoscopic or Open Resection II (COLOR II) Study Group. Laparoscopic versus open surgery for rectal cancer (COLOR II): short-term outcomes of a randomised, phase 3 trial. *Lancet Oncol.* 2013;14(3):210-8.
8. Penninckx F, Kartheuser A, Van de Stadt J, Pattyn P, Mansvelt B, Bertrand C, Van Eycken E, Jegou D, Fieuws S; PROCARE. Outcome following laparoscopic and open total mesorectal excision for rectal cancer. *Br J Surg.* 2013;100(10):1368-75.
9. Jayne DG, Thorpe HC, Copeland J, Quirke P, Brown JM, Guillou PJ. Five-year follow-up of the medical research council CLASICC trial of laparoscopically assisted versus open surgery for colorectal cancer. *Br J Surg.* 2010;97(11):1638-45.
10. Funahashi K, Koike J, Teramoto T, Saito N, Shiokawa H, Kurihara A, et al. Transanal rectal dissection: a procedure to assist achievement of laparoscopic total mesorectal excision for bulky tumor in the narrow pelvis. *Am J Surg.* 2009;197(4):e46-50.
11. Sylla P, Rattner DW, Delgado S, Lacy AM. NOTES transanal rectal cancer resection using transanal endoscopic microsurgery and laparoscopic assistance. *Surg Endosc.* 2010;24(5):1205-10.
12. Fernández-Hevia M, Delgado S, Castells A, Tasende M, Momblan D, Díaz del Gobbo G, et al. Transanal total mesorectal excision in rectal cancer: short-term outcomes in comparison with laparoscopic surgery. *Ann Surg.* 2015; 261(2):221-7.
13. Atallah S, Martin-Perez B, Albert M, deBeche-Adams T, Nassif G, Hunter L, et al. Transanal minimally invasive surgery for total mesorectal excision (TAMIS-TME): results and experience with the first 20 patients undergoing curative-intent rectal cancer surgery at a single institution. *Tech Coloproctol.* 2014;18(5):473-80.
14. Velthuis S, Nieuwenhuis DH, Ruijter TE, Cuesta MA, Bonjer HJ, Sietes C. Transanal versus traditional laparoscopic total mesorectal excision for rectal carcinoma. *Surg Endosc.* 2014;28(12):3494-9.
15. de Lacy AM, Rattner DW, Adelsdorfer C, Tasende MM, Fernández M, Delgado S, et al. Transanal natural orifice transluminal endoscopic surgery (NOTES) rectal resection: "down-to-up" total mesorectal excision (TME)--short-term outcomes in the first 20 cases. *Surg Endosc.* 2013;27(9):3165-72.
16. Velthuis S, van den Boezem PB, van der Peet DL, Cuesta MA, Sietes C. Feasibility study of transanal total mesorectal excision. *Br J Surg.* 2013;100(6):828-31.
17. Quirke P, Durdey P, Dixon MF, Williams NS. Local recurrence of rectal adenocarcinoma due to inadequate surgical resection: histopathological study of lateral tumour spread and surgical excision. *Lancet.* 1986;2(8514):996-9.
18. Dworak O, Keilholz L, Hoffmann A. Pathological features of rectal cancer after preoperative radiochemotherapy. *Int J Colorectal Dis.* 1997;12(1):19-23.
19. Emmertsen KJ, Laurberg S. Low anterior resection syndrome score: development and validation of a symptom-based scoring system for bowel dysfunction after low anterior resection for rectal cancer. *Ann Surg.* 2012;255(5):922-8.
20. Stevenson AR, Solomon MJ, Lumley JW, Hewett P, Clouston AD, GebSKI VJ, Davies L, Wilson K, Hague W, Simes J; ALaCaRT Investigators. Effect of laparoscopic-assisted resection vs open resection on pathological outcomes in rectal cancer: the ALaCaRT randomized clinical trial. *JAMA.* 2015;314(13):1356-63.
21. Fleshman J, Branda M, Sargent DJ, Boller AM, George V, Abbas M, et al. Effect of laparoscopic-assisted resection vs open resection of stage ii or iii rectal cancer on pathologic outcomes: the ACOSOG Z6051 randomized clinical trial. *JAMA.* 2015;314(13):1346-55.
22. Marks G, Mohiuddin M, Goldstein SD. Sphincter preservation for cancer of the distal rectum using high dose preoperative radiation. *Int J Radiat Oncol Biol Phys.* 1988;15(5):1065-8.
23. Rouanet P, Mourregot A, Azar CC, Carrere S, Gutowski M, Quenet F, et al. Transanal endoscopic proctectomy: an innovative procedure for difficult resection of rectal tumors in men with narrow pelvis. *Dis Colon Rectum.* 2013;56(4):408-15.

24. Sylla P, Bordeianou LG, Berger D, Han KS, Lauwers GY, Sahani DV, et al. A pilot study of natural orifice transanal endoscopic total mesorectal excision with laparoscopic assistance for rectal cancer. *Surg Endosc.* 2013;27(9):3396-405.
25. Guillou PJ, Quirke P, Thorpe H, Walker J, Jayne DG, Smith AM, Heath RM, Brown JM; MRC CLASICC trial group. Short-term endpoints of conventional versus laparoscopic-assisted surgery in patients with colorectal cancer (MRC CLASICC trial): multicentre, randomised controlled trial. *Lancet.* 2005;365(9472):1718-26.
26. Bonjer HJ, Deijen CL, Abis GA, Cuesta MA, van der Pas MH, de Lange-de Klerk ES, Lacy AM, Bemelman WA, Andersson J, Angenete E, Rosenberg J, Fuerst A, Haglind E; COLOR II Study Group. A randomized trial of laparoscopic versus open surgery for rectal cancer. *N Engl J Med.* 2015;372(14):1324-32.
27. Kang SB, Park JW, Jeong SY, Nam BH, Choi HS, Kim DW, et al. Open versus laparoscopic surgery for mid or low rectal cancer after neoadjuvant chemoradiotherapy (COREAN trial): short-term outcomes of an open-label randomised controlled trial. *Lancet Oncol.* 2010;11(7):637-45.

Received in: 06/20/2019

Accepted for publication: 07/15/2019

Conflict of interest: none.

Source of funding: Researchers' own financial support for the purchase of the necessary devices to perform transanal surgeries (Gelpoint).

Mailing address:

Marllus Braga Soares

E-mail: marllussoares@hotmail.com

