

# The Manzi projection: an imaging method used in dentistry for differential diagnosis of atheroma

*Projeção de Manzi: um método odontológico para diagnóstico diferencial de atheroma*

Guilherme Augusto Alves de OLIVEIRA<sup>1</sup>

Beethoven Estevão COSTA<sup>2</sup>

Flávio Ricardo MANZI<sup>1</sup>

## ABSTRACT

*Atherosclerosis is a pathology of great importance worldwide, because of its direct relationship with cerebrovascular events, resulting in high morbidity and mortality rates. The possibility of atheromas being identified by means of panoramic radiography is consolidated in literature; however, limitations have been reported. Thus, the aim of the present clinical case was to demonstrate the possibility of using Manzi's Projection, which is a technique that enables visualization of the carotid artery trajectory without superimpositions of other anatomic structures, capable of promoting differential diagnosis of calcified atheromas in the carotid artery during dental exams.*

**Indexing terms:** Atherosclerosis. Carotid arteries. Panoramic radiography.

## RESUMO

A aterosclerose representa uma patologia de grande importância mundial devido à relação direta com as doenças cerebrovasculares, resultando em altos índices de morbimortalidade. A possibilidade de identificação destas placas ateromatosas através da radiografia panorâmica está consolidada na literatura, sendo também relatadas suas limitações. Com intuito de possibilitar um diagnóstico diferencial de ateromas na prática odontológica, a Projeção de Manzi consiste numa técnica ântero-posterior que possibilita uma visualização sem sobreposições do trajeto carotídeo. O presente estudo tem por objetivo relatar um caso clínico demonstrando as possibilidades diagnósticas dos exames odontológicos na detecção de ateromas calcificados na artéria carótida.

**Termos de indexação:** Aterosclerose. Artérias carótidas. Radiografia panorâmica.

## INTRODUCTION

Atherosclerosis is an important public health issue worldwide and is characterized by lipid and inflammatory cell deposition on the arterial walls, forming plaques denominated atheromas<sup>1-2</sup>.

The development of atheromas occurs predominantly at the level of the carotid artery bifurcation, as it presents a large turbulent flow that generates low intensity, but constant stress on the arterial wall<sup>3</sup>.

Clinically, Doppler Ultrasonography is the method of choice for detecting these atheromatous plaques, because it has an accuracy of approximately 90% in comparison with Intra-arterial Angiography - the gold standard. Since Angiography is an invasive method with high morbidity and mortality rates estimated at 2%, its indication has been restricted<sup>4</sup>.

Atheromas may be diagnosed by means of routine dental radiographic exams (panoramic radiography) as this calcified plaque is characterized as a radiopaque mass that may be circular, heterogeneous, unilateral or bilateral, in a lateral position to the intervertebral space C3-C4<sup>5</sup>.

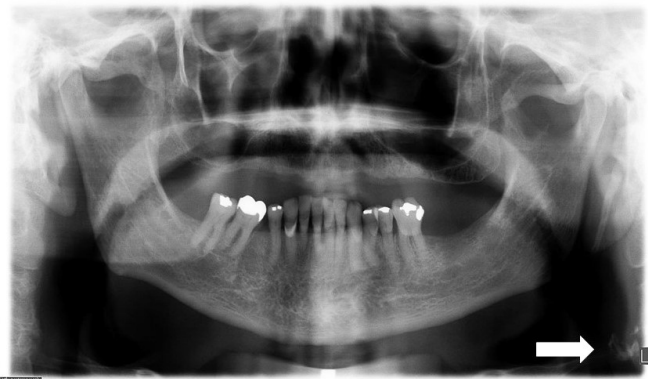Although these atheromatous plaques may be identified in panoramic radiographs, further exams are required to establish a differential diagnosis, due to the presence of structures with similar characteristics, such as triticeous cartilage calcification, sialoliths, phlebolites, the hyoid bone, and calcified lymphatic ganglia, among others in the cervical region. The Manzi projection consists of an exam that may promote this differential diagnosis by enabling visualization of the carotid trajectory without the superimposition of other calcified structures<sup>3,5-6</sup>.

## CASE REPORT

The patient, a 74-year old man, presented with systemic risk factors for the formation of atheromas, sedentarism and chronic periodontitis. For dental care, the patient was requested to have a panoramic radiograph taken with the Kodak Ceph 9000 3D apparatus, (Carestream Health, Inc.), in which the presence of a radiopaque mass on the left side was verified, located laterally to the intervertebral space C3-C4, suggestive of a calcified atheroma (Figure 1).

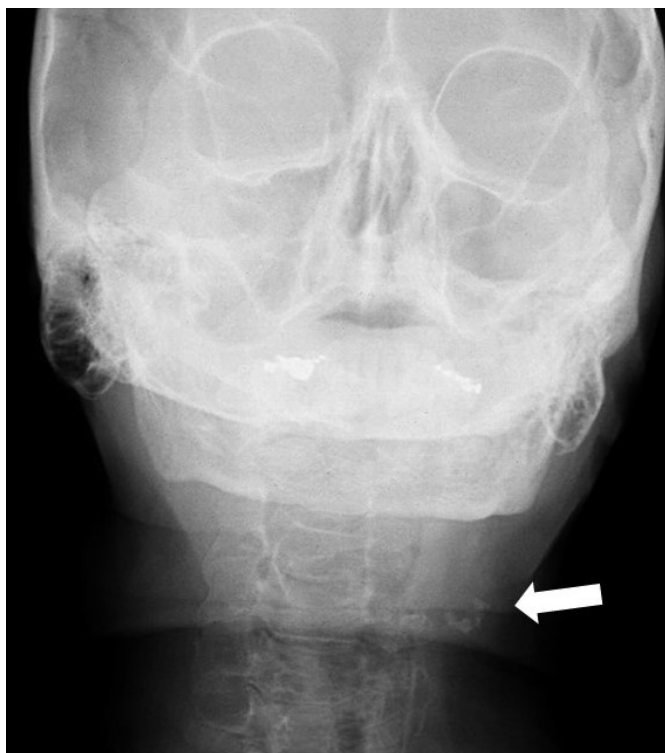
<sup>1</sup> Pontifícia Universidade Católica de Minas Gerais, Programa de Pós-Graduação em Odontologia. Av. D. José Gaspar, 500, Prédio 46, sala 101, Coração Eucarístico, 30535-901, Belo Horizonte, MG, Brasil. Correspondência para / Correspondence to: GAA OLIVEIRA. E-mail: <guilherme\_augusto.o@hotmail.com>.

<sup>2</sup> Fundação Universidade de Itaúna. Itaúna, MG, Brasil.



**Figure 1.** Well delimited radiopaque image on the left side close to the intervertebral space C3 and C4 (arrow).

For differential diagnosis between atheromas and other types of calcifications with some radiographic similarity, the option was taken to perform the Manzi Projection, an anterior-posterior projection performed in the cephalometric unit with the Kodak Ceph 9000 3D apparatus (Carestream Health, Inc.), in which the patient is positioned with the Frankfurt plane slightly inclined (between 15-30°) towards the vertical position. On performing the exam, the presence of a radiopaque mass was verified on the left side, site of the carotid trajectory, compatible with calcified atheroma in the carotid artery (Figure 2).



**Figure 2.** The Manzi Projection showing radiopaque images close to the intervertebral space C3 and C4 (arrow).

After confirmation of calcifications in the carotid by means of the Manzi Projection, the patient was referred for cardiological treatment, and was requested to have Doppler Ultrasonography performed to verify the degree of arterial stenosis. As a result, the presence of a large calcified plaque was found in the left carotid artery, promoting 50-69% stenosis.

## DISCUSSION

The early diagnosis of atheromatous plaques may represent an enormous social gain, since atherosclerosis is directly associated with cerebrovascular diseases, this would act in the prevention of acute events<sup>7-8</sup>.

Historically, the diagnosis of calcified plaques in the carotid artery was obtained only by means of medical exams, however, with the studies of Fridlander and Lande, the possibility of using dental exams for this purpose was verified. Panoramic radiography was the method of choice, because it demonstrated not only the oral and maxillofacial complex, but the cervical region as well. Since then, use of this exam for this purpose has been studied, and the advantages and limitations related to the diagnosis of calcified plaques in the carotid artery have been reported<sup>3,9-11</sup>.

Panoramic radiography, a widely used diagnostic method in dental practice, increases the possibility of diagnosing atheromas in the portion of the population not in the habit of seeking periodic medical consultations. Moreover, because it concerns a generally asymptomatic disease, occasional findings of calcified plaques may represent a method of triage of patients at risk for the development of cerebrovascular events<sup>3,5,12</sup>.

The fact that calcified structures present similar radiographic characteristics is a limitation of panoramic radiography in the diagnosis of atheromas, however, when associated with the Manzi Projection, it was possible to establish a differential diagnosis. This was because the carotid trajectory, in the region of greatest prevalence - the bifurcation - was shown without the superimposition of other structures. Vertical inclination of the patient (between 15-30°) broadened visualization of the cervical spine, because it promoted less mandibular superimposition<sup>6</sup>.

## CONCLUSION

The present report demonstrated that the Manzi Projection was a promising dental method for establishing the differential diagnosis of calcified atheromas in the bifurcation of the carotid artery.

## REFERENCES

- Alves N, Deana NF, Garay I. Detection of common carotid artery calcifications on panoramic radiographs: prevalence and reliability. *Int J Clin Exp Med*. 2014;7(8):1931-1939.
- Mozaffarian D, Benjamin EJ, Go AS, Arnett DK, Blaha MJ, Cushman M, et al. Heart disease and stroke statistics - 2015 update: a report from the American Heart Association. *Circulation*. 2015;131(4):e29-322. doi: 10.1161/CIR.0000000000000152
- Friedlander AH, Lande A. Panoramic radiographic identification of carotid arterial plaques. *Oral Surg Oral Med Oral Pathol*. 1981;52(1):102-4. doi: 10.1016/0030-4220(81)90181-X
- Grant EG, Benson CB, Moneta GL, Alexandrov AV, Baker DJ, Bluth EI, et al. Carotid artery stenosis: gray scale and Doppler US diagnosis-Society of radiologists in ultrasound consensus conference. *Radiology*. 2003;229(2):340-6. doi: 10.1148/radiol.2292030516
- Friedlander AH, Friedlander IK. Panoramic dental radiography: an aid in detecting individuals prone to stroke. *Br Dent J*. 1996;181(1):23-6.
- Manzi FR, Bóscolo FN, De Almeida SM, Heiter-Neto F. Panoramic radiography as an auxiliary in detecting patients at risk for cerebrovascular accident (CVA): a case report. *J Oral Sci*. 2003;45:177-80. doi: 10.2334/josnusd.45.177
- O'Donnell MJ, Xavier D, Liu L, Zhang H, Chin SL, Rao-Melacini P. Risk factors for ischaemic and intracerebral haemorrhagic stroke in 22 countries (the INTERSTROKE study): a case-control study. *Lancet*. 2010;376:112-23. doi: 10.1016/s0140-6736(10)60834-3
- World Health Organization. The top 10 causes of death. Fact sheet number 310, 2014 [cited 2016 Nov 10]. Available from: <<http://www.who.int/mediacentre/factsheets/fs310/en/>>.
- Shakhinovich I, Kiser D, Satiani B. Importance of validation of accuracy of duplex ultrasonography in identifying moderate and severe carotid artery stenosis. *Vasc Endovasc Surg*. 2010;44(6):483-488. doi: 10.1177/1538574410374128
- Roldán R, Oñate RE, López F, Cabrerizo MC, Martínez F. Panoramic radiograph as a method for detecting calcified atheroma plaques: review of literature. *Oral Med Oral Patol Oral Surg Oral Radiol Endod*. 2006;11(3):261-6. doi: 10/10489368 [pii]
- Romano CM, Krejci L, Medeiros FM, Graciosa-Filho RG, Martins MF, Guedes VN, et al. Diagnostic agreement between panoramic radiographs and color doppler images of carotid atheroma. *J Appl Oral Sci*. 2009;17(1):45-48. doi: 10.1590/S1678-77572009000100009
- Norris JW, Zhu CZ, Bornstein NM, Chambers BR. Vascular risks of asymptomatic carotid stenosis. *Stroke*. 1991;22(12):1485-90. doi: 10.1161/01.STR.22.12.1485

## Collaborators

GAA OLIVEIRA performed the clinical care of the patient and prepared the manuscript. BE COSTA carried out the literary review and preparation of the manuscript. FR MANZI performed the radiological examinations, critical analysis and orthographic corrections of the manuscript.

Received on: 9/2/2017

Final version resubmitted on: 17/3/2017

Approved on: 21/4/2017